

# Unit 2 Pictures

BIOL 212 Online Lab PowerPoint

**Hint: Slides with colored backgrounds help to divide content into different days.**

Use the following pictures to help you identify terms from the lab term handout.

Another good resource is the Olexik website: [http://faculty.montgomerycollege.edu/wolexik/204\\_histology\\_page.htm](http://faculty.montgomerycollege.edu/wolexik/204_histology_page.htm)

# Gross Bone Structure

Figure 6.4a The structure of a long bone (humerus of arm).

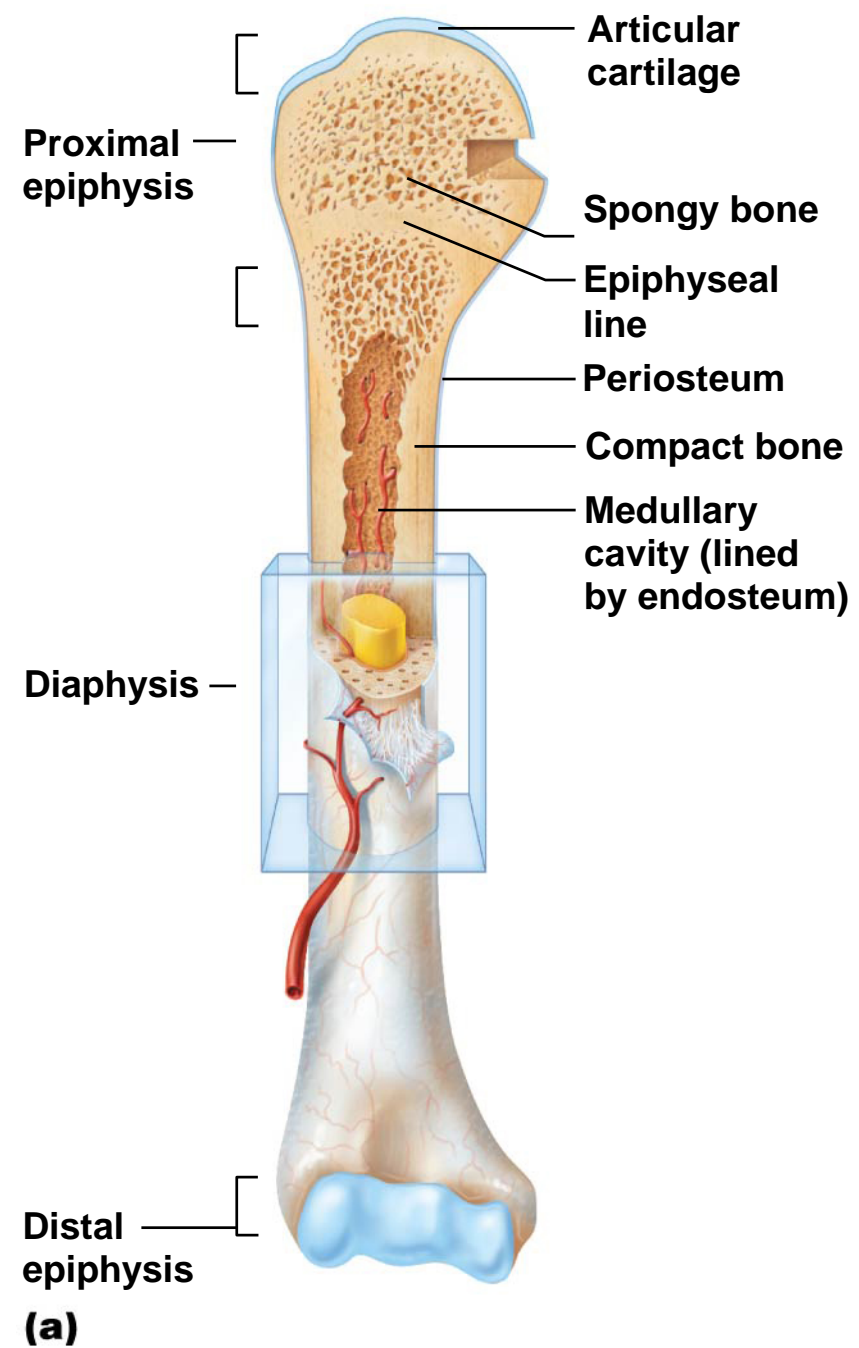


Figure 6.4b The structure of a long bone (humerus of arm).

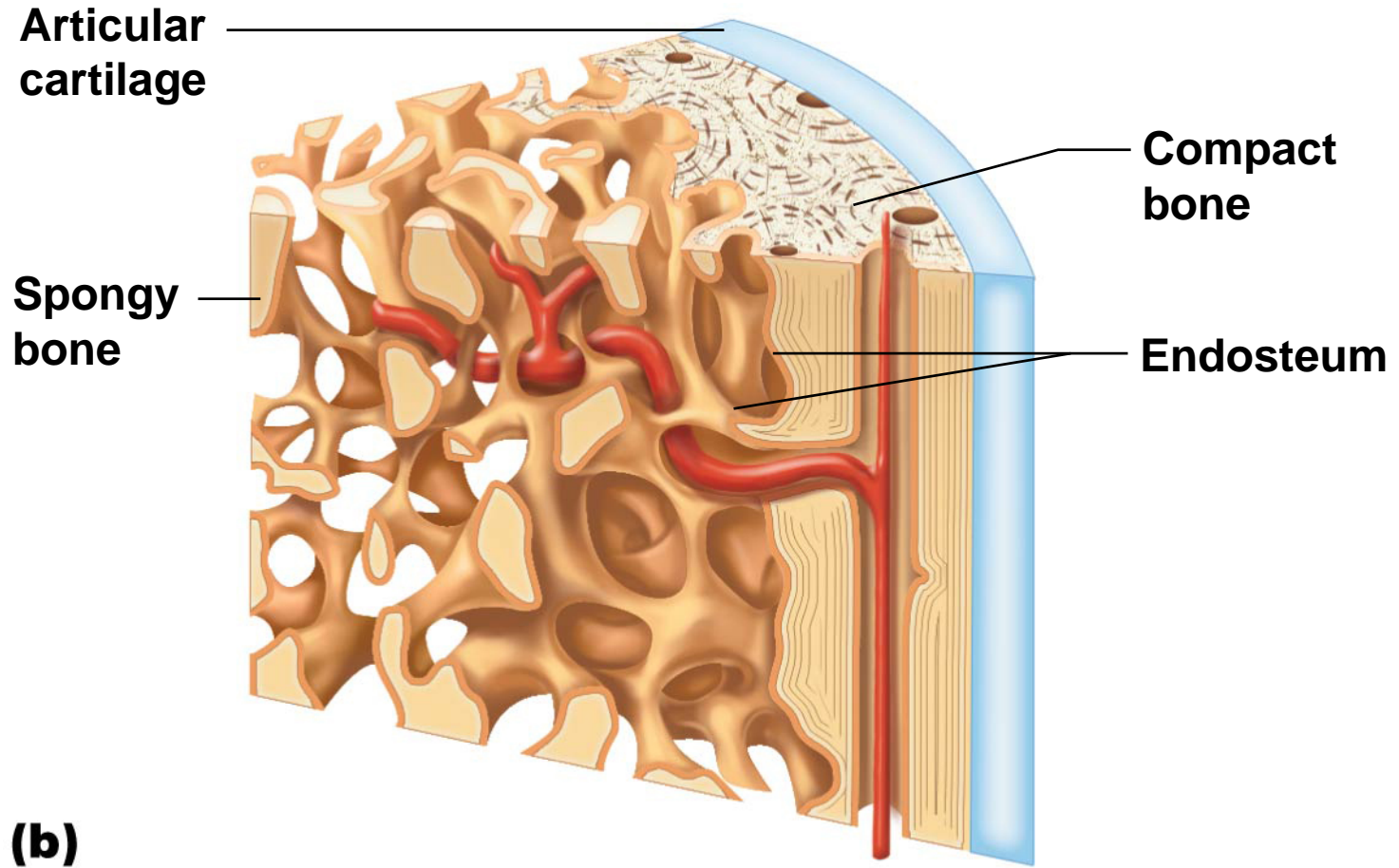
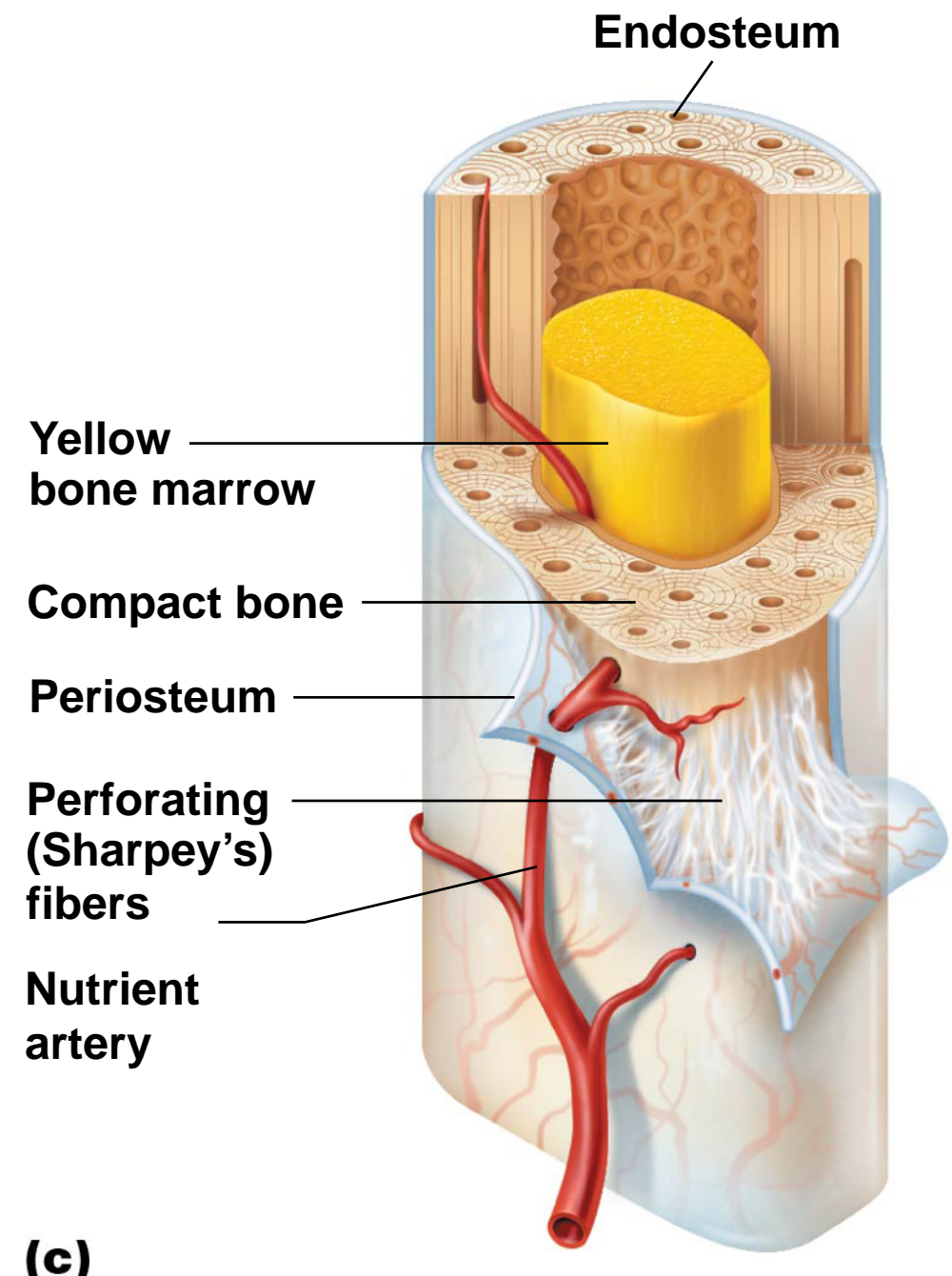


Figure 6.4c The structure of a long bone (humerus of arm).



**(c)**

Figure 6.6 A single osteon.

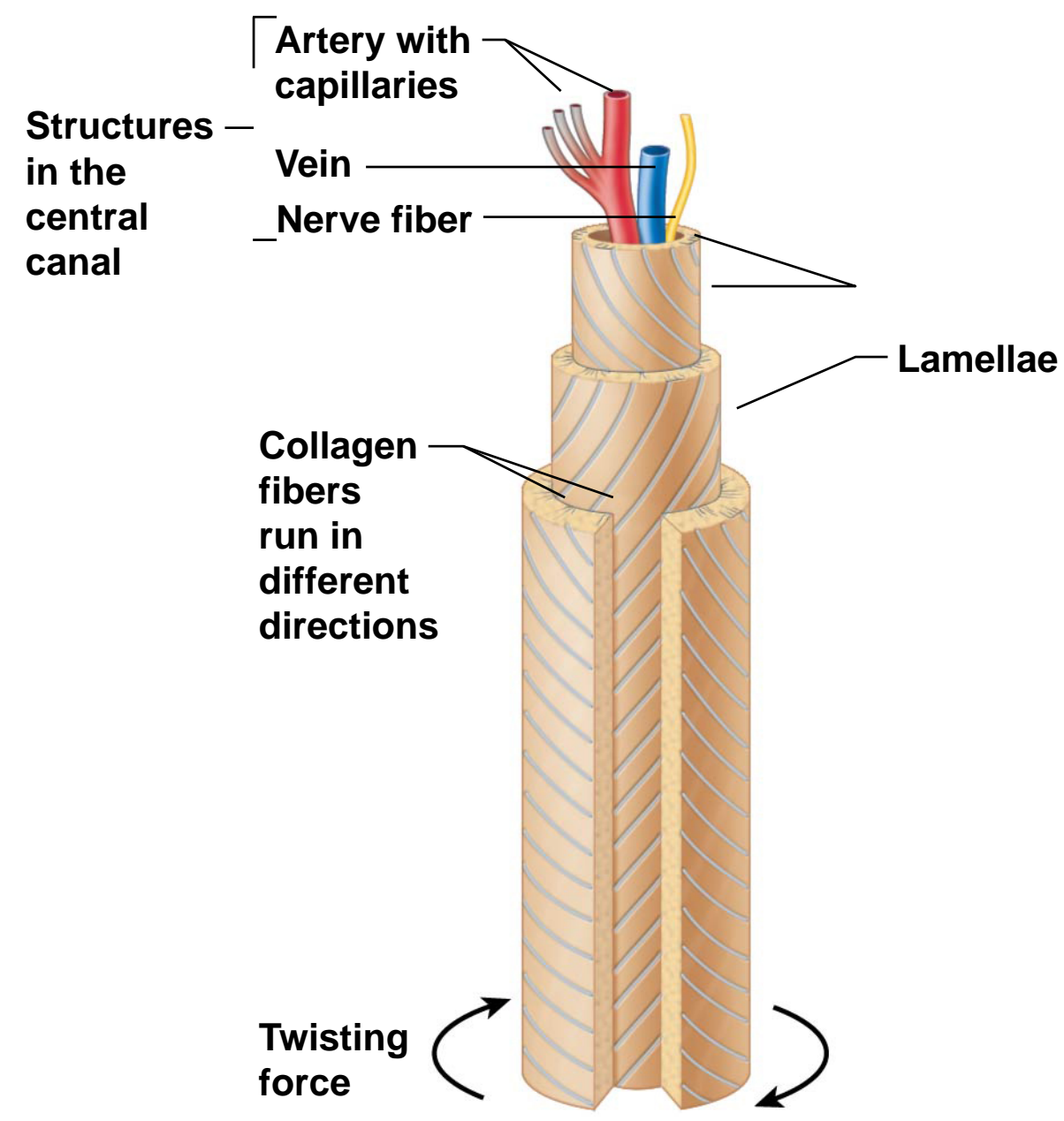
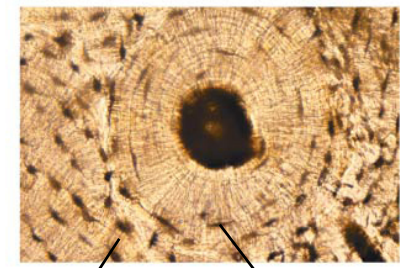
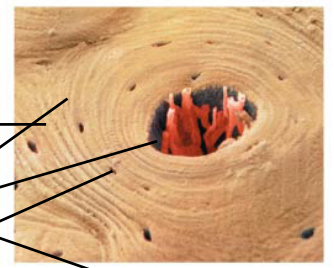
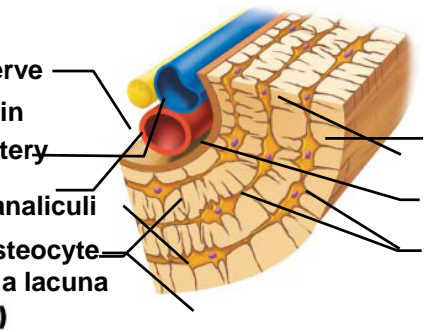
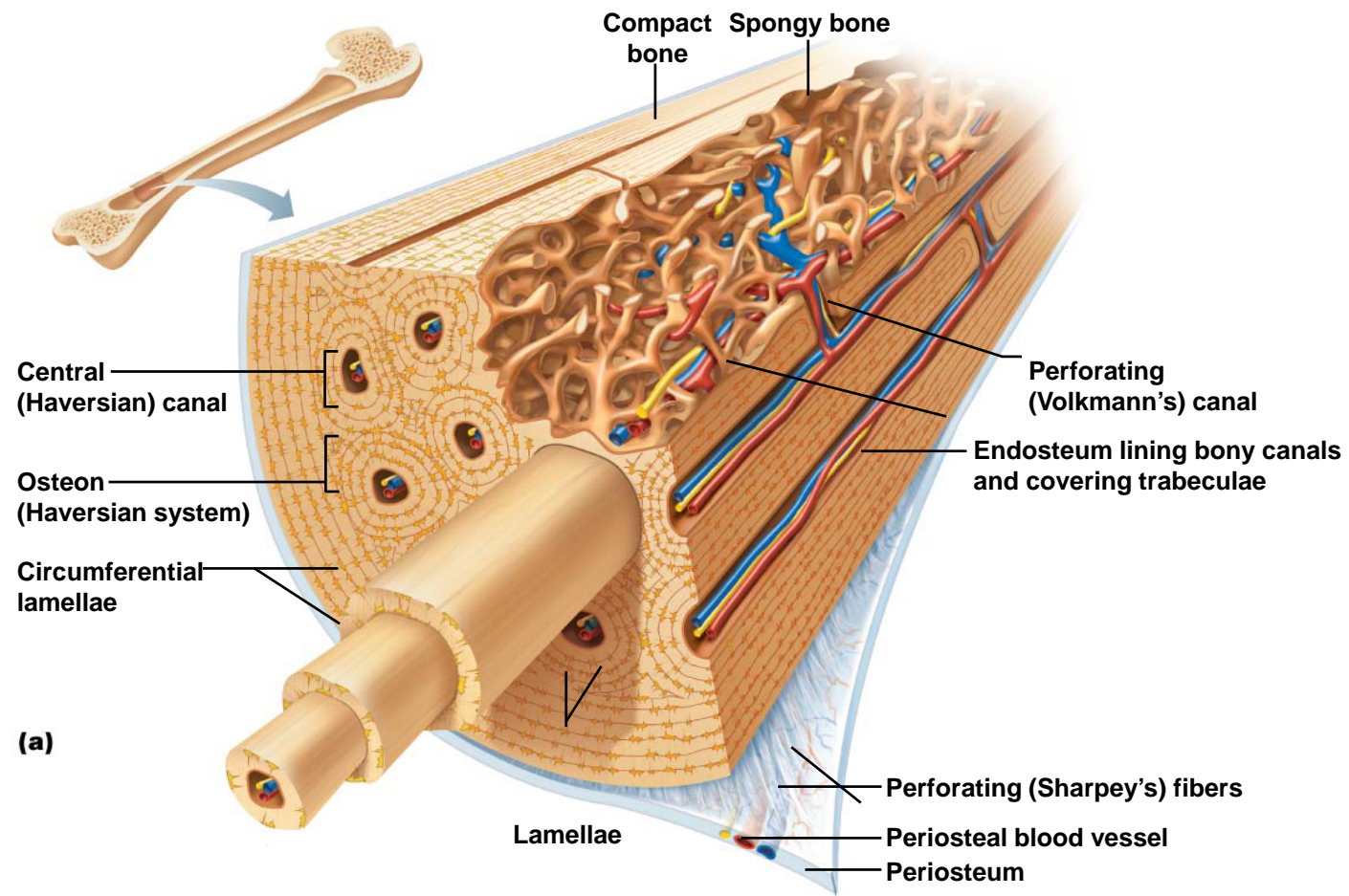


Figure 6.7 Microscopic anatomy of compact bone.



Interstitial lamella Lacuna (with osteocyte)



Figure 6.7a Microscopic anatomy of compact bone.

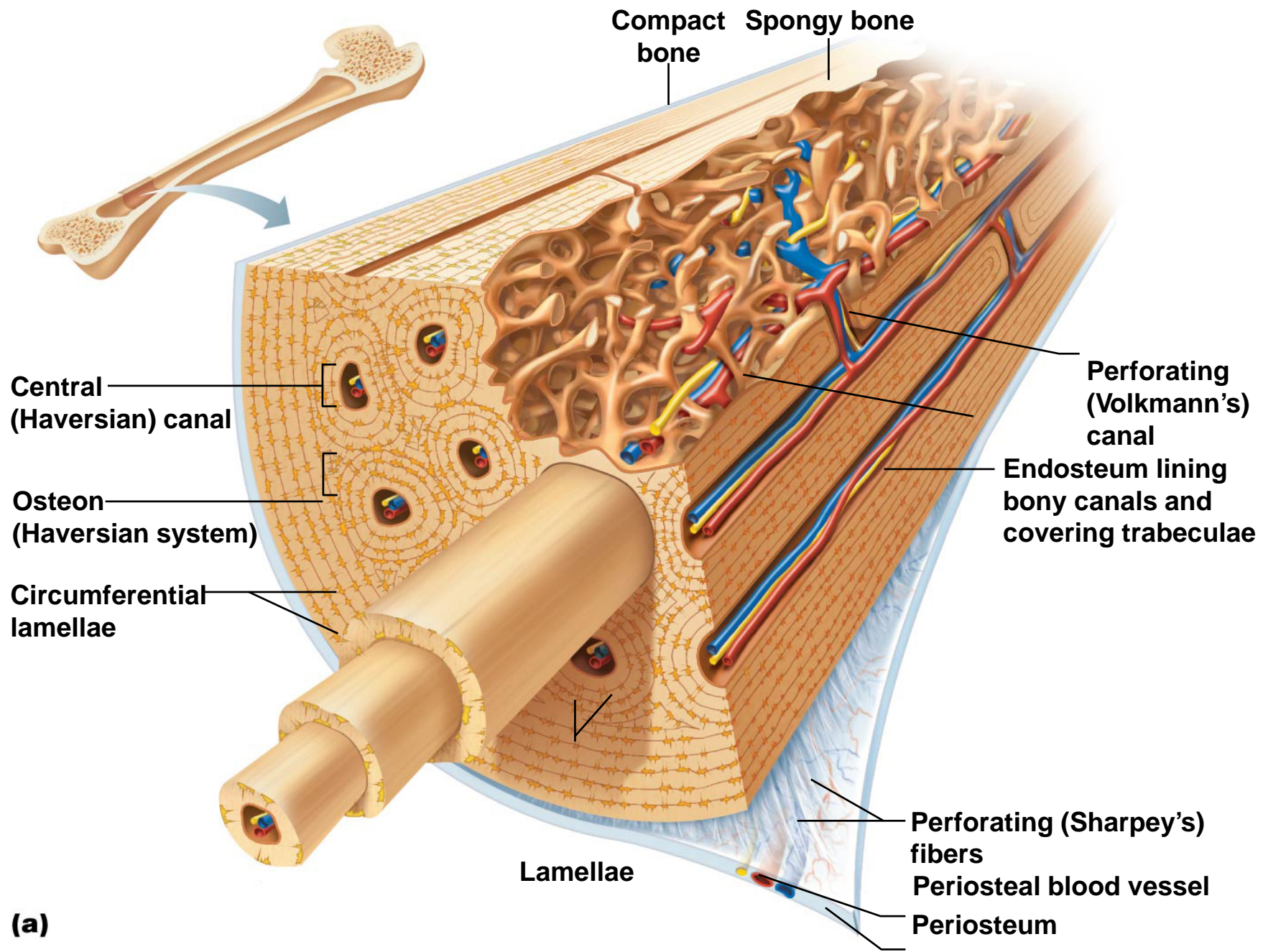
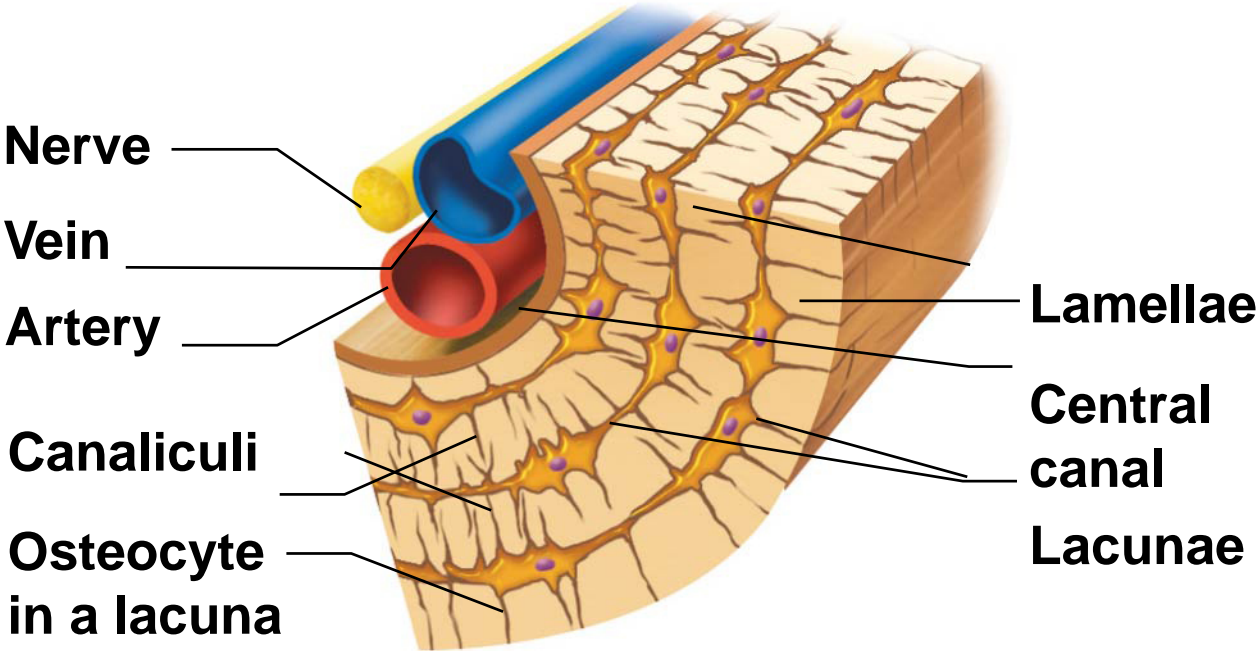
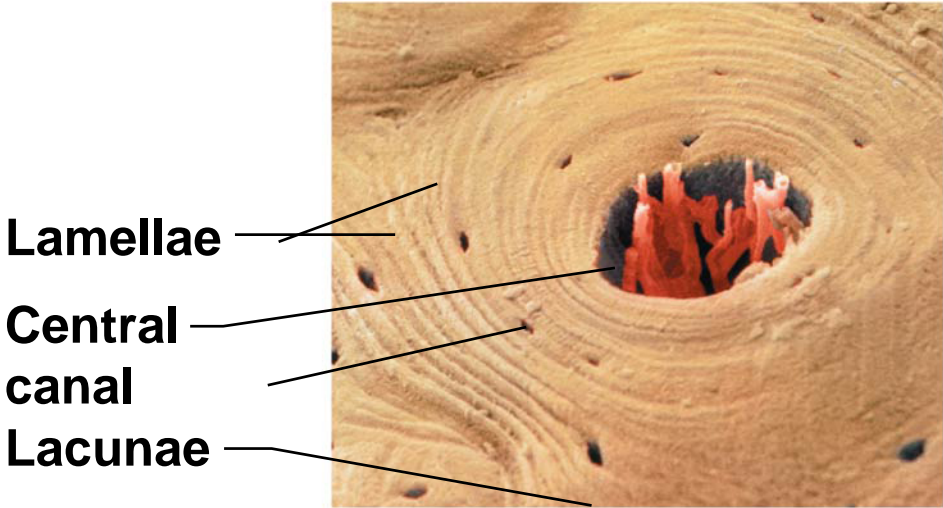


Figure 6.7b Microscopic anatomy of compact bone.

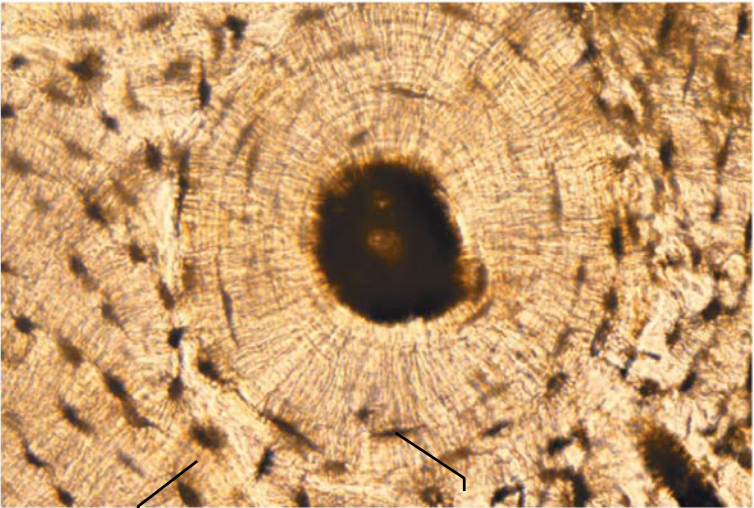


**(b)**

Figure 6.7c Microscopic anatomy of compact bone.



(c)



Interstitial lamella  
Lacuna (with osteocyte)

**Table 6.1 Bone Markings**

NAME OF BONE MARKING	DESCRIPTION	ILLUSTRATIONS
----------------------	-------------	---------------

**Projections That Are Sites of Muscle and Ligament Attachment**

Tuberosity (too'bĕ-ros'ĭ-te)	Large rounded projection; may be roughened
Crest	Narrow ridge of bone; usually prominent
Trochanter (tro-kan'ter)	Very large, blunt, irregularly shaped process (the only examples are on the femur)
Line	Narrow ridge of bone; less prominent than a crest
Tubercle (too'ber-kl)	Small rounded projection or process
Epicondyle (ep'i-kon'dĭl)	Raised area on or above a condyle
Spine	Sharp, slender, often pointed projection
Process	Any bony prominence

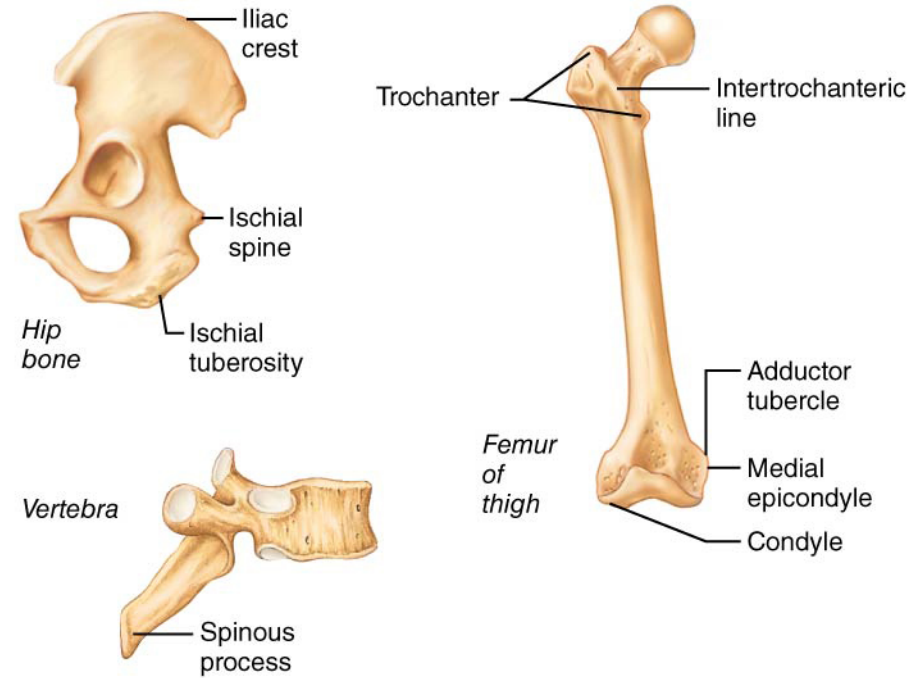


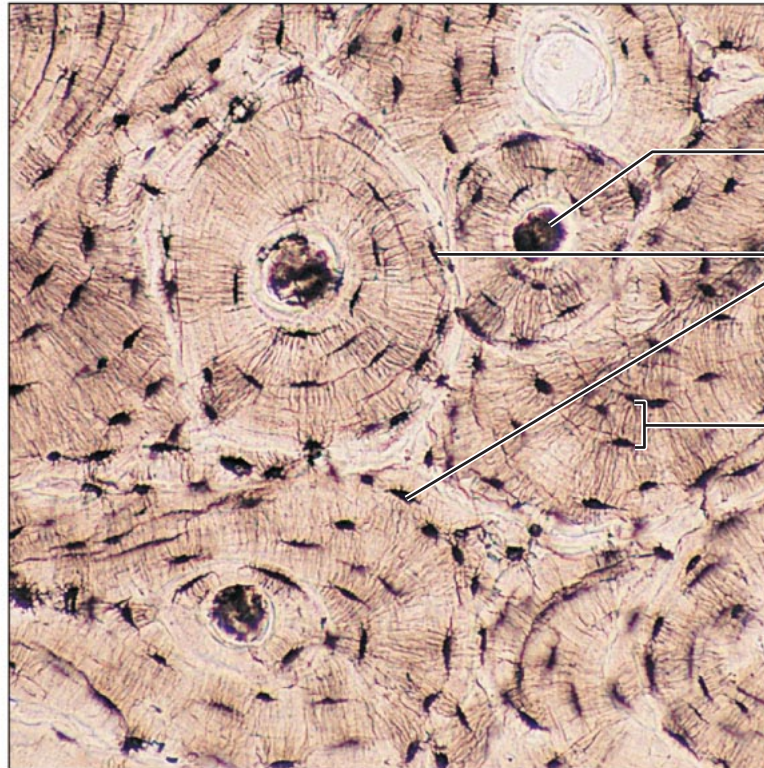
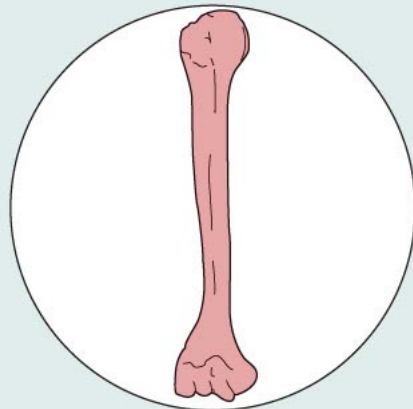
Table 6.1 Bone Markings ( <i>continued</i> )		
NAME OF BONE MARKING	DESCRIPTION	ILLUSTRATIONS
<b>Projections That Help to Form Joints</b>		
Head	Bony expansion carried on a narrow neck	<p>The illustrations show a rib with labels for its 'Head' and 'Facets', and a mandible with labels for its 'Condyle' and 'Ramus'.</p>
Facet	Smooth, nearly flat articular surface	
Condyle (kon'dīl)	Rounded articular projection	
Ramus (ra'mus)	Armlike bar of bone	
<b>Depressions and Openings</b>		
<b>For Passage of Blood Vessels and Nerves</b>		
Groove	Furrow	<p>The illustrations show a lateral view of the skull with labels for 'Meatus', 'Fossa', 'Notch', 'Groove', and 'Sinus', and a frontal view of the skull with labels for 'Inferior orbital fissure' and 'Foramen'.</p>
Fissure	Narrow, slitlike opening	
Foramen (fo-ra'men)	Round or oval opening through a bone	
Notch	Indentation at the edge of a structure	
<b>Others</b>		
Meatus (me-a'tus)	Canal-like passageway	
Sinus	Cavity within a bone, filled with air and lined with mucous membrane	
Fossa (fos'ah)	Shallow, basinlike depression in a bone, often serving as an articular surface	

(j) Others: bone (osseous tissue)

Description: **Hard, calcified matrix** containing many collagen fibers; osteocytes lie in lacunae. **Very well vascularized.**

Function: **Bone supports and protects** (by enclosing); provides levers for the muscles to act on; **stores** calcium and other minerals and fat; marrow inside bones is the site for **blood cell formation (hematopoiesis).**

Location: **Bones**

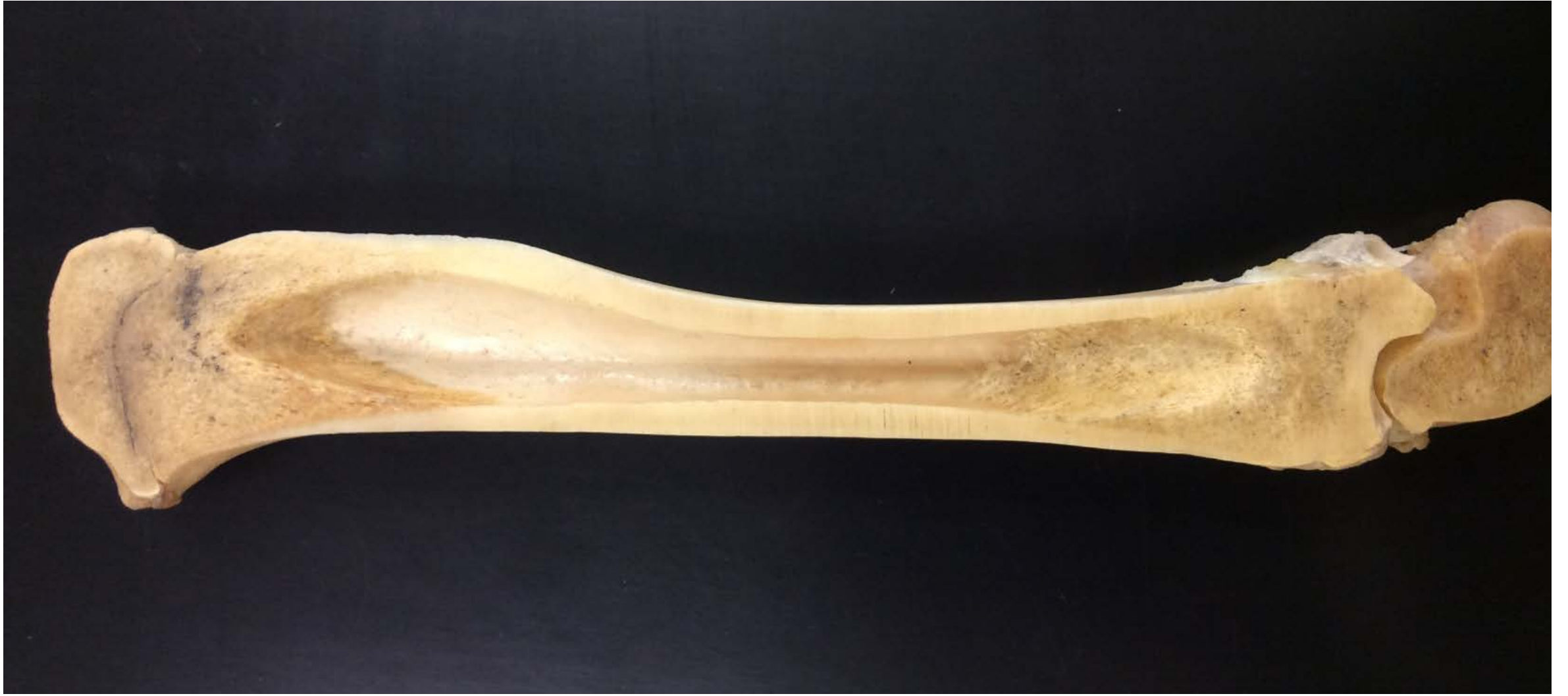

Central canal  
Lacunae  
Lamella

Photomicrograph: **Cross-sectional view of bone (125x).**

Use the following pictures to help you practice finding the terms from the lab term handout on unlabeled images.

- Remember, you won't learn them if you don't take plenty of time to practice!
- Also, be sure to mix up the order once you get comfortable with the unlabeled slides.
- Over the weekend, once you are feeling confident with the pictures here, do the bone model quizzes in PAL (from the Pearson website) to get practice with new pictures that you haven't seen.

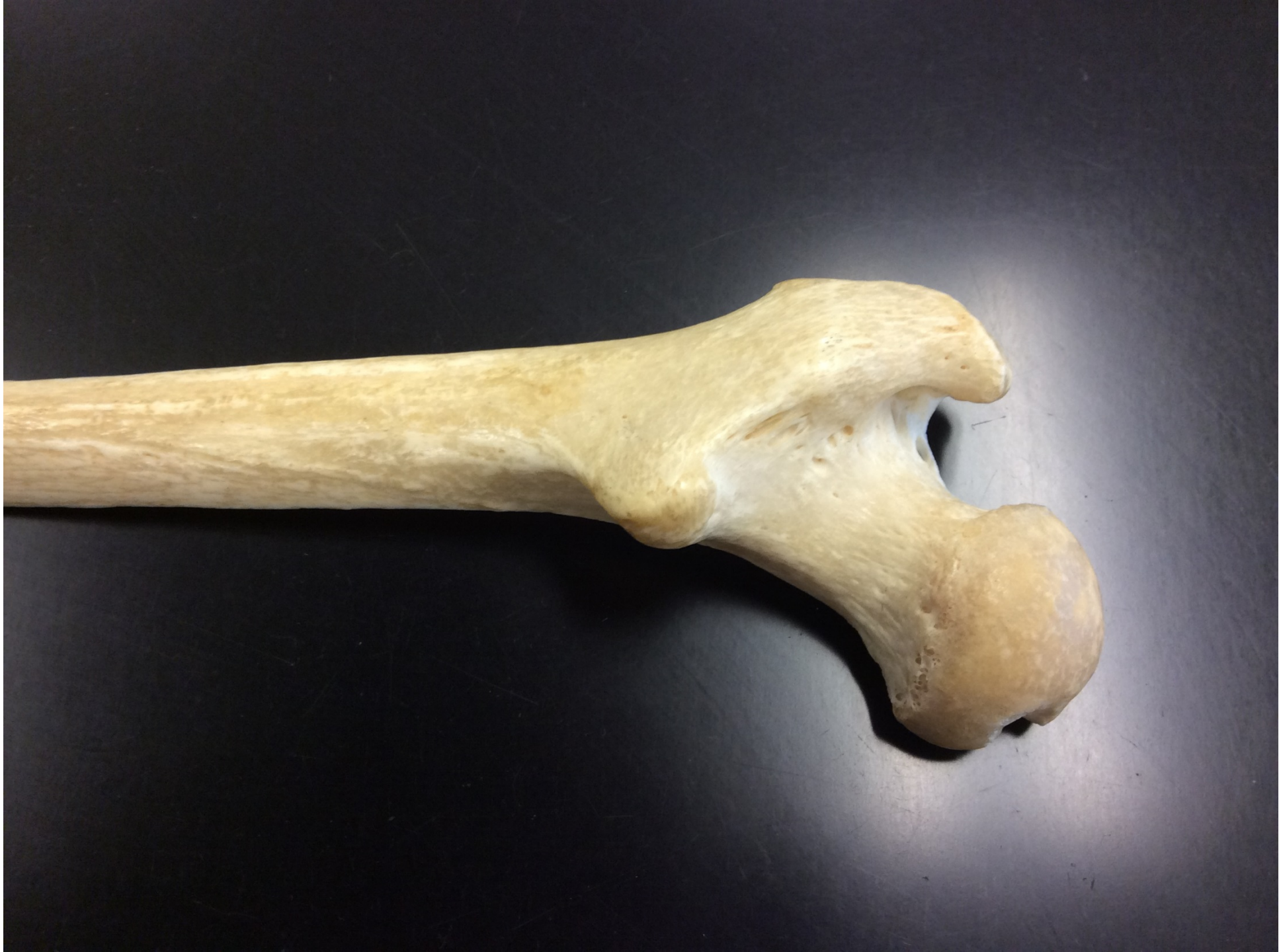






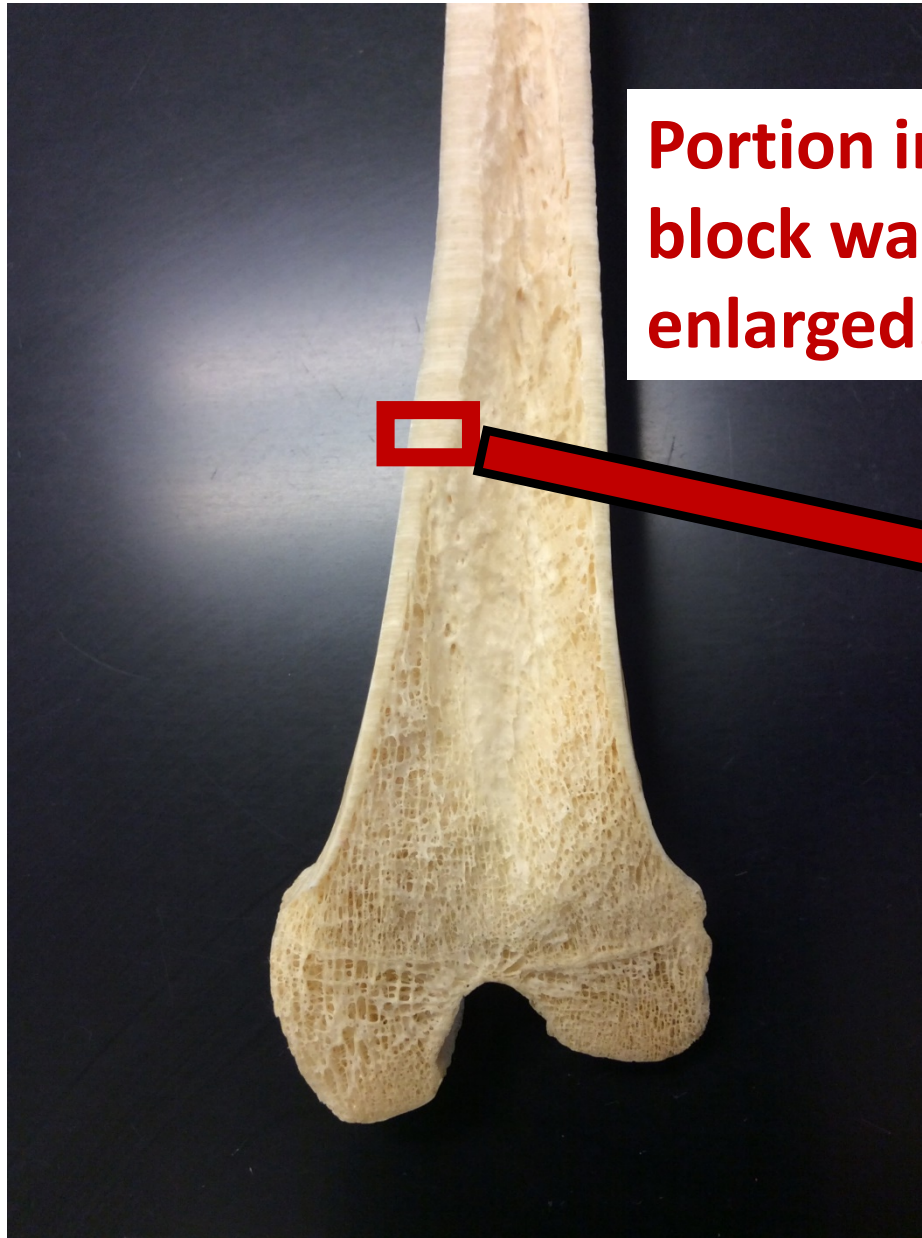







This picture is not for labeling,  
but is to show you what the below model  
is showing you.


Portion inside the  
block was cut out and  
enlarged.



**Slice from the side  
of a long bone.**



**Slice from the side  
of a long bone.**





**Slice from the side  
of a long bone.**






This picture is not for labeling, but is to show you what the below model is showing you.


Portion inside the circle was cut out and enlarged.



# One osteon and edges of nearby osteons

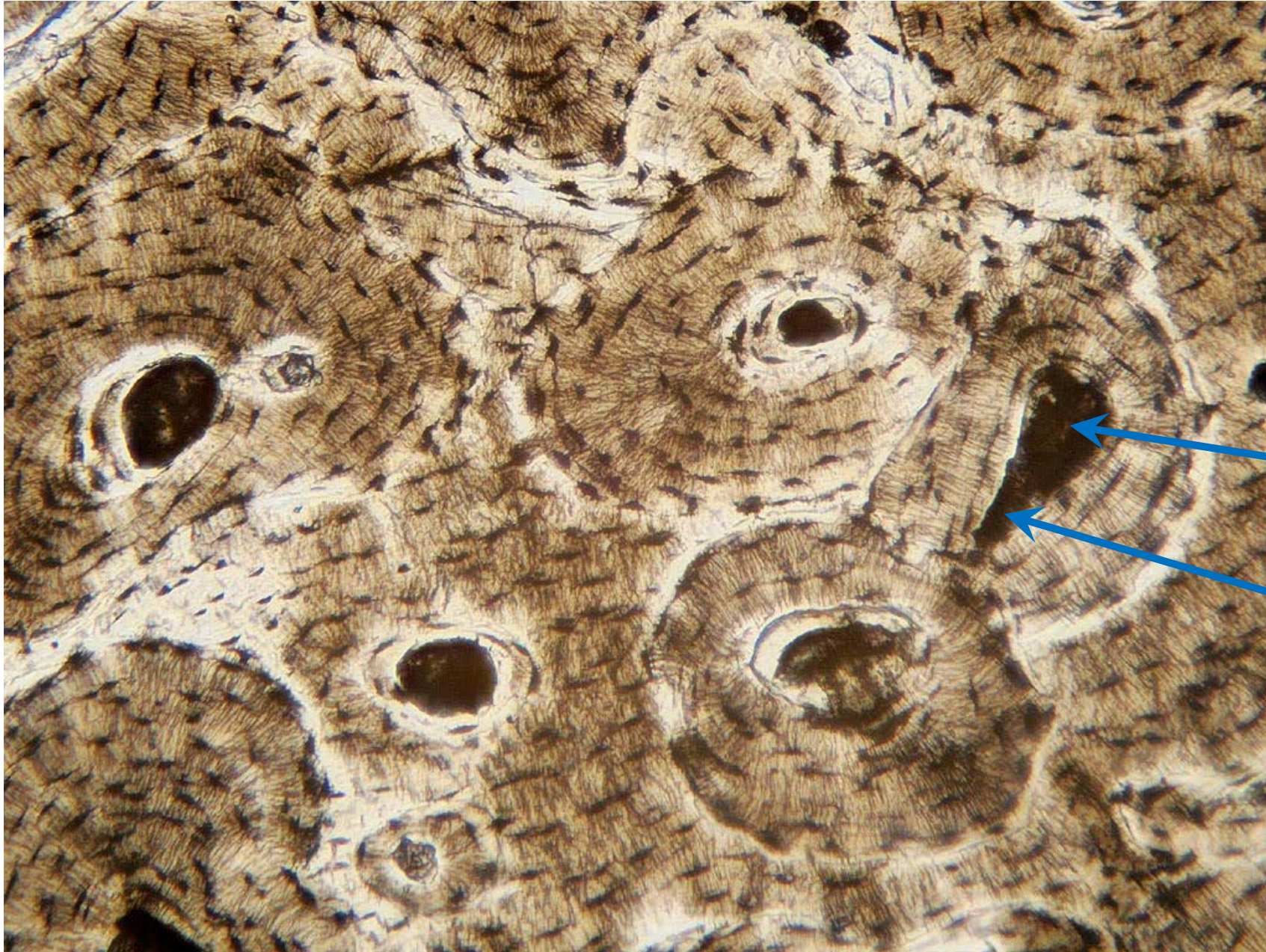


**One osteon**  
and edges of  
nearby osteons

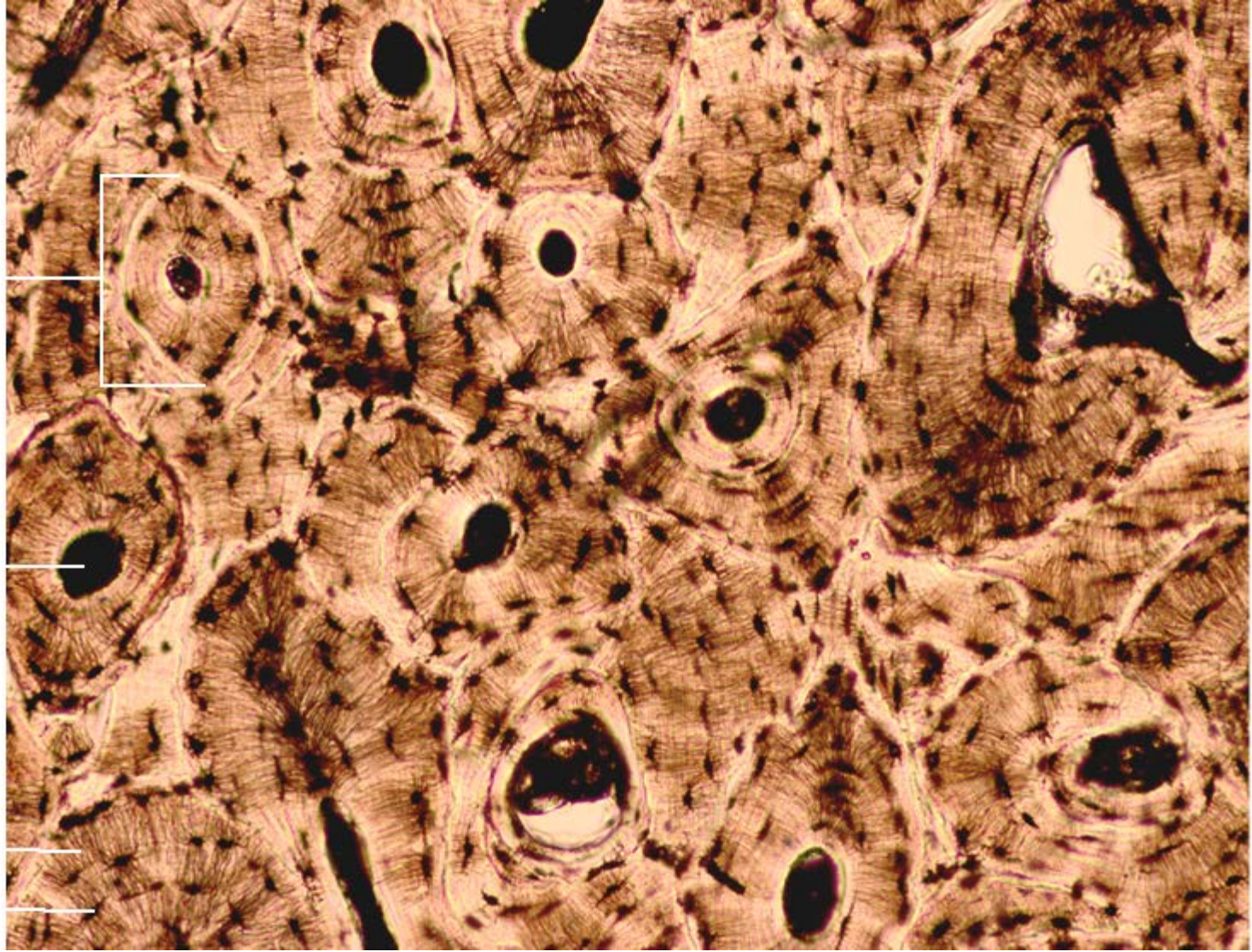

**One osteon**  
and edges of  
nearby osteons





Hint: The arrows are pointing to 2 different open spaces that connect to each other.



3

4

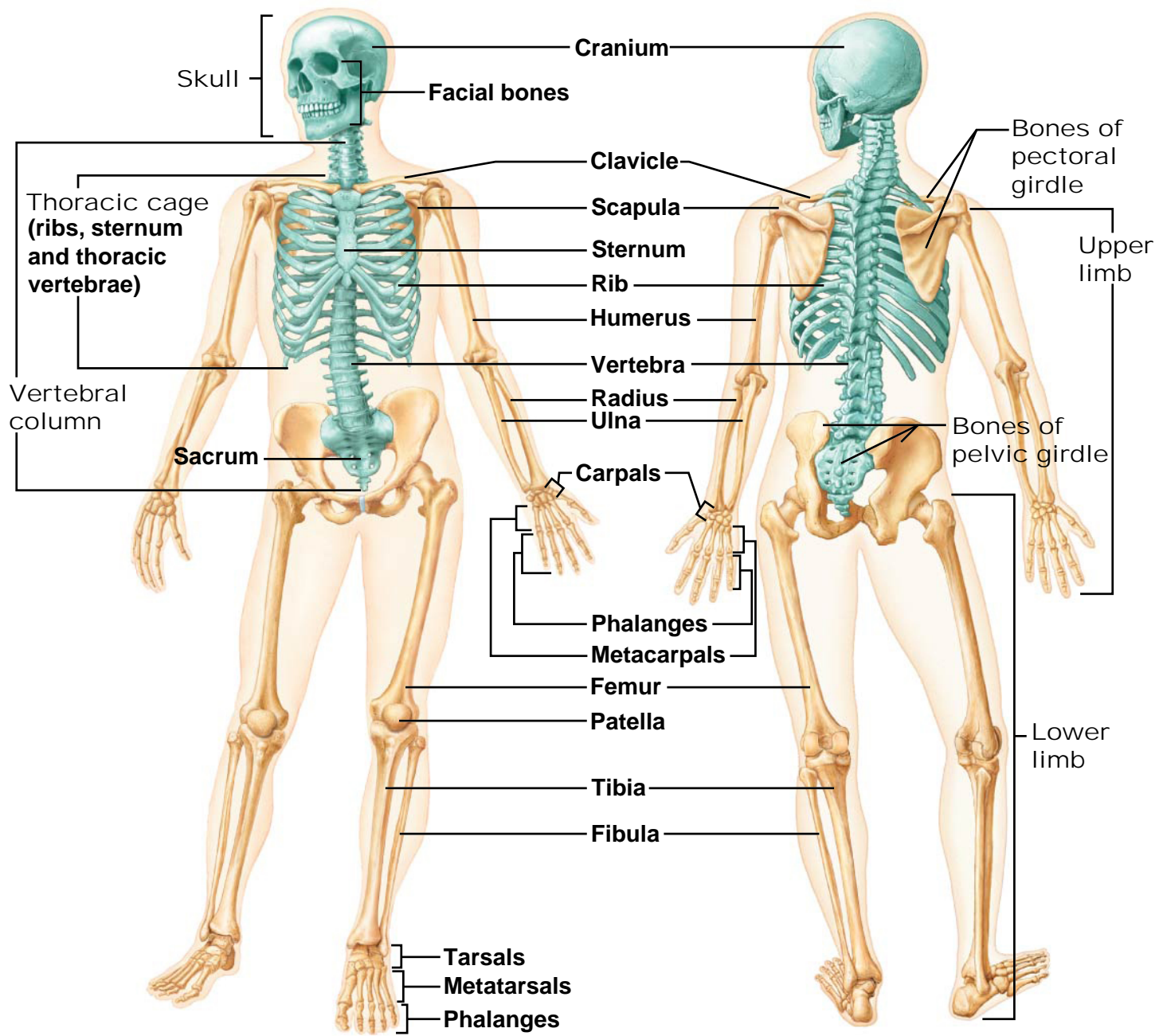
# Use the following pictures to help you identify terms from the lab term handout.

Another good resource is the Visible Body app: <http://skeleton.visiblebody.com>

Don't forget that to use the link to download to a personal device, the device must first be connected to the MCPA Wi-Fi at the Rockville campus.

**\*\*If you feel like you are struggling**, there are videos that can help you! Go to the textbook website and select the tab on the left labeled "Study Area (myA&P)". Next, there will be a lot of tabs on the left of the screen...look for "Lab Videos" and select "Bone and Dissection Videos." Watch whichever bone videos you need (in the box on the left).

Figure 7.1 The human skeleton.

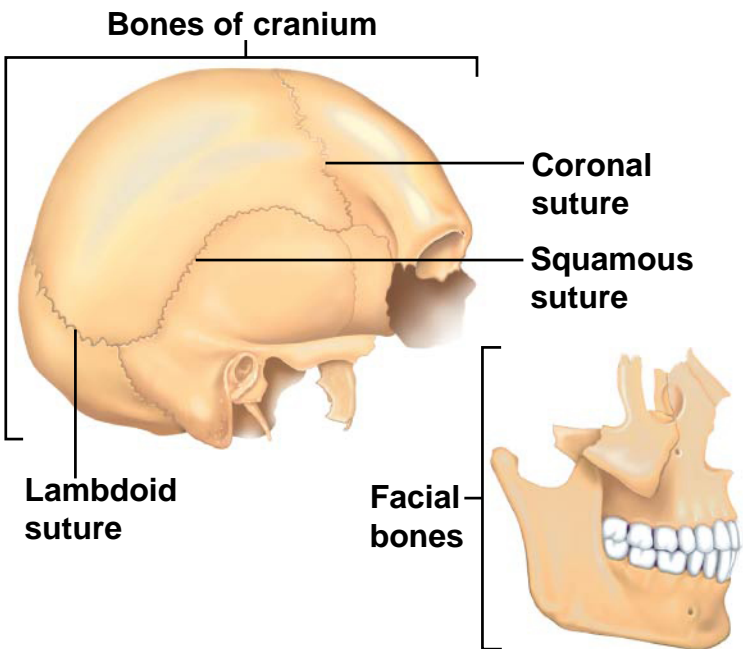


(a) Anterior view

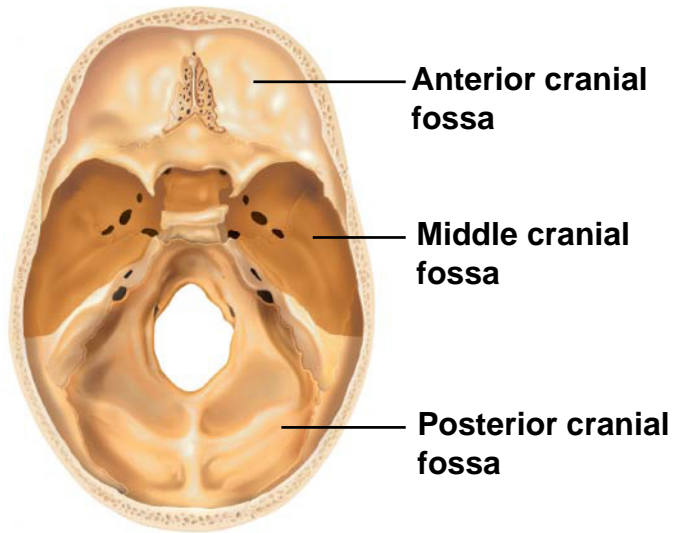
(b) Posterior view



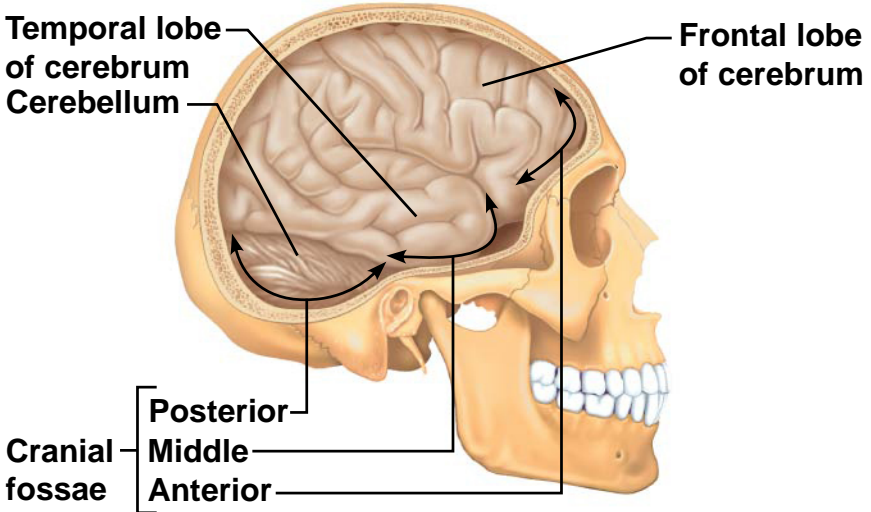
Figure 7.2 The skull.



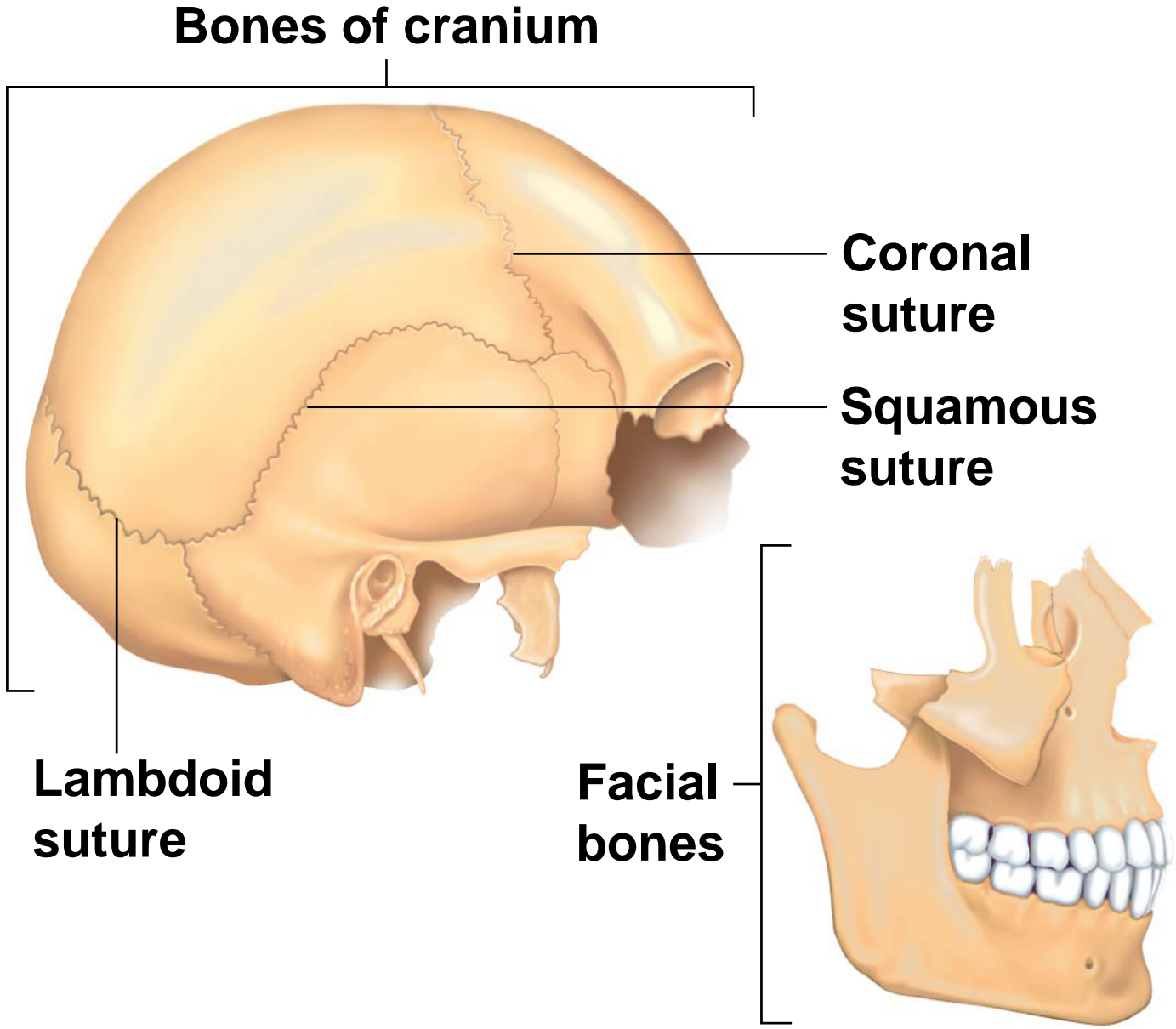
(a) Cranial and facial divisions of the skull



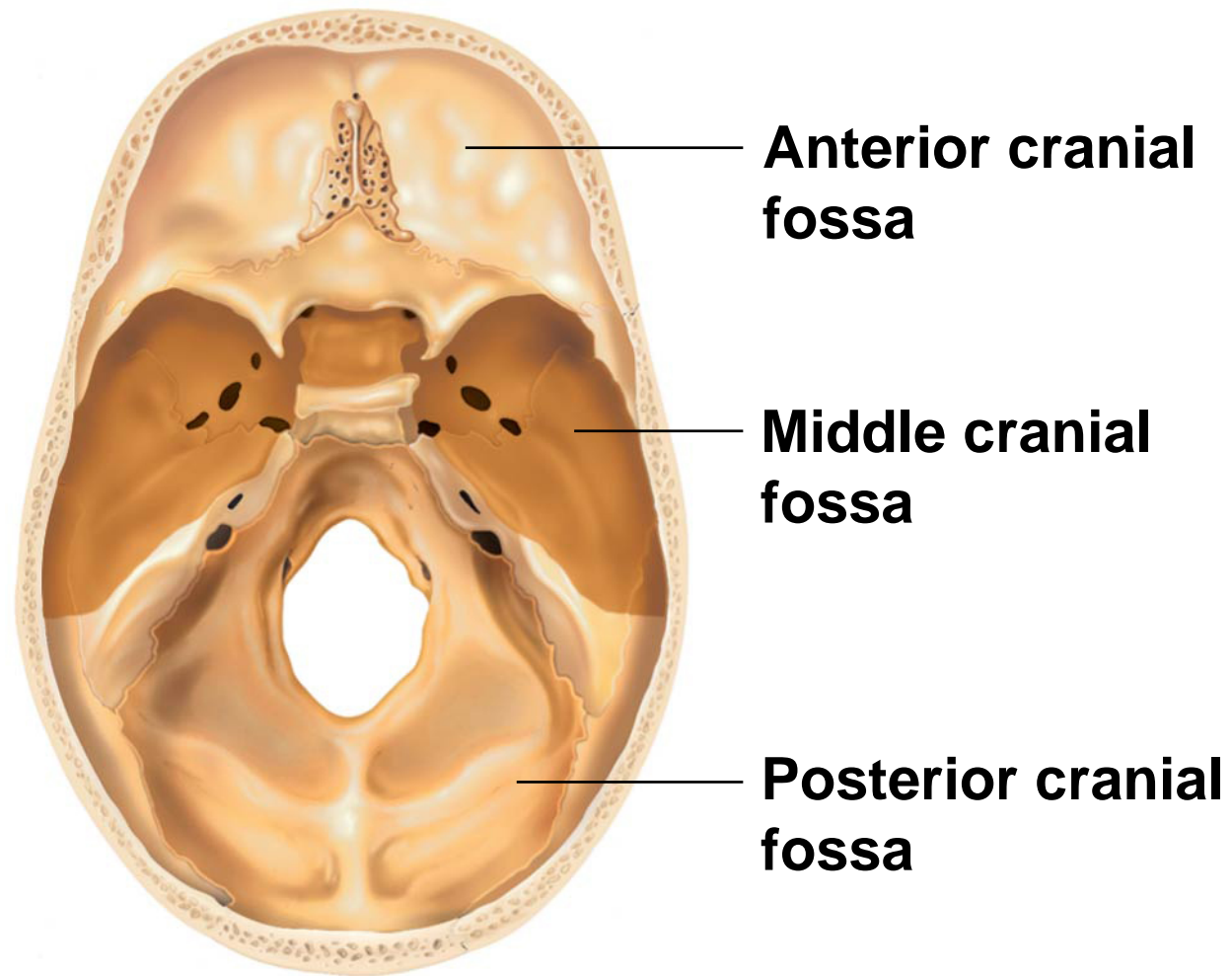
(b) Superior view of the cranial fossae



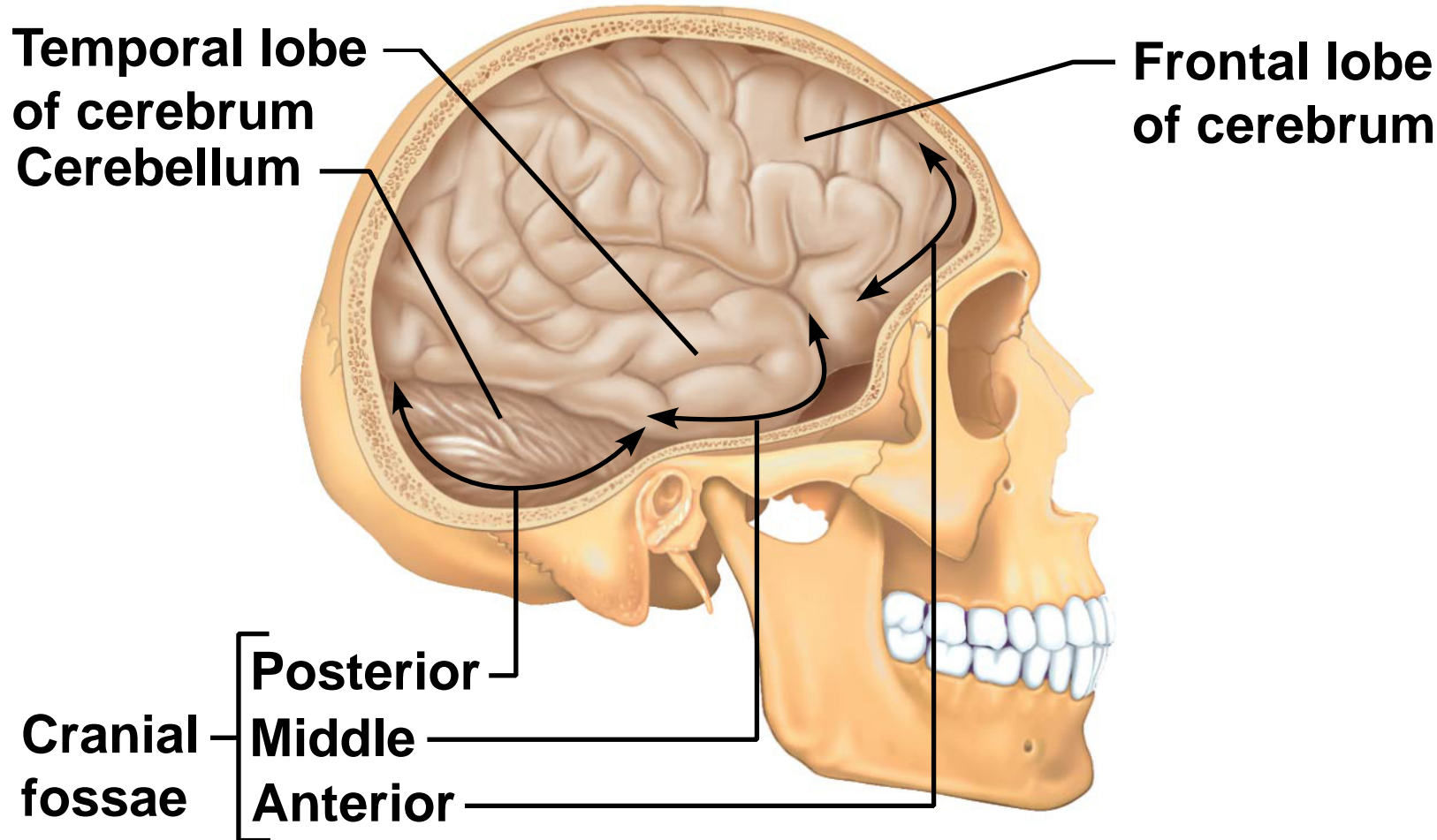
(c) Lateral view of cranial fossae showing the contained brain regions



**(a)** Cranial and facial divisions of the skull



**(b)** Superior view of the cranial fossae



**(c)** Lateral view of cranial fossae showing the contained brain regions

Figure 7.3 Major cavities of the skull, frontal section.

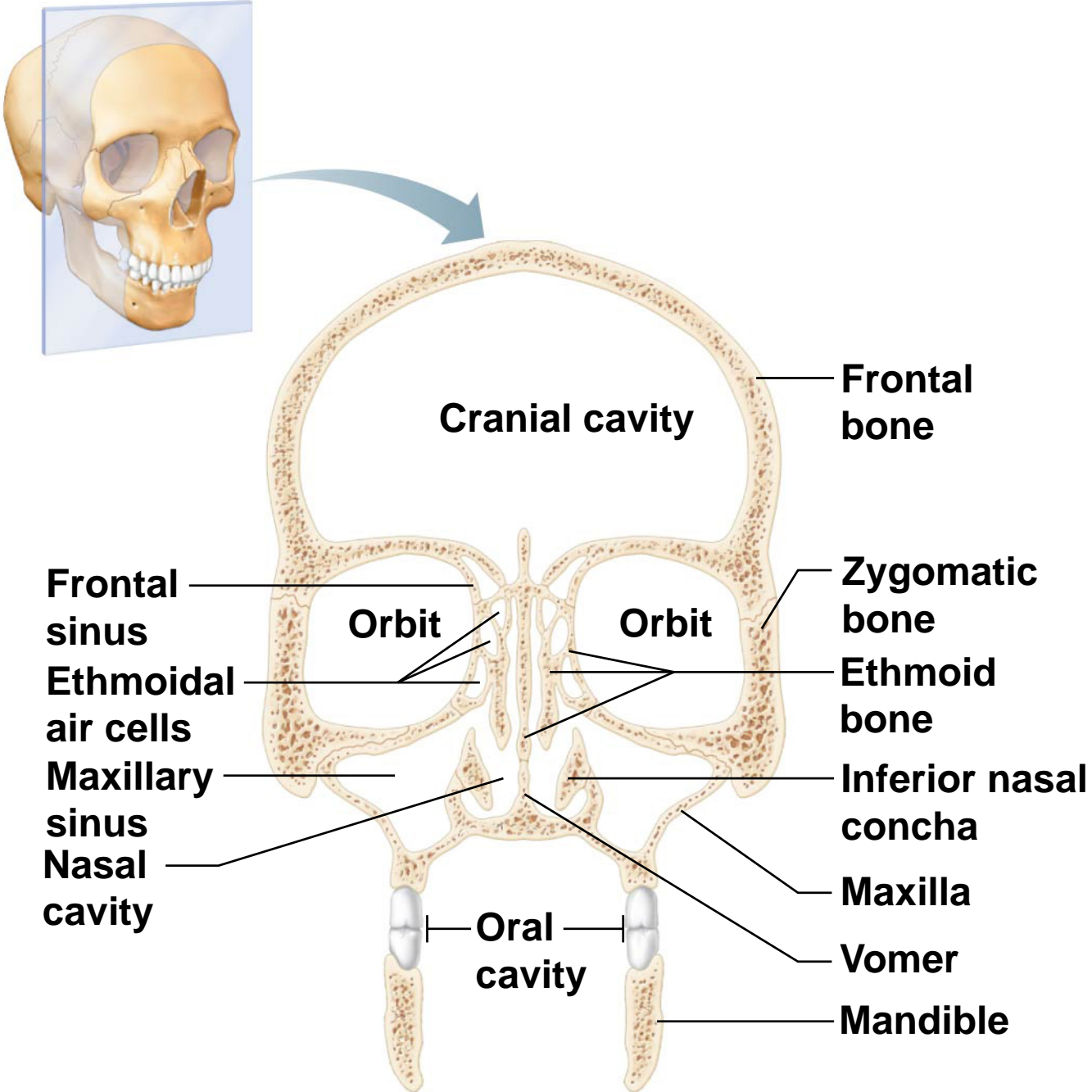


Figure 7.4 Anterior and posterior views of the skull.

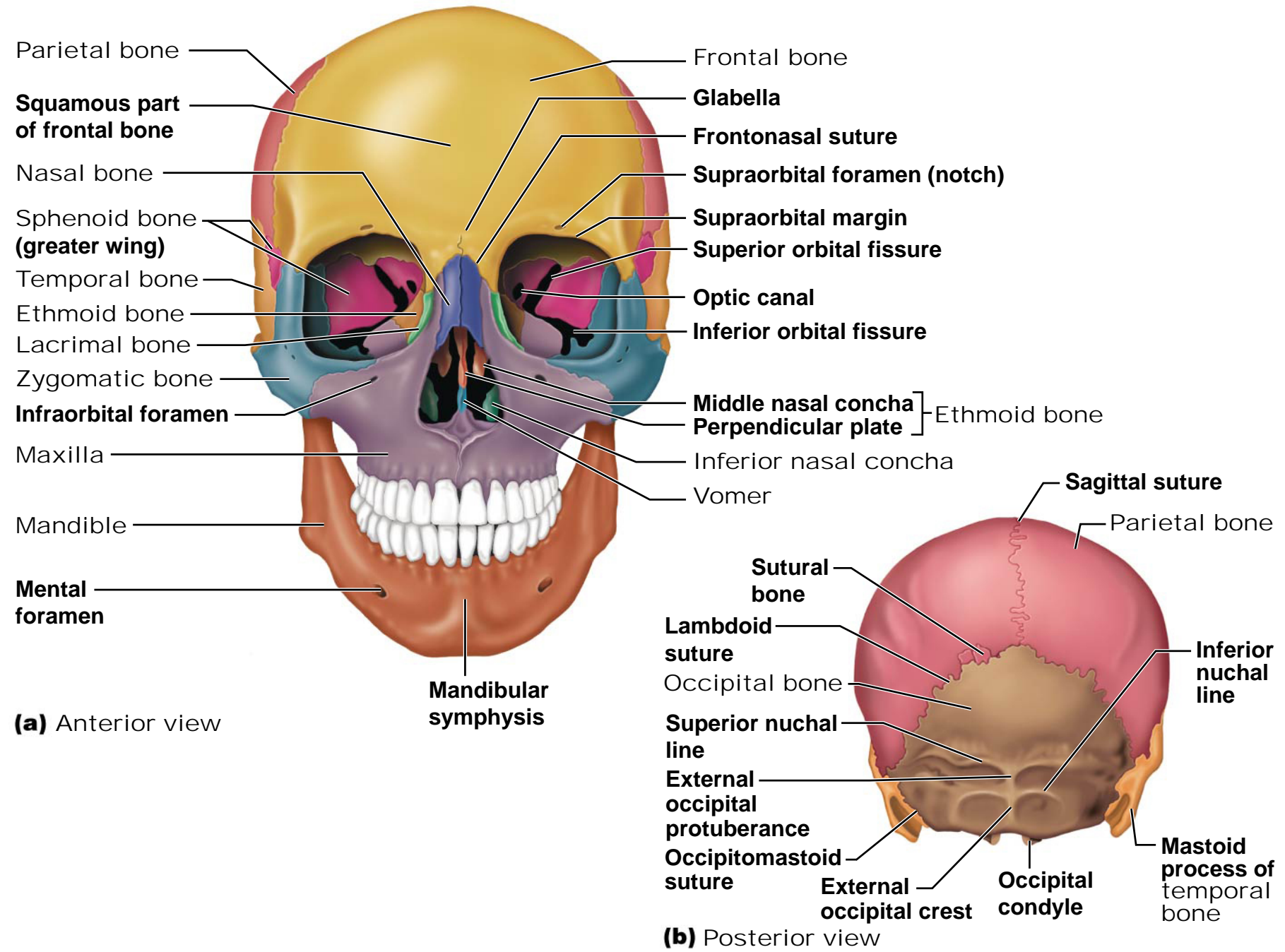
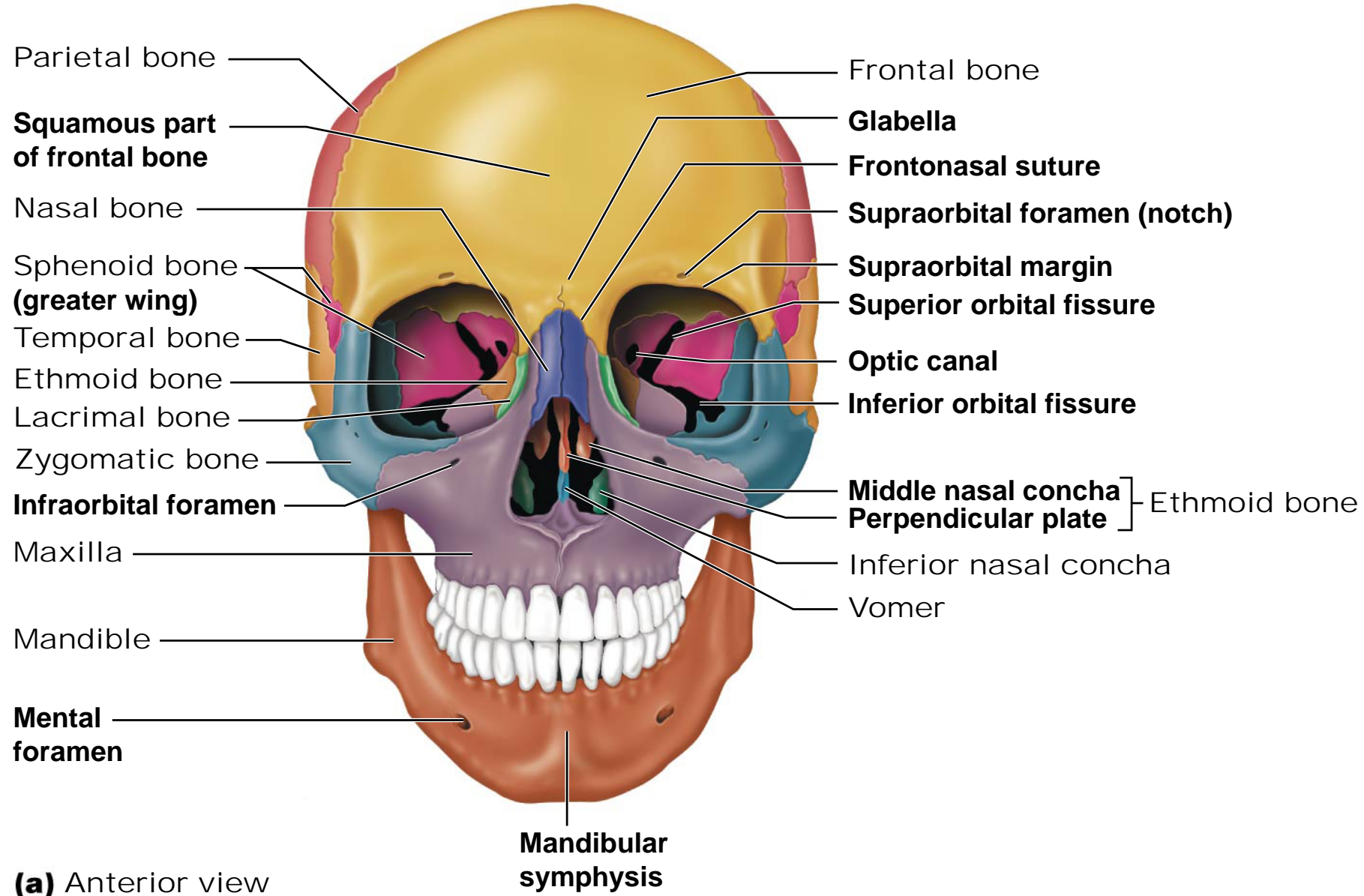
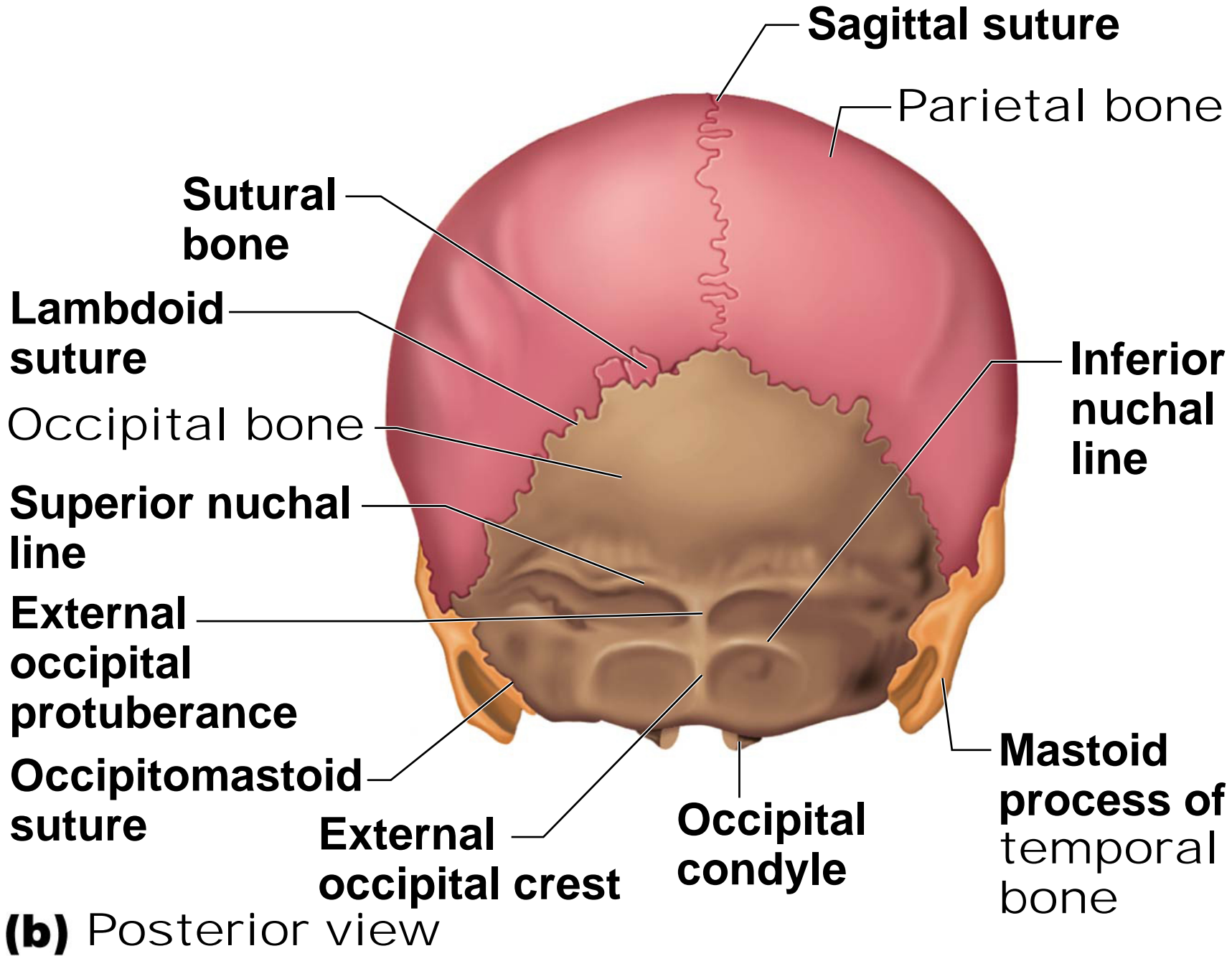


Figure 7.4a Anterior and posterior views of the skull.



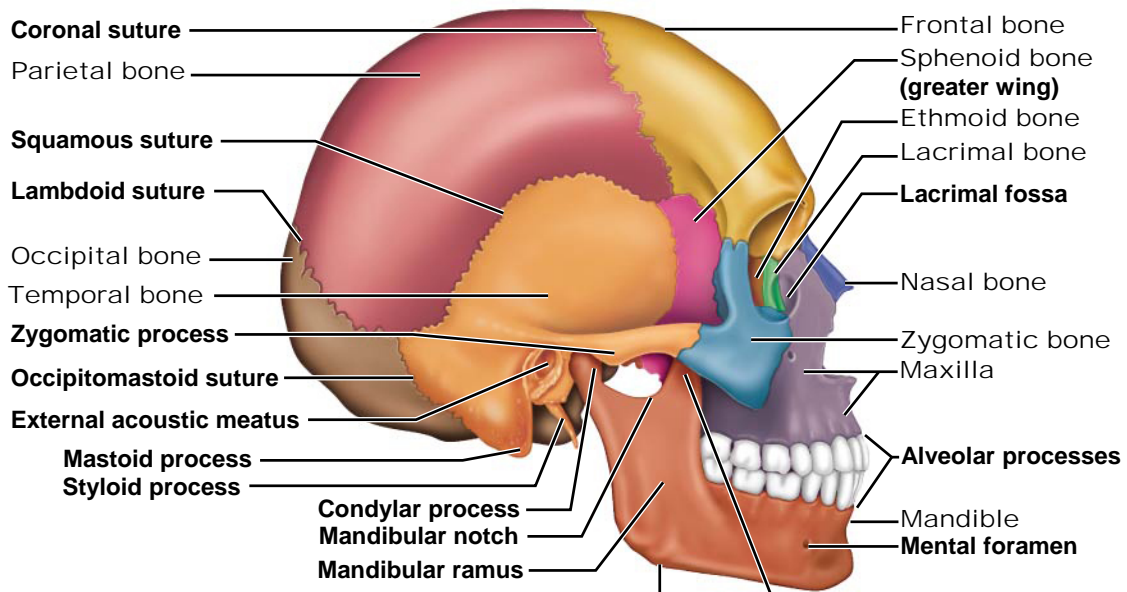
(a) Anterior view

Figure 7.4b Anterior and posterior views of the skull.

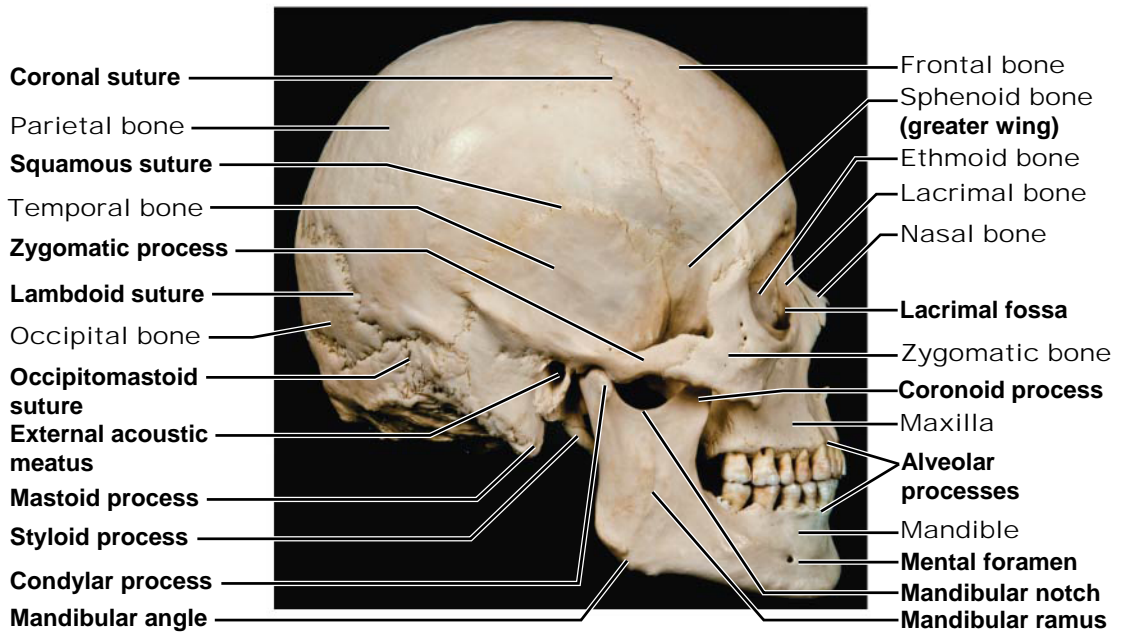




**Figure 7.5** Bones of the lateral aspect of the skull, external and internal views.

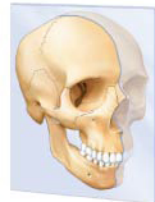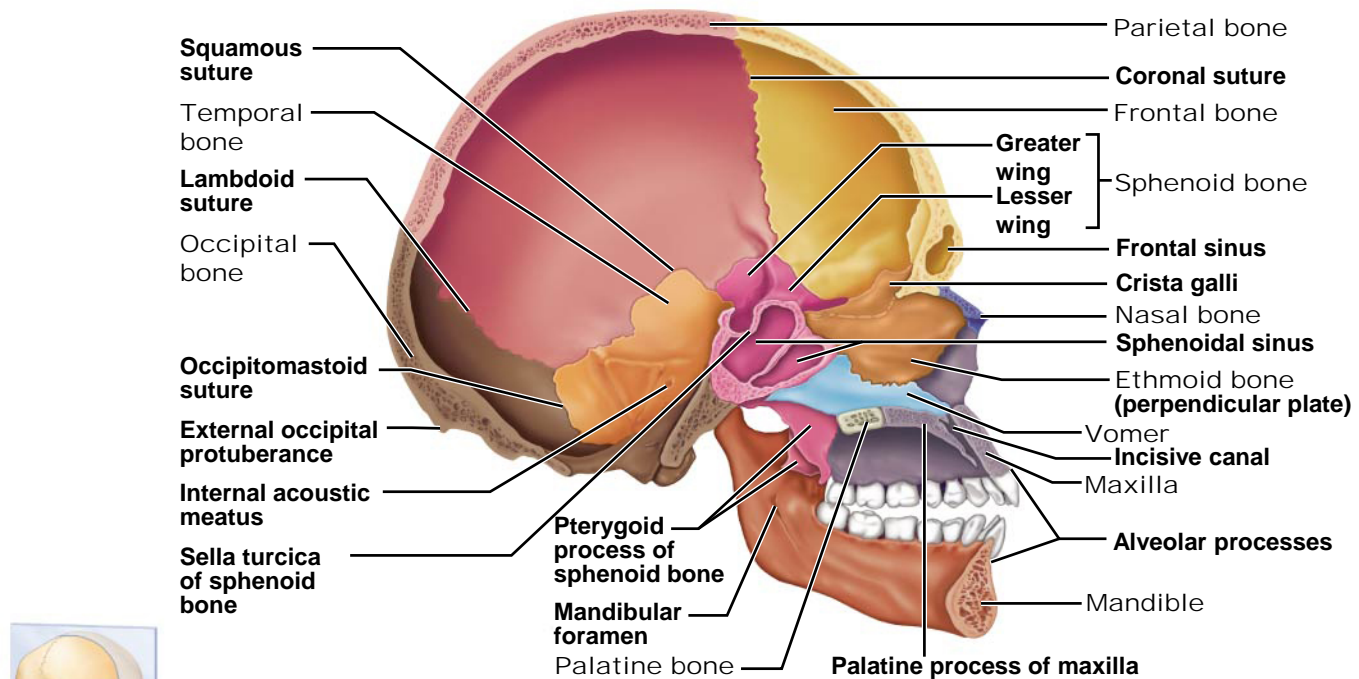


**(a)** External anatomy of the right side of the skull

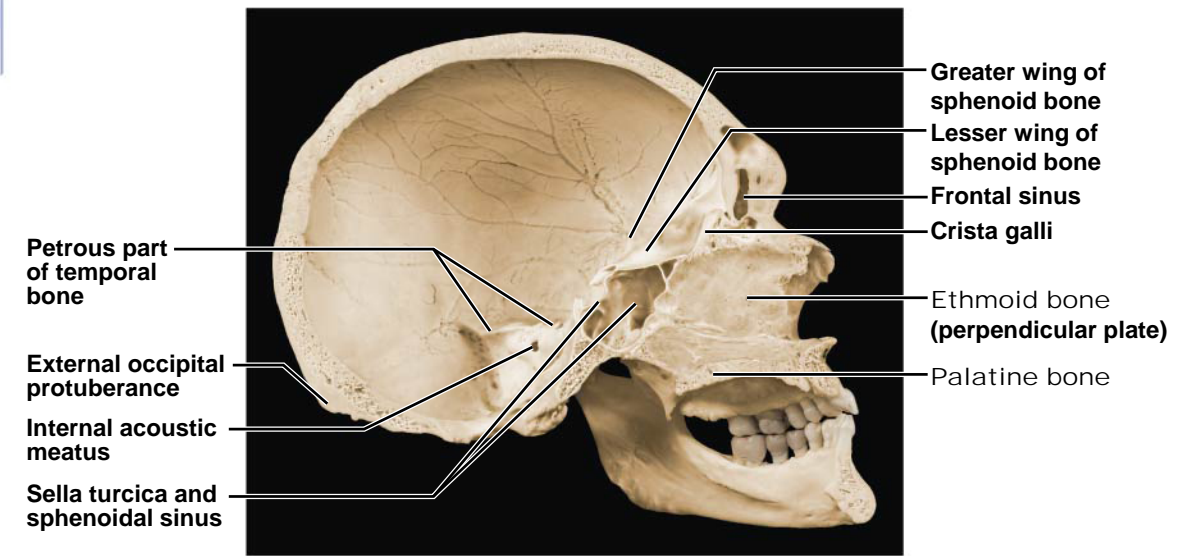


**(b)** Photograph of right side of skull

Figure 7.5 Bones of the lateral aspect of the skull, external and internal views (continued).



(c) Midsagittal section showing the internal anatomy of the left half of skull



(d) Photo of skull cut through the midline, same view as in (c)

Figure 7.5a Bones of the lateral aspect of the skull, external and internal views.

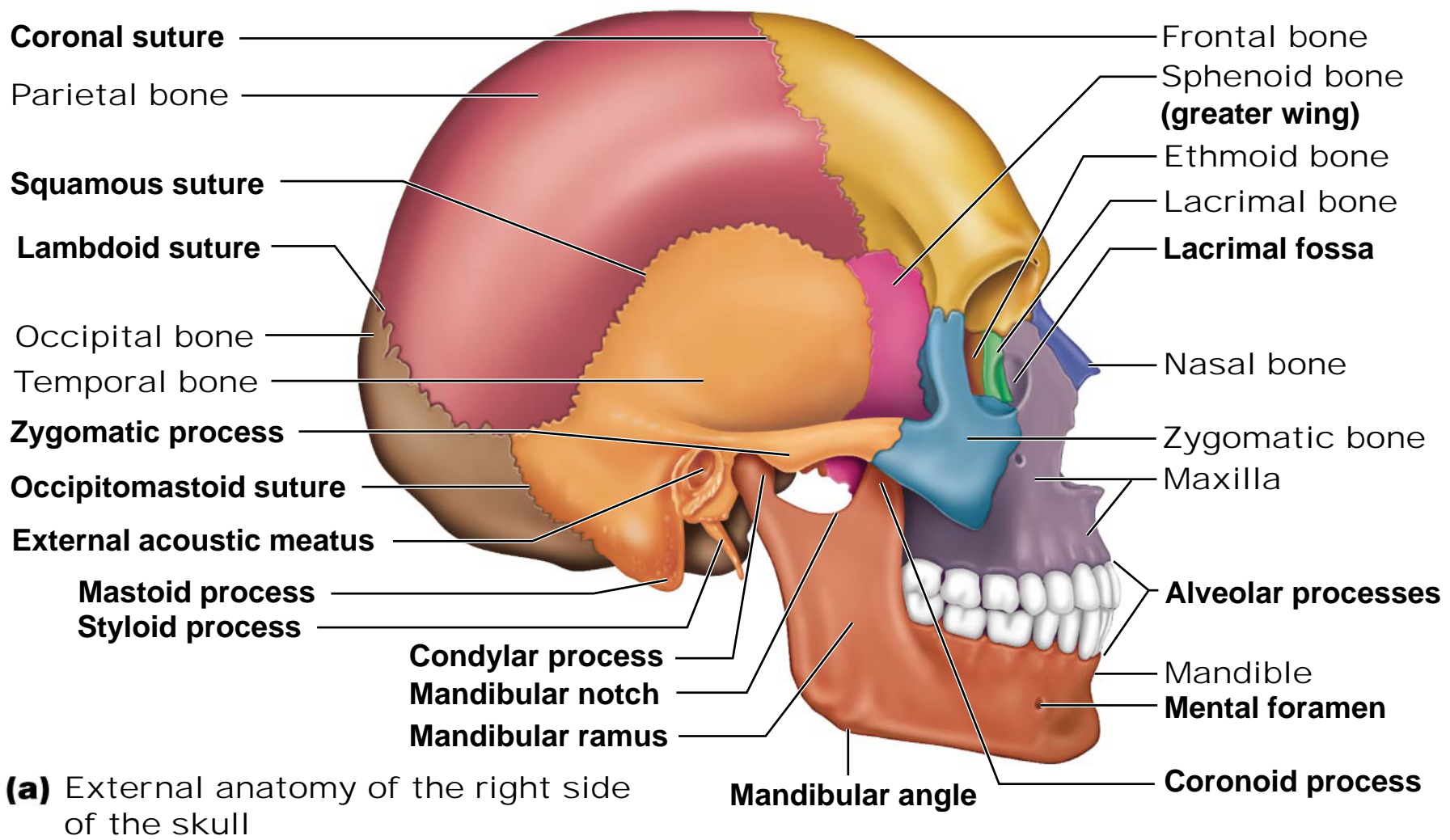
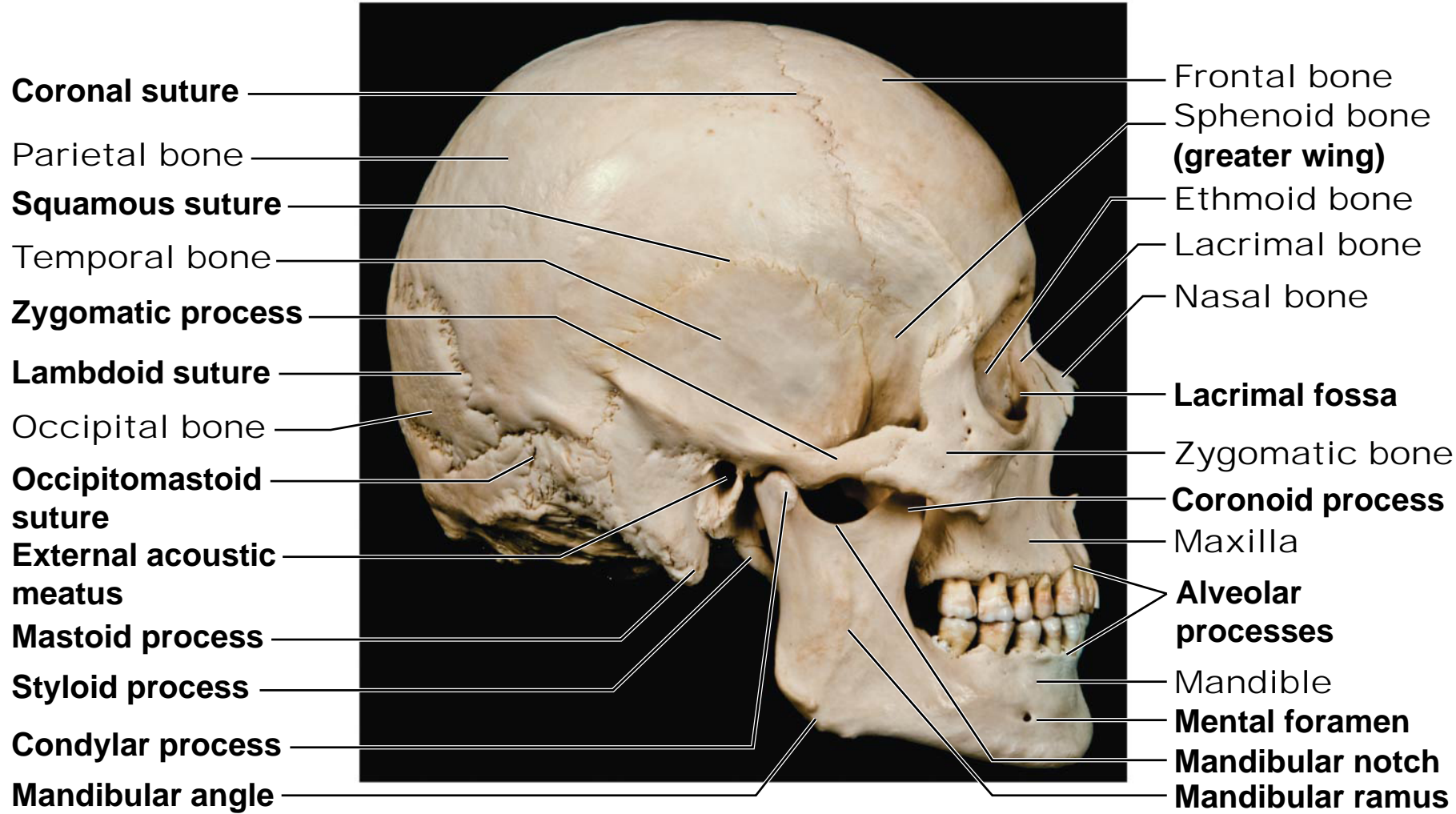
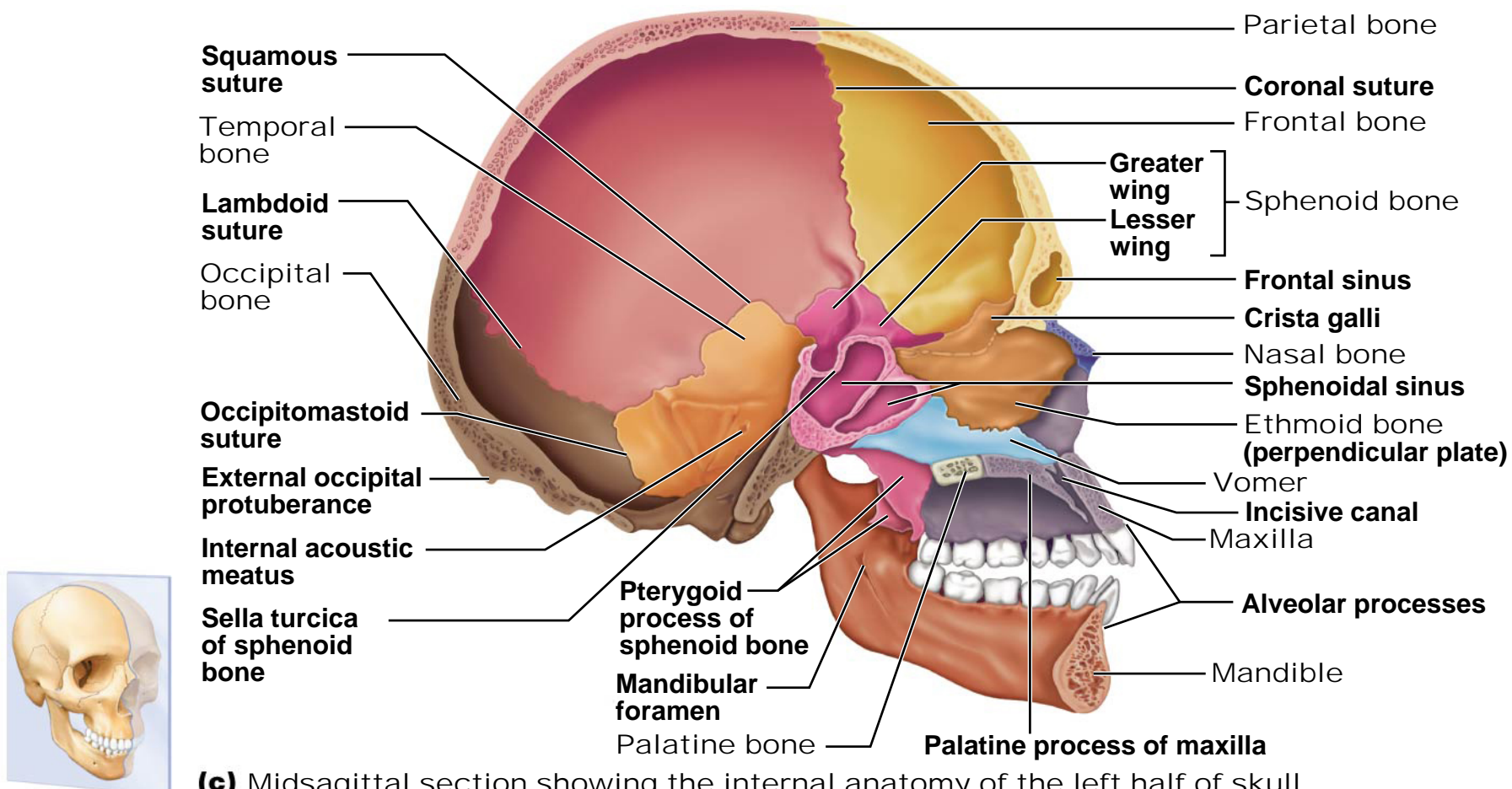


Figure 7.5b Bones of the lateral aspect of the skull, external and internal views.



**(b)** Photograph of right side of skull

Figure 7.5c Bones of the lateral aspect of the skull, external and internal views.



(c) Midsagittal section showing the internal anatomy of the left half of skull

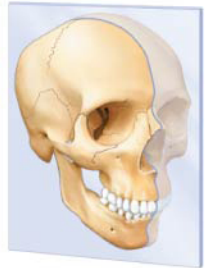
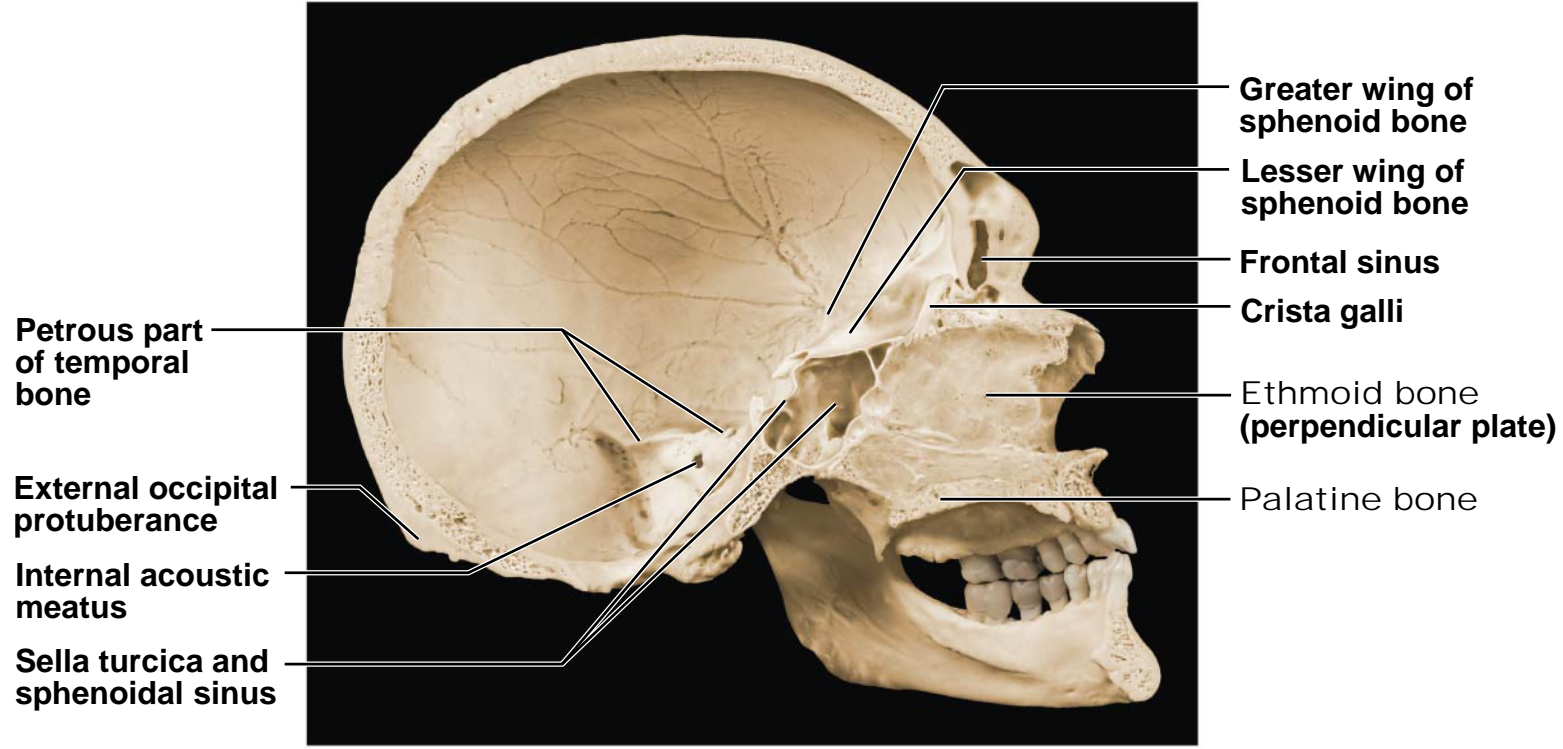
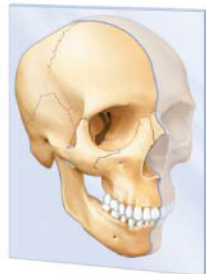
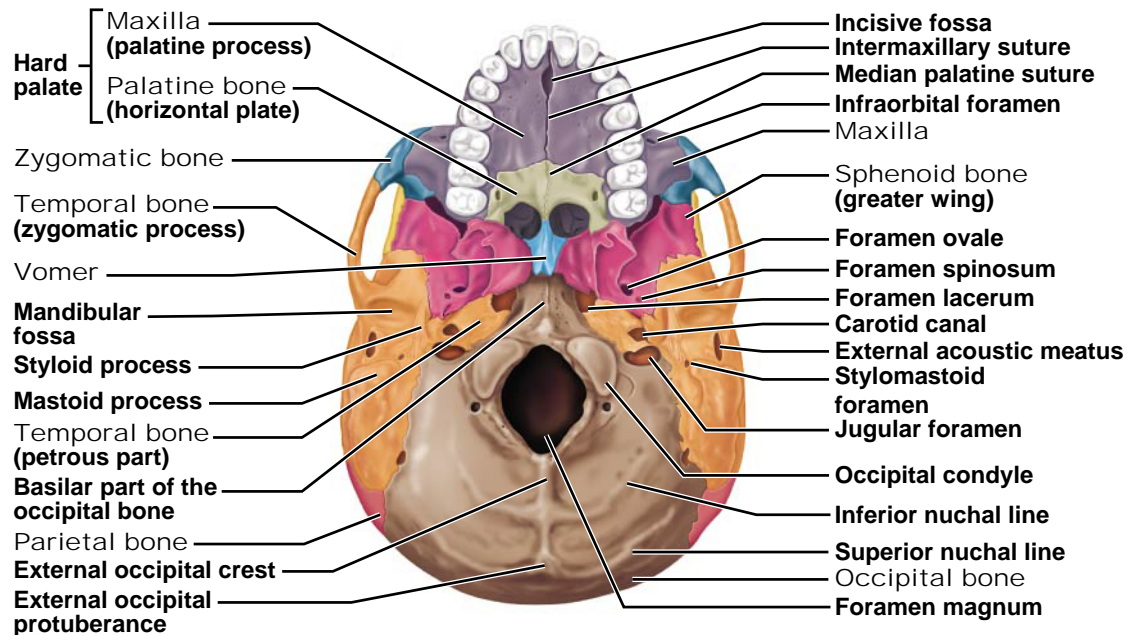


Figure 7.5d Bones of the lateral aspect of the skull, external and internal views.

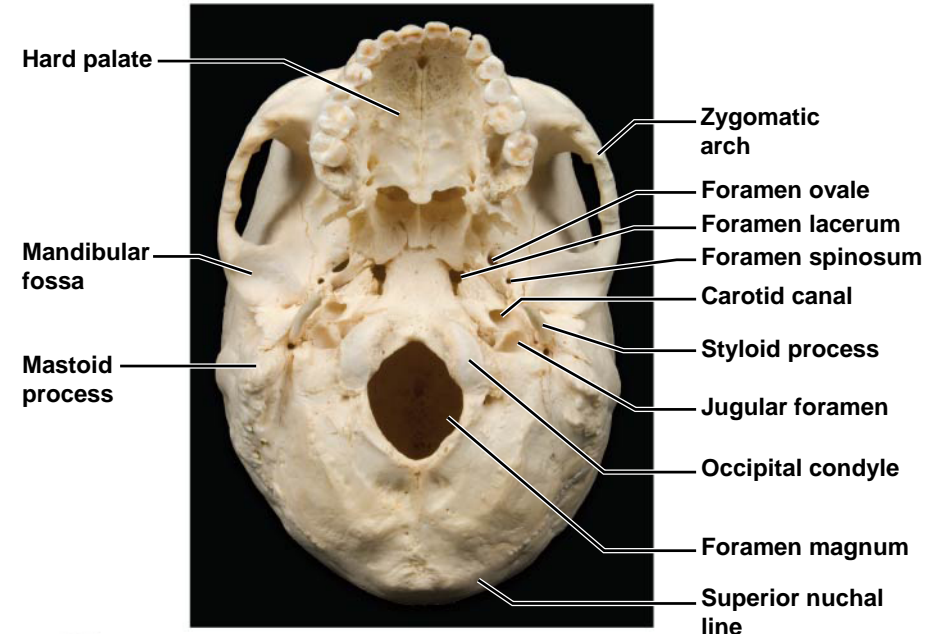


**(d)** Photo of skull cut through the midline, same view as in (c)

Figure 7.6 Inferior aspect of the skull, mandible removed.

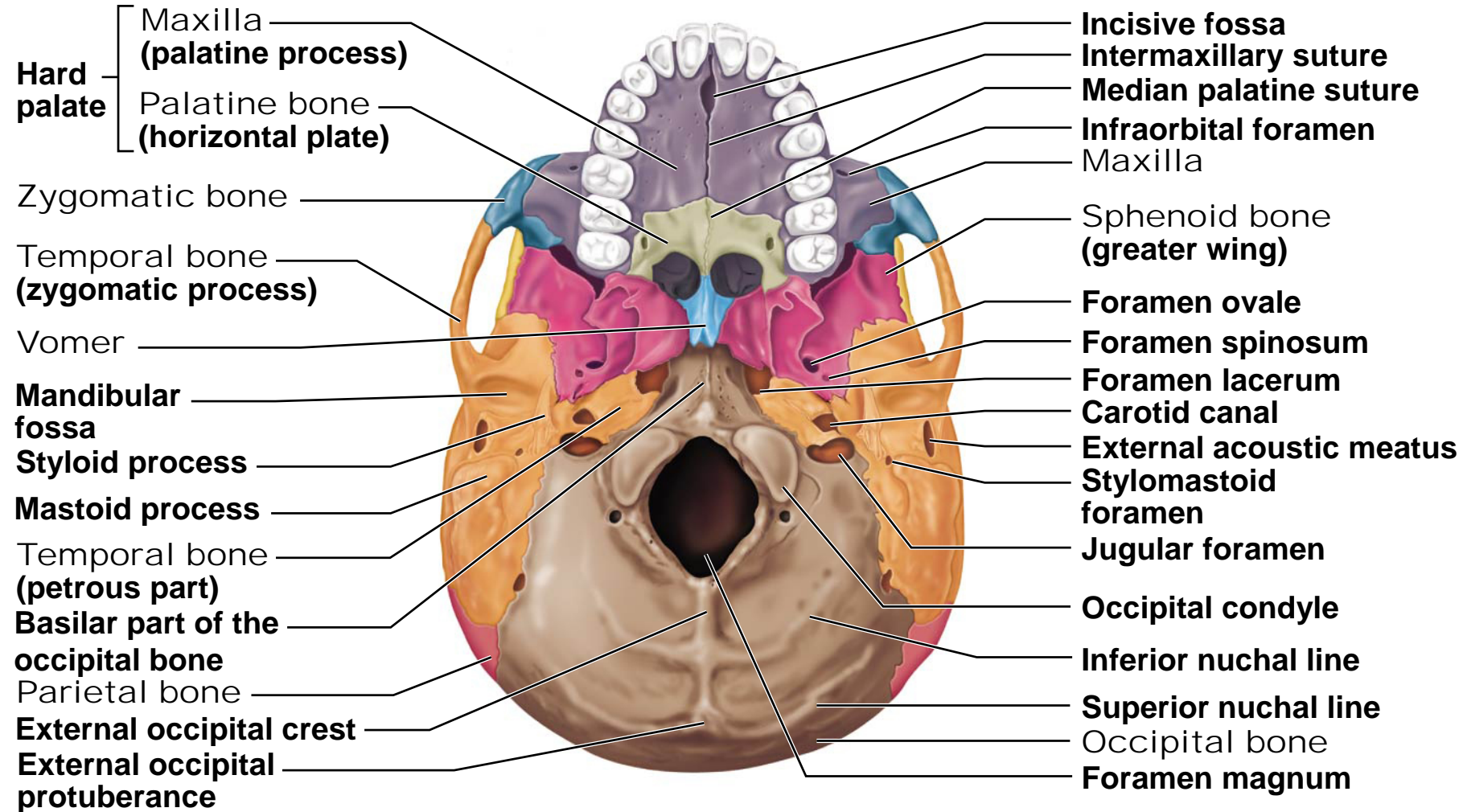


(a) Inferior view of the skull (mandible removed)



(b) Photo of inferior view of the skull

Figure 7.6a Inferior aspect of the skull, mandible removed.



(a) Inferior view of the skull (mandible removed)

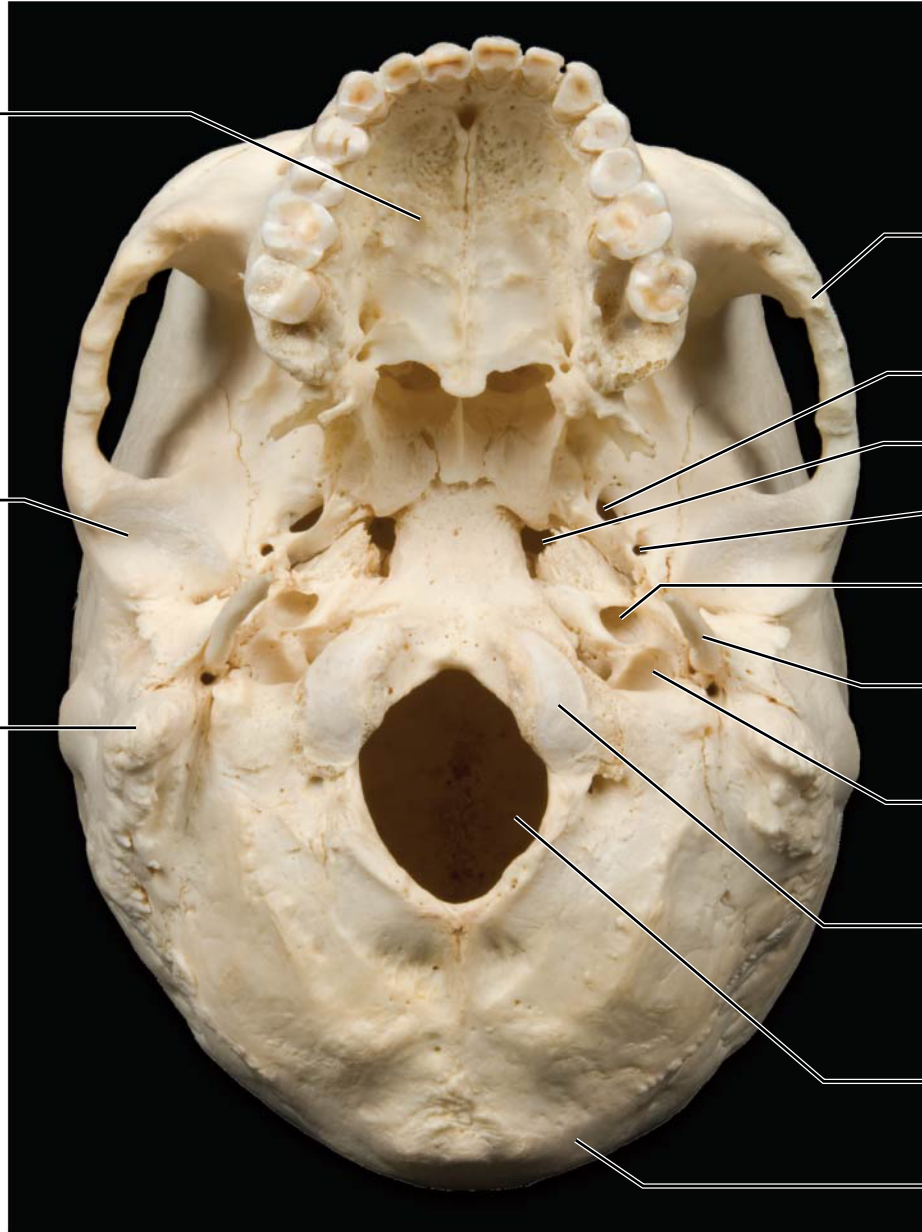


Figure 7.6b Inferior aspect of the skull, mandible removed.

**Hard palate**

**Mandibular fossa**

**Mastoid process**



**Zygomatic arch**

**Foramen ovale**

**Foramen lacerum**

**Foramen spinosum**

**Carotid canal**

**Styloid process**

**Jugular foramen**

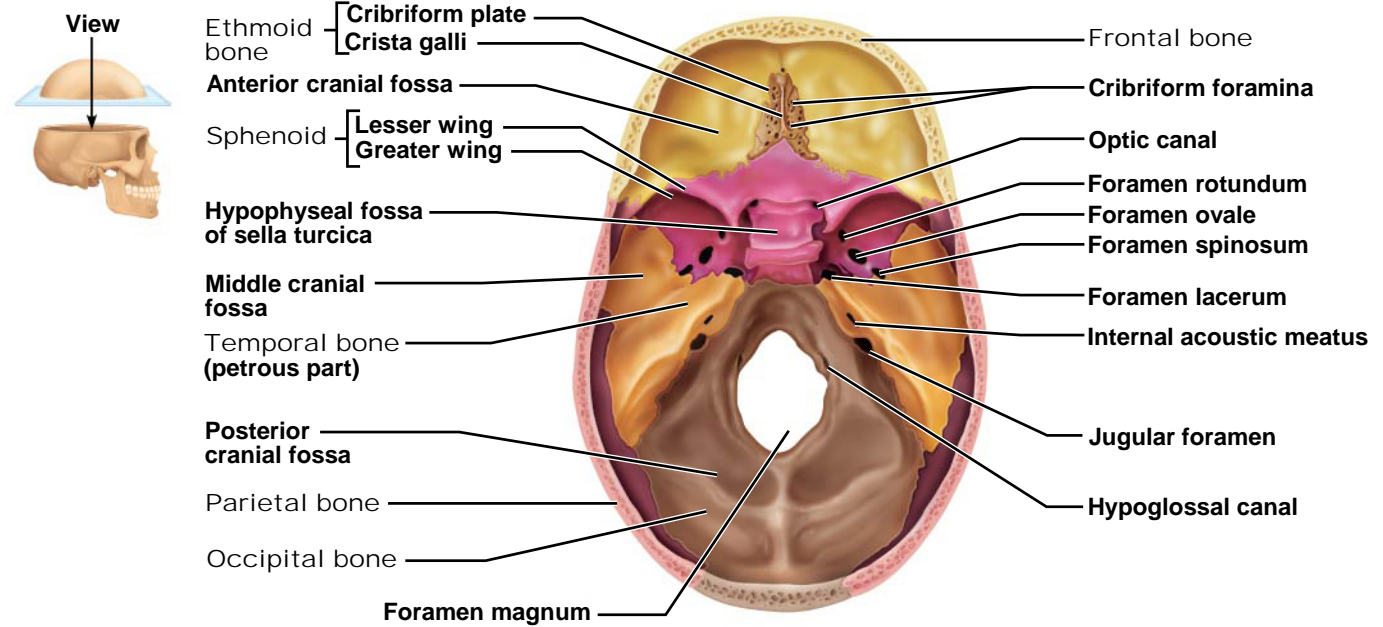
**Occipital condyle**

**Foramen magnum**

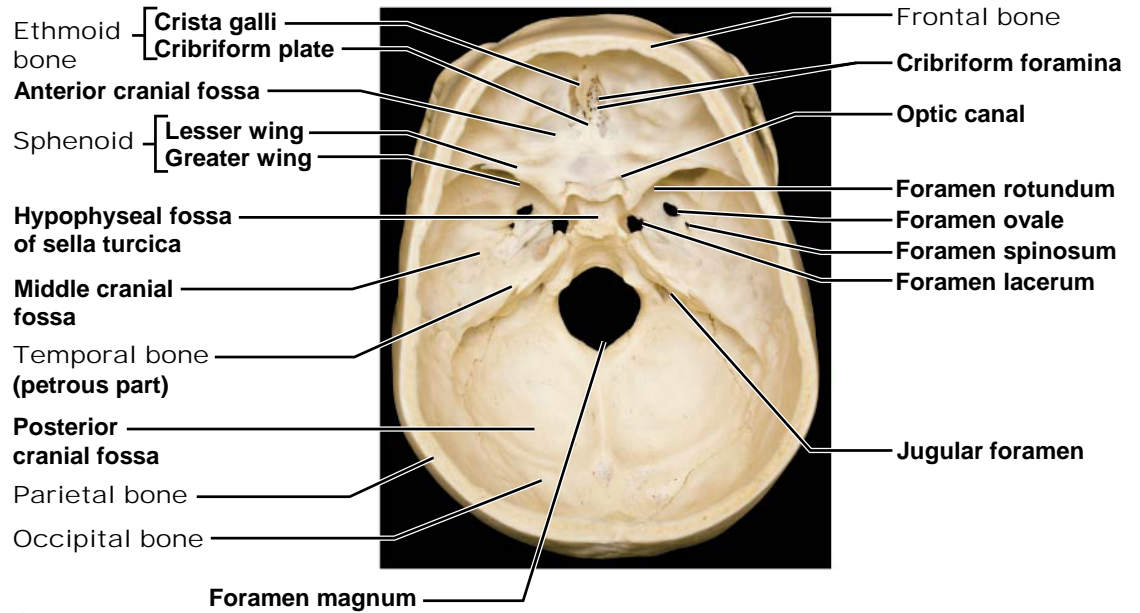
**Superior nuchal line**

**(b)** Photo of inferior view of the skull

Figure 7.7 The base of the cranial cavity.

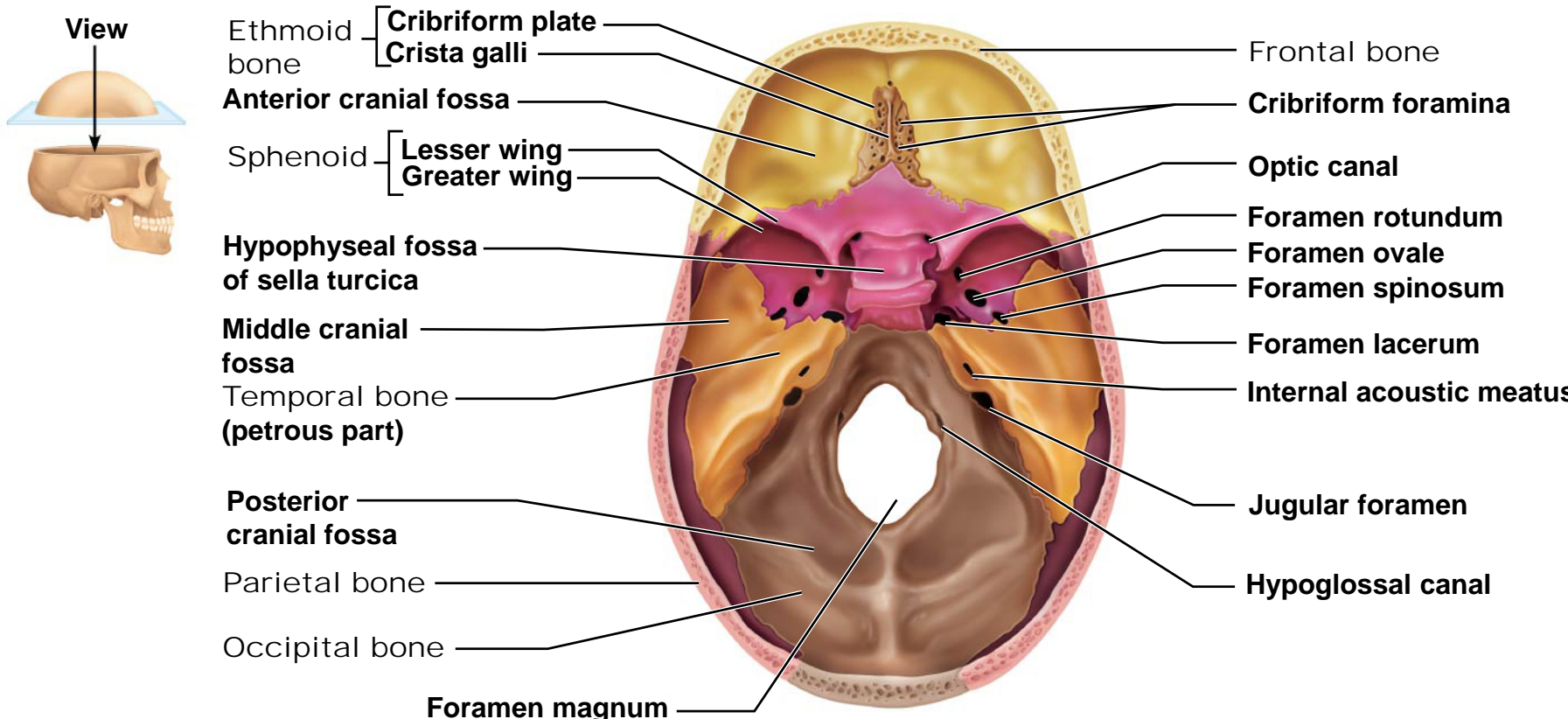


(a) Superior view of the skull, calvaria removed



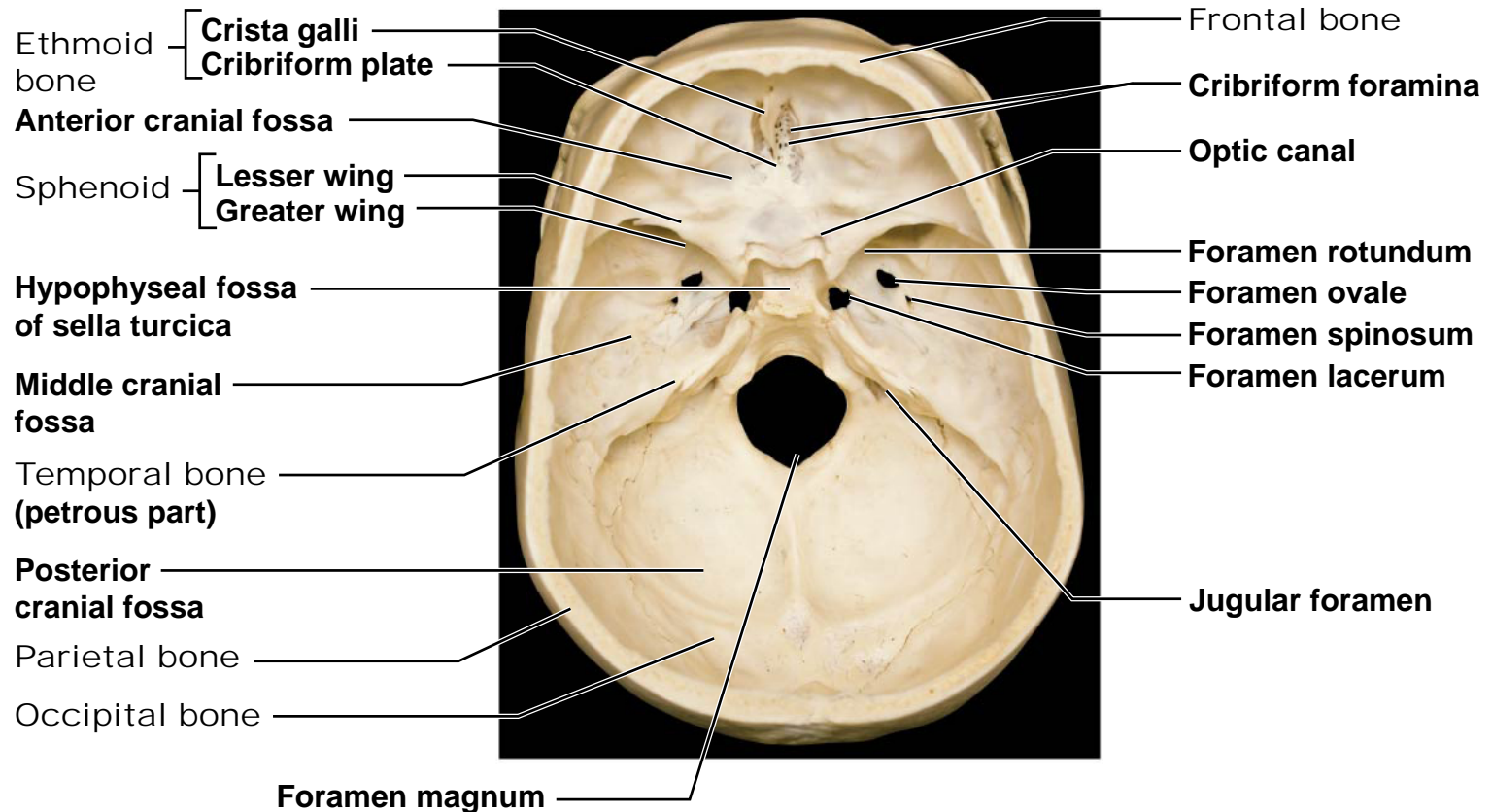
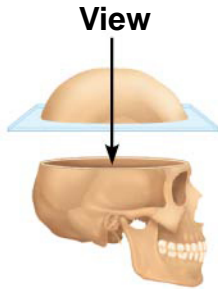
(b) Photo of superior view of the skull, calvaria removed

Figure 7.7a The base of the cranial cavity.



(a) Superior view of the skull, calvaria removed

Figure 7.7b The base of the cranial cavity.



(b) Photo of superior view of the skull, calvaria removed

Figure 7.8 The temporal bone.

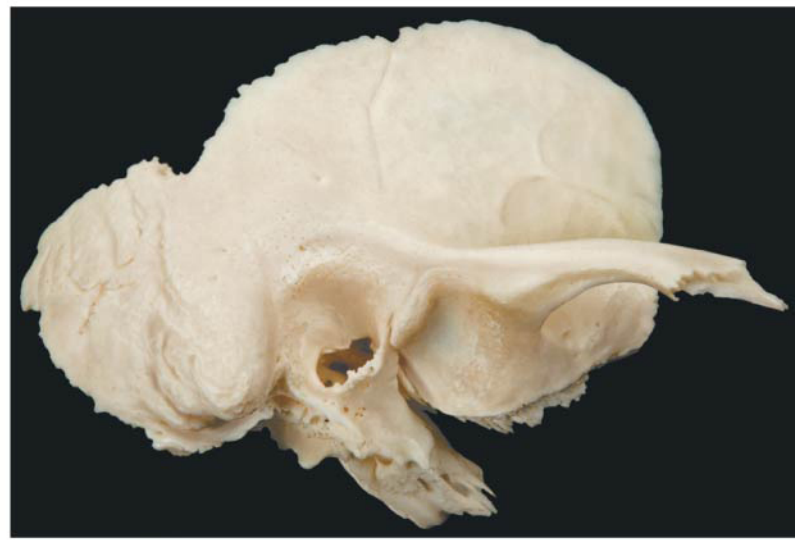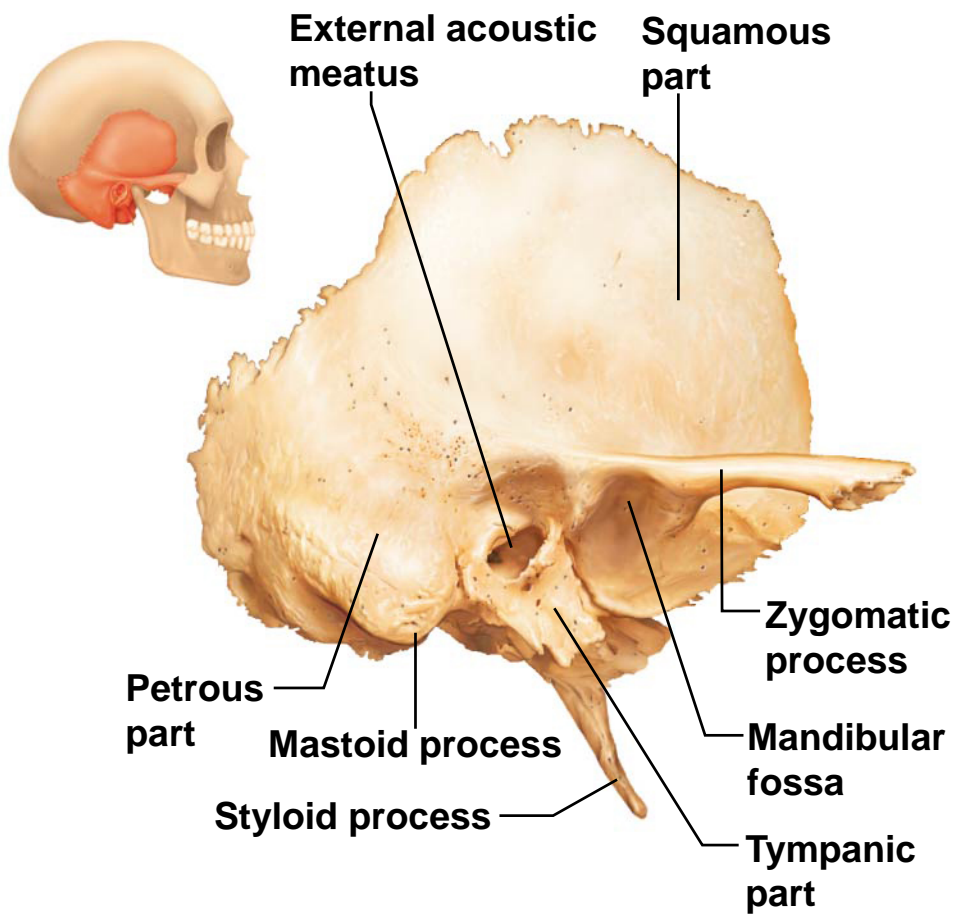
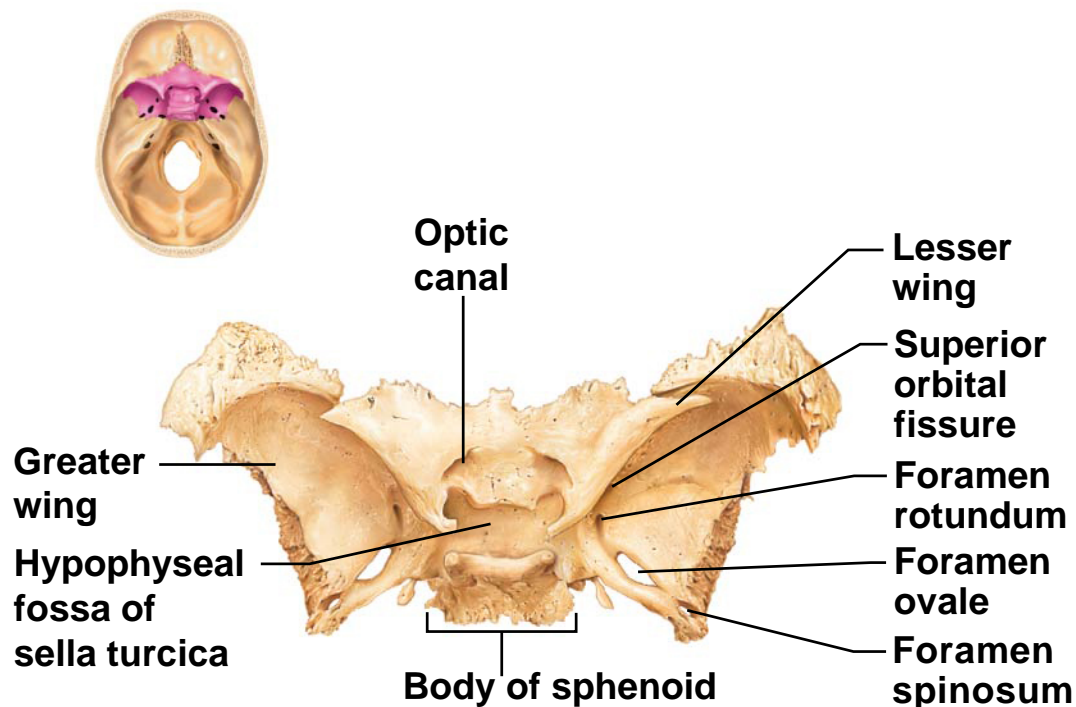
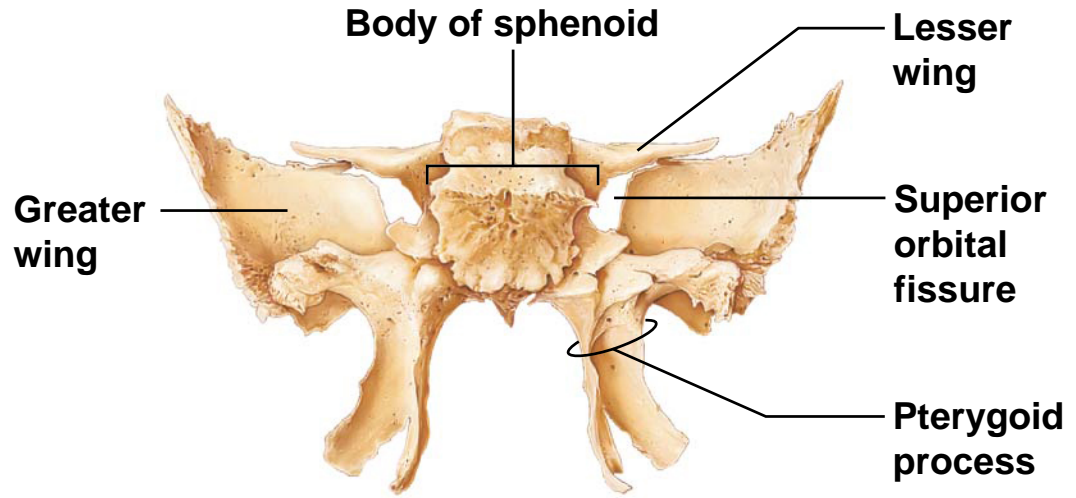

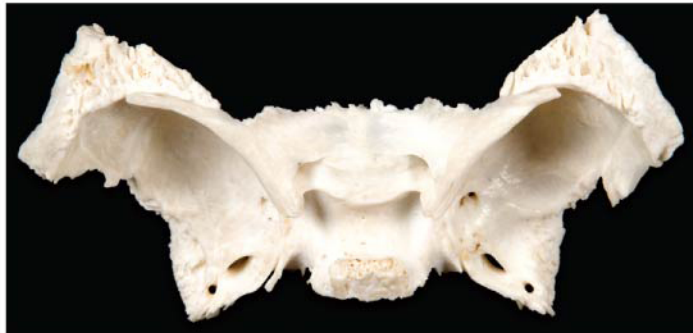
Figure 7.9 The sphenoid bone.



(a) Superior view



(b) Posterior view

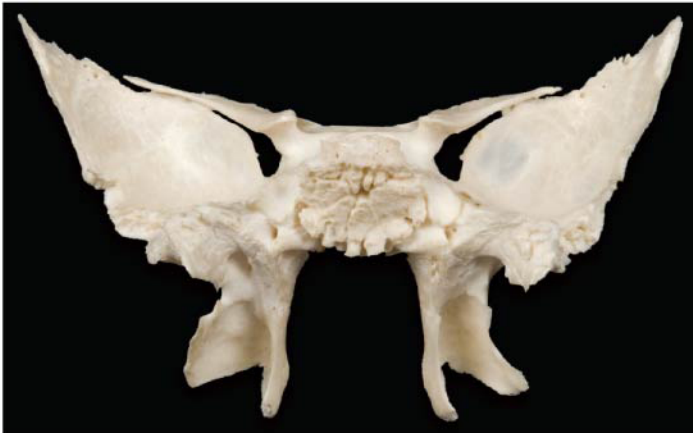

Figure 7.9a The sphenoid bone.

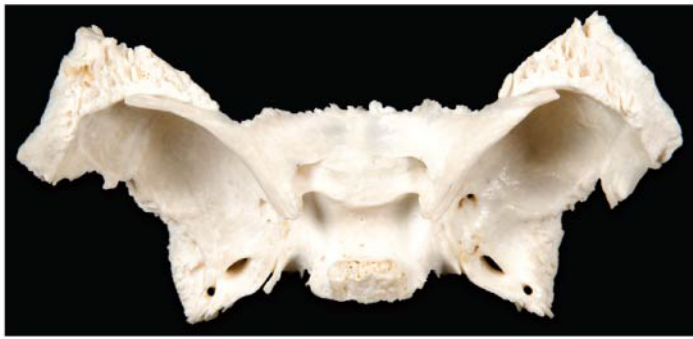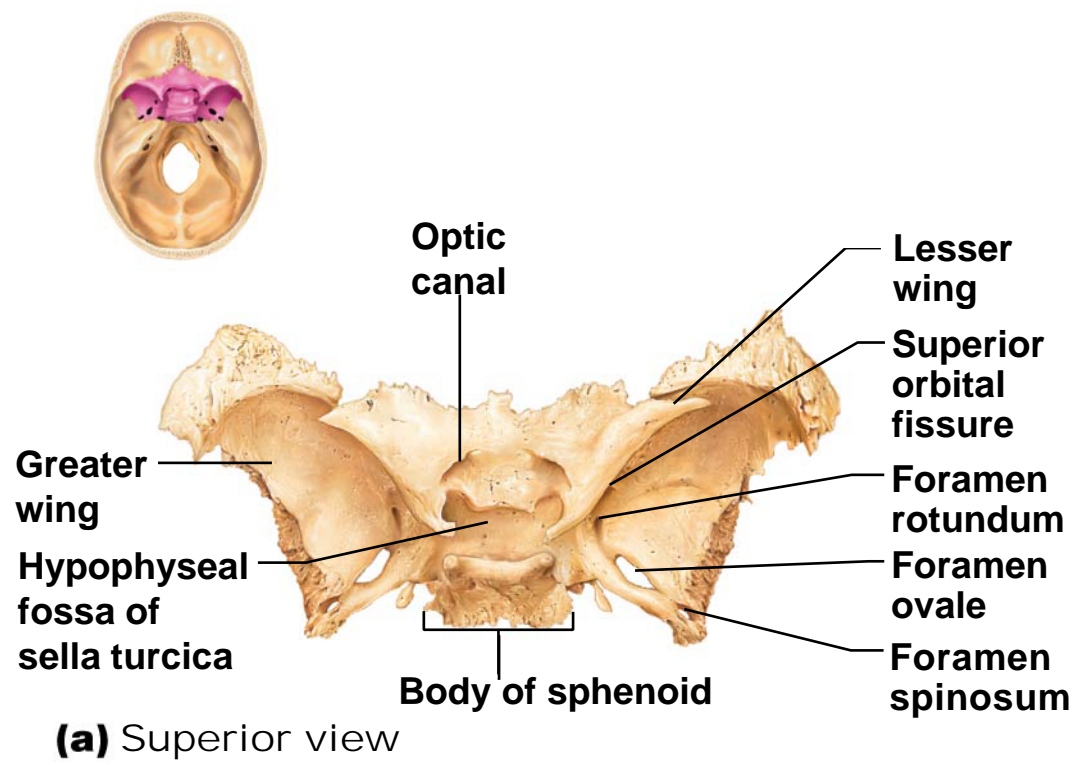


Figure 7.9b The sphenoid bone.

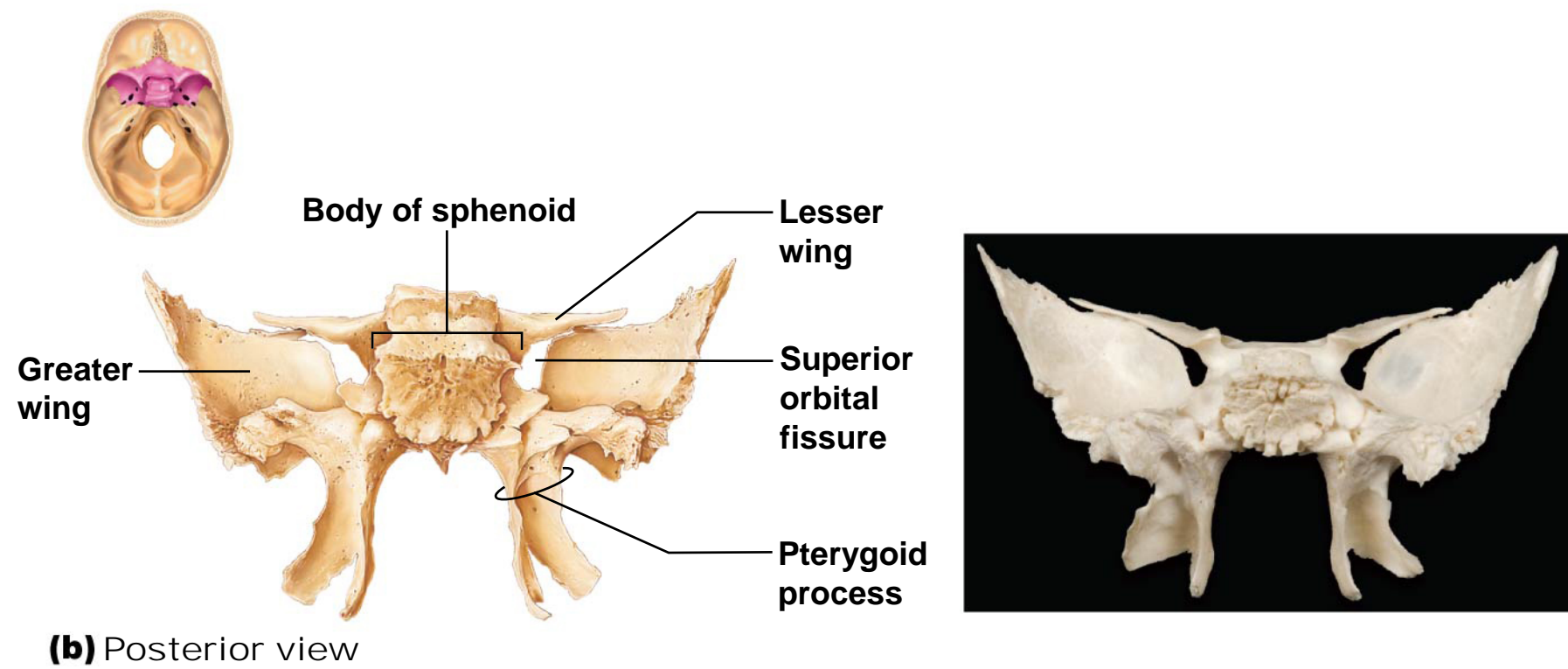




Figure 7.10 The ethmoid bone.

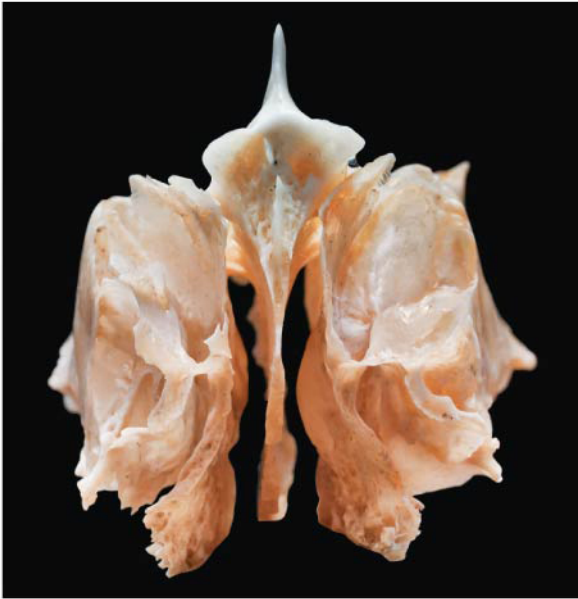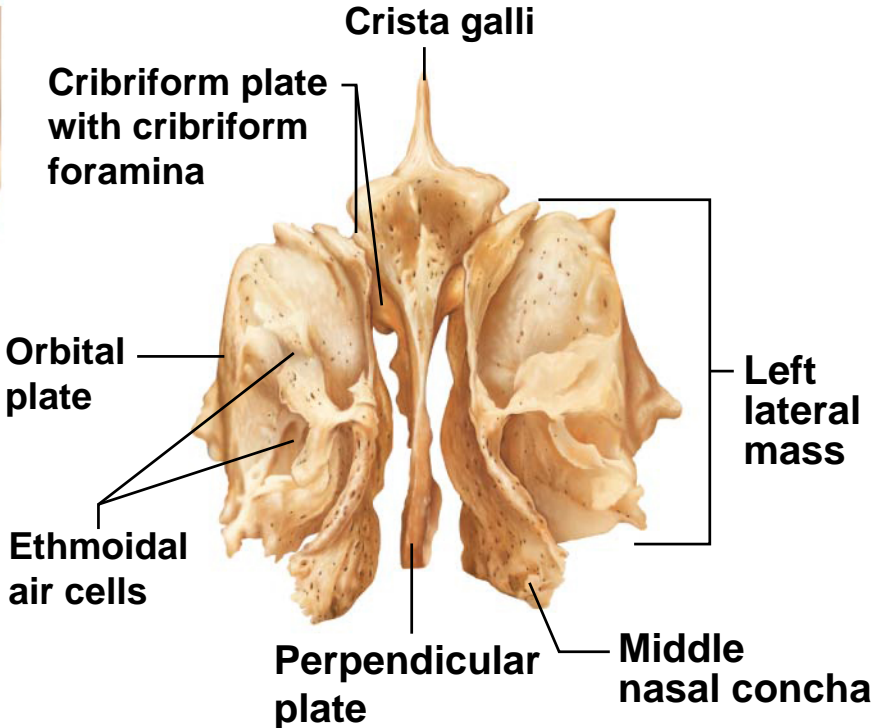
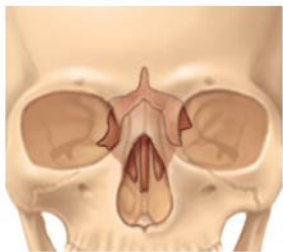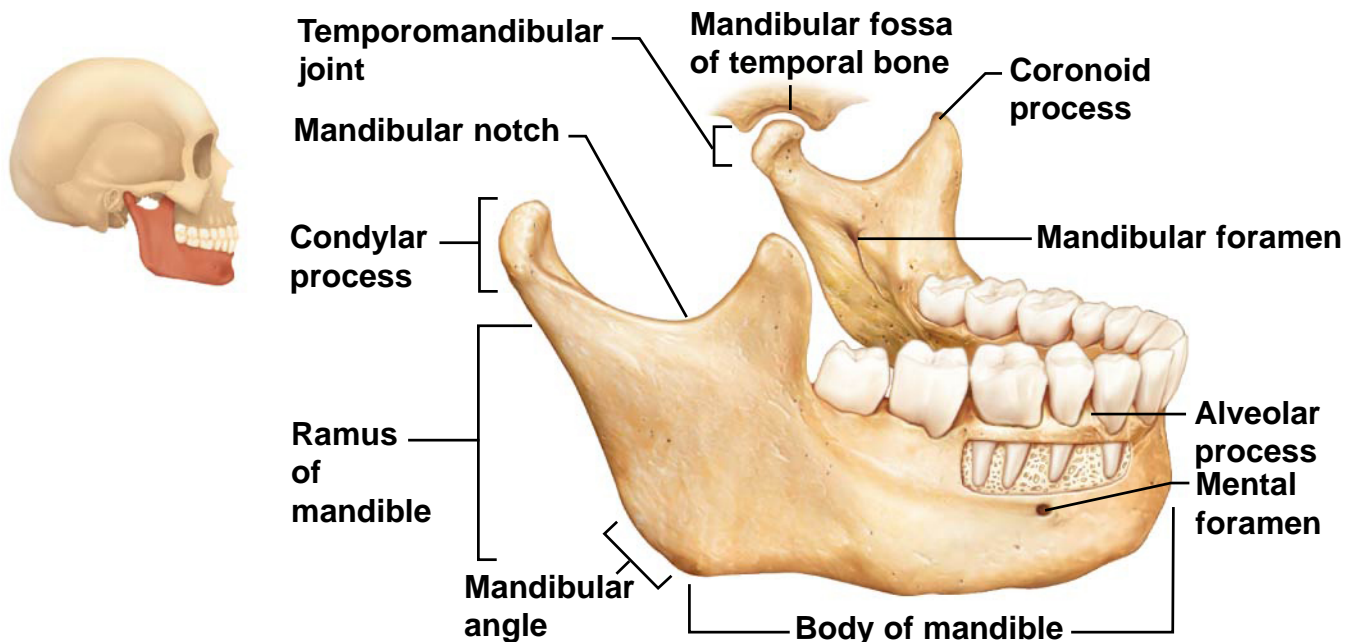
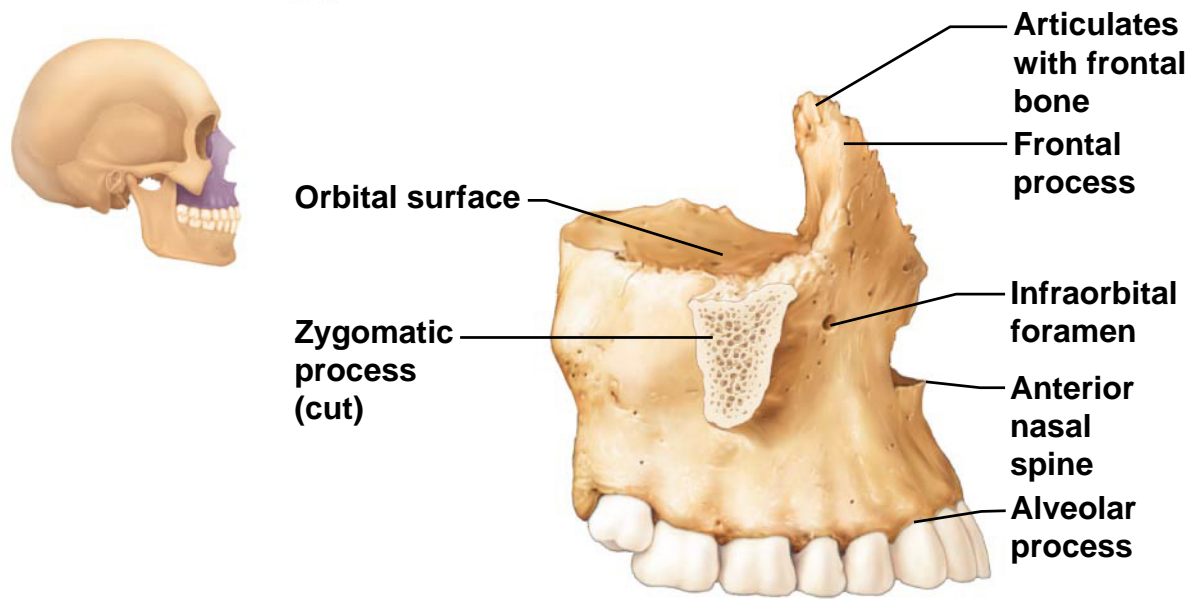


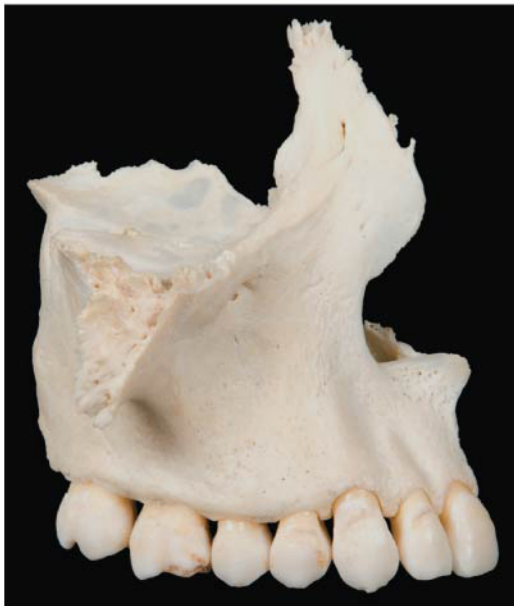Figure 7.11 Detailed anatomy of the mandible and the maxilla.



(a) Mandible, right lateral view

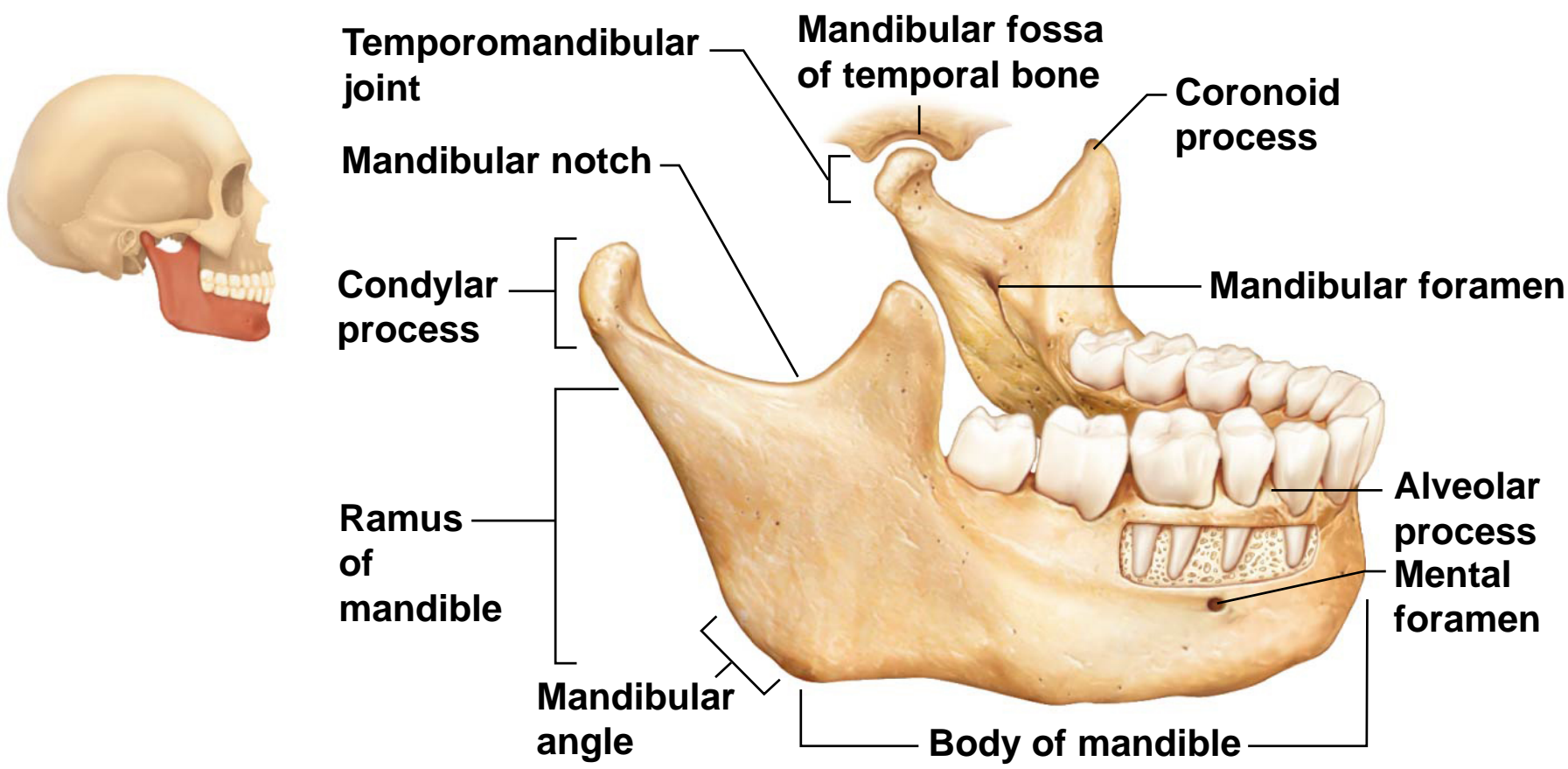


(b) Maxilla, right lateral view

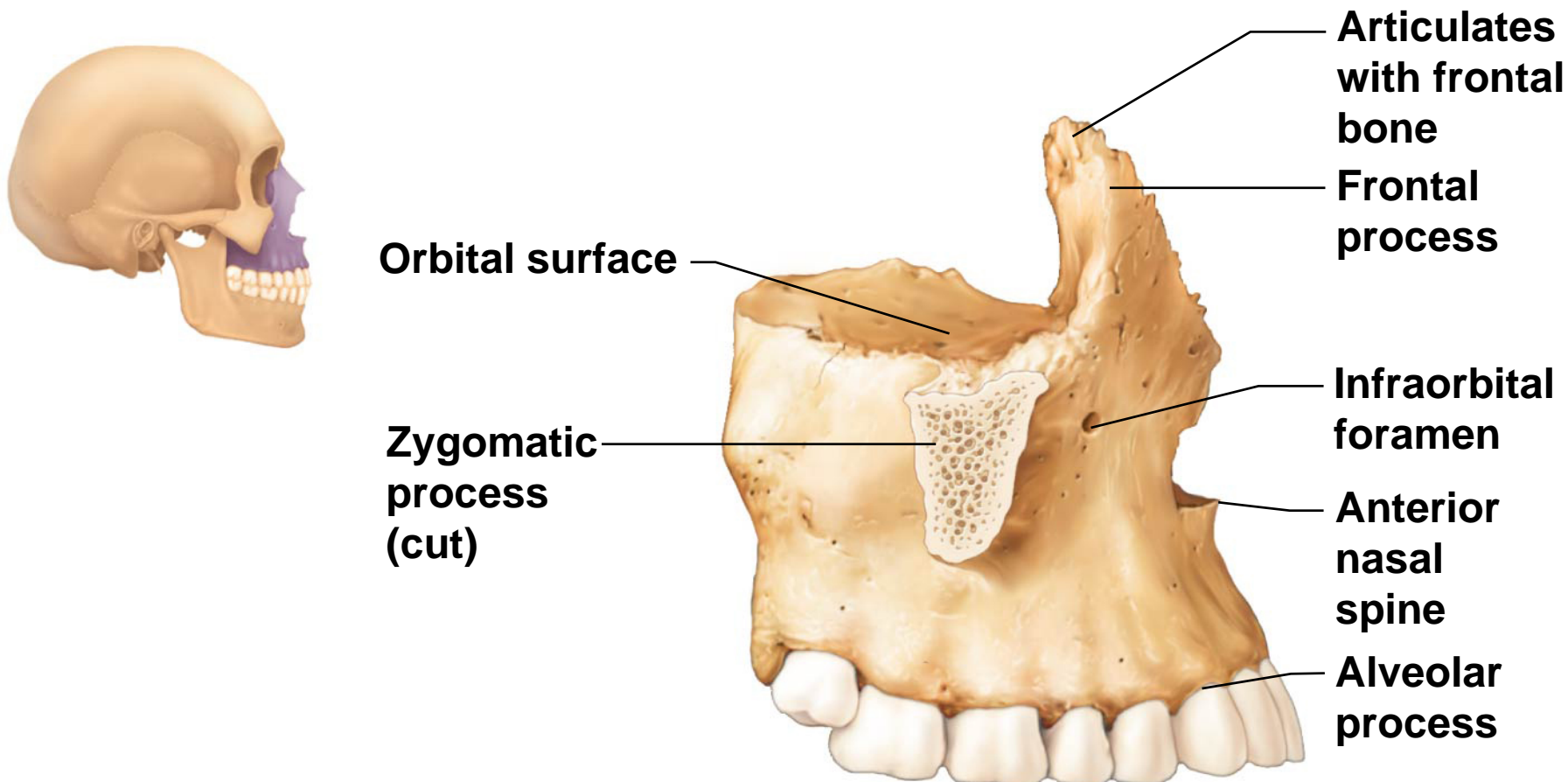


(c) Maxilla, photo of right lateral view

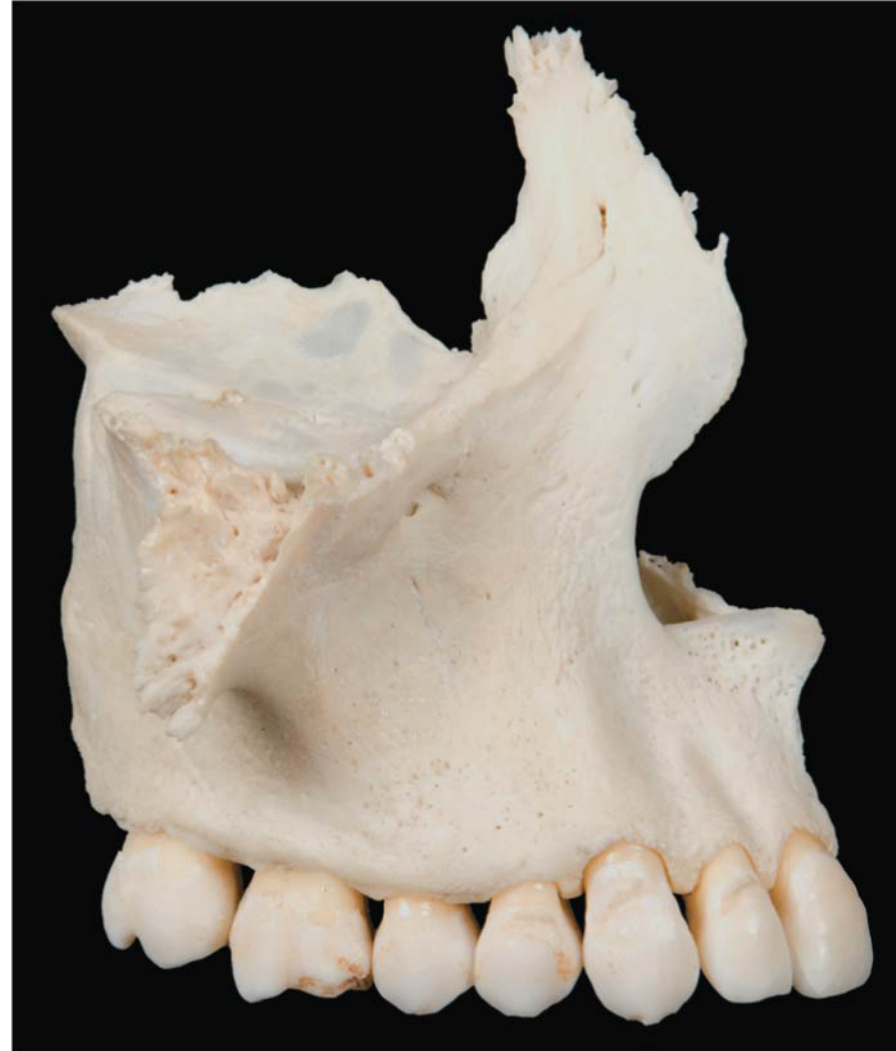Figure 7.11a Detailed anatomy of the mandible and the maxilla.



**(a)** Mandible, right lateral view



**(b)** Maxilla, right lateral view



**(c)** Maxilla, photo of right lateral view

Figure 7.12 The hyoid bone.

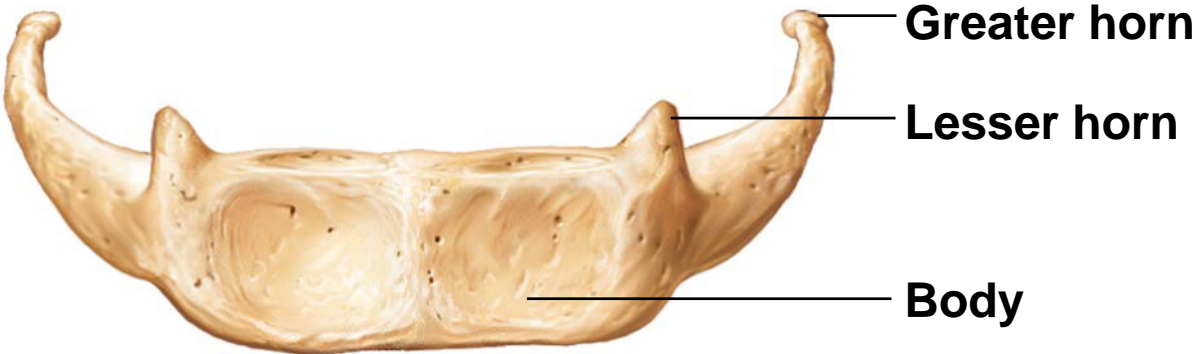
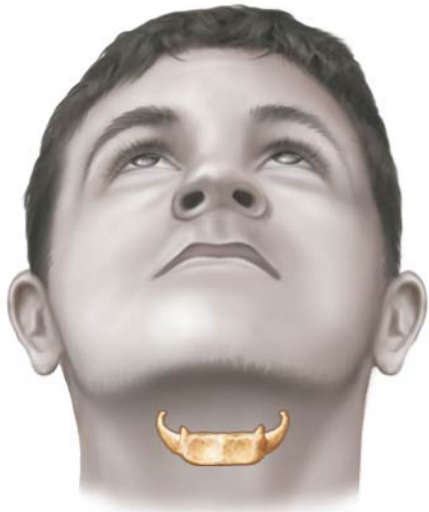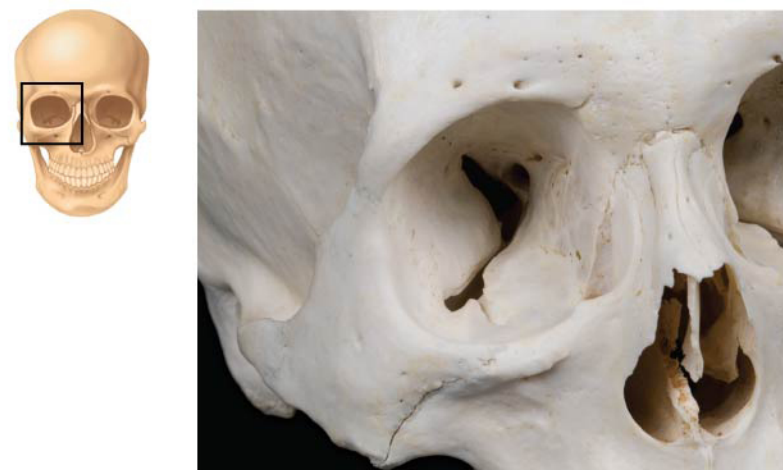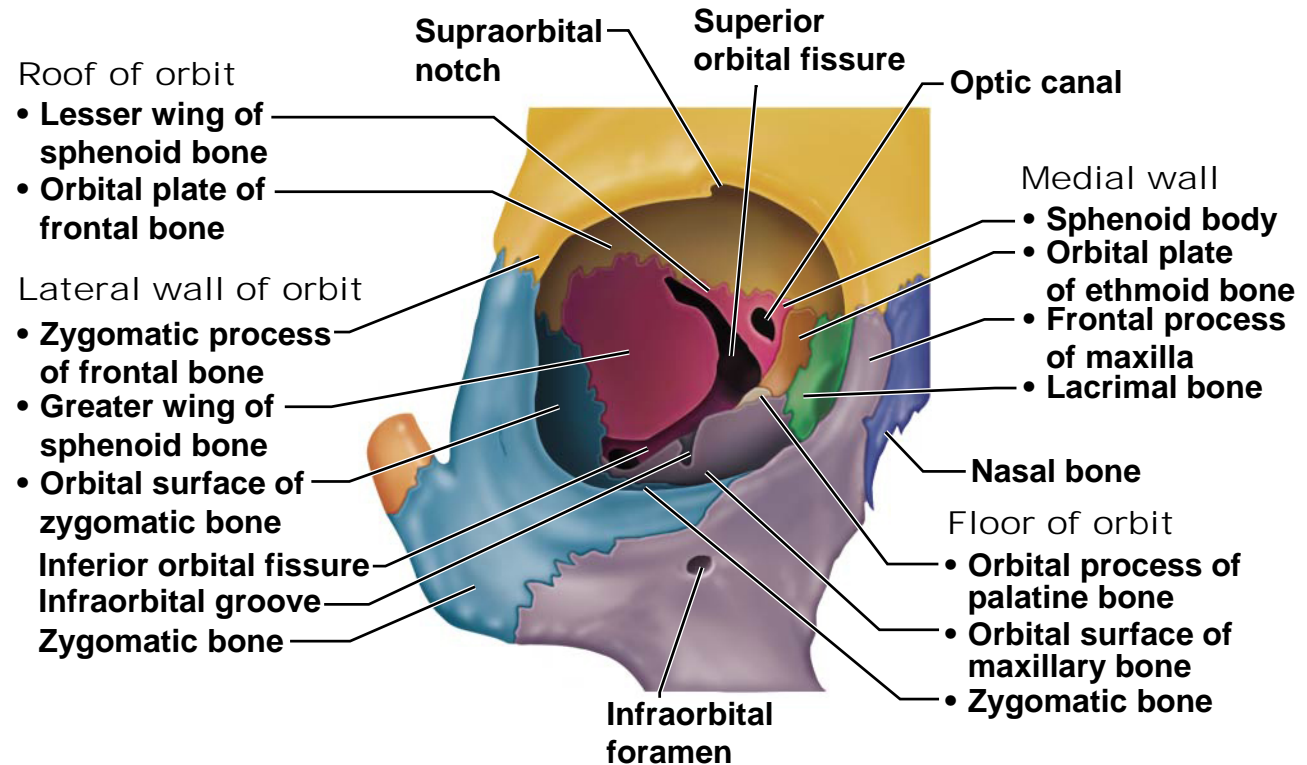


Figure 7.13 Bones that form the orbits.

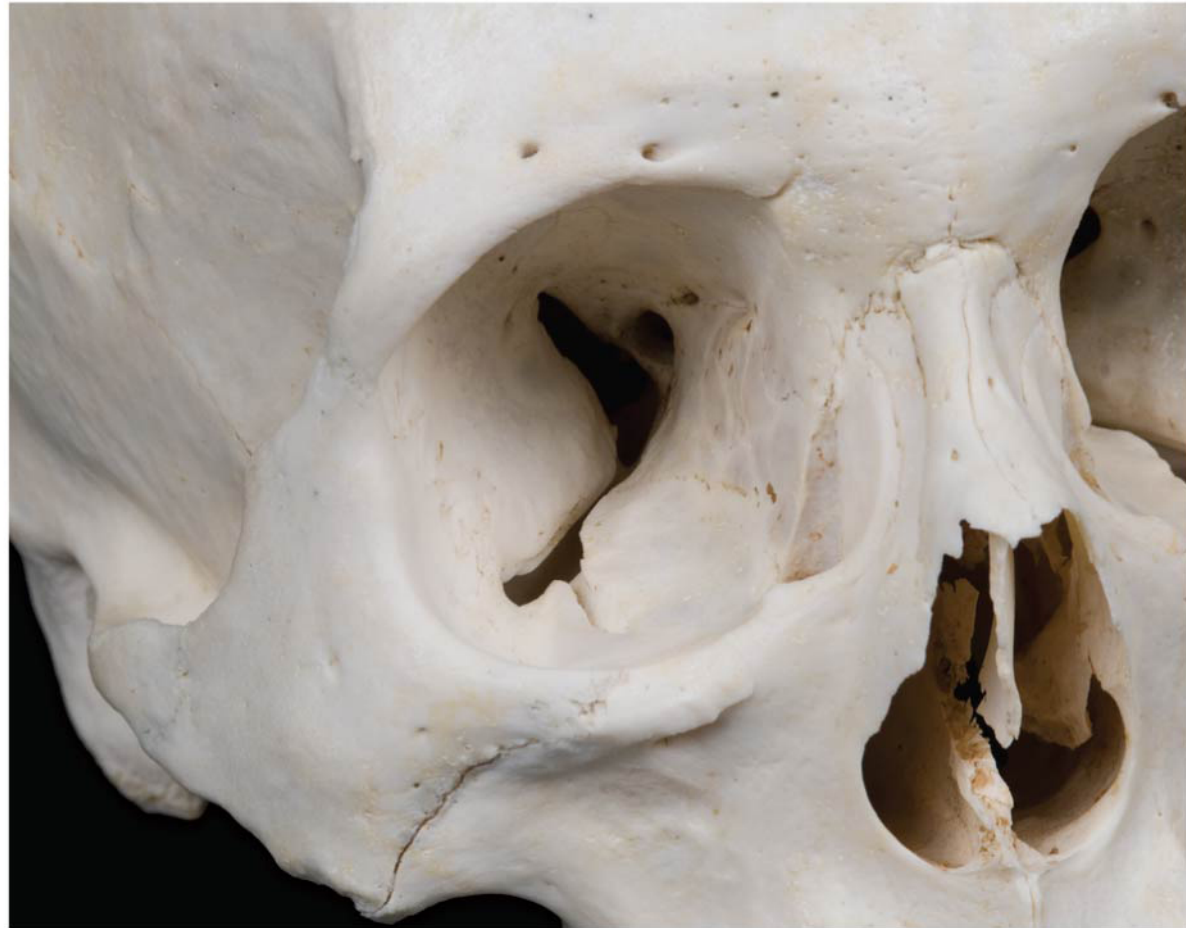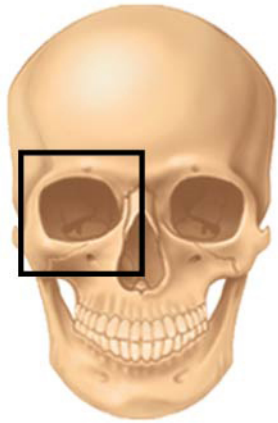


(a) Photograph, right orbit



(b) Contribution of each of the seven bones forming the right orbit

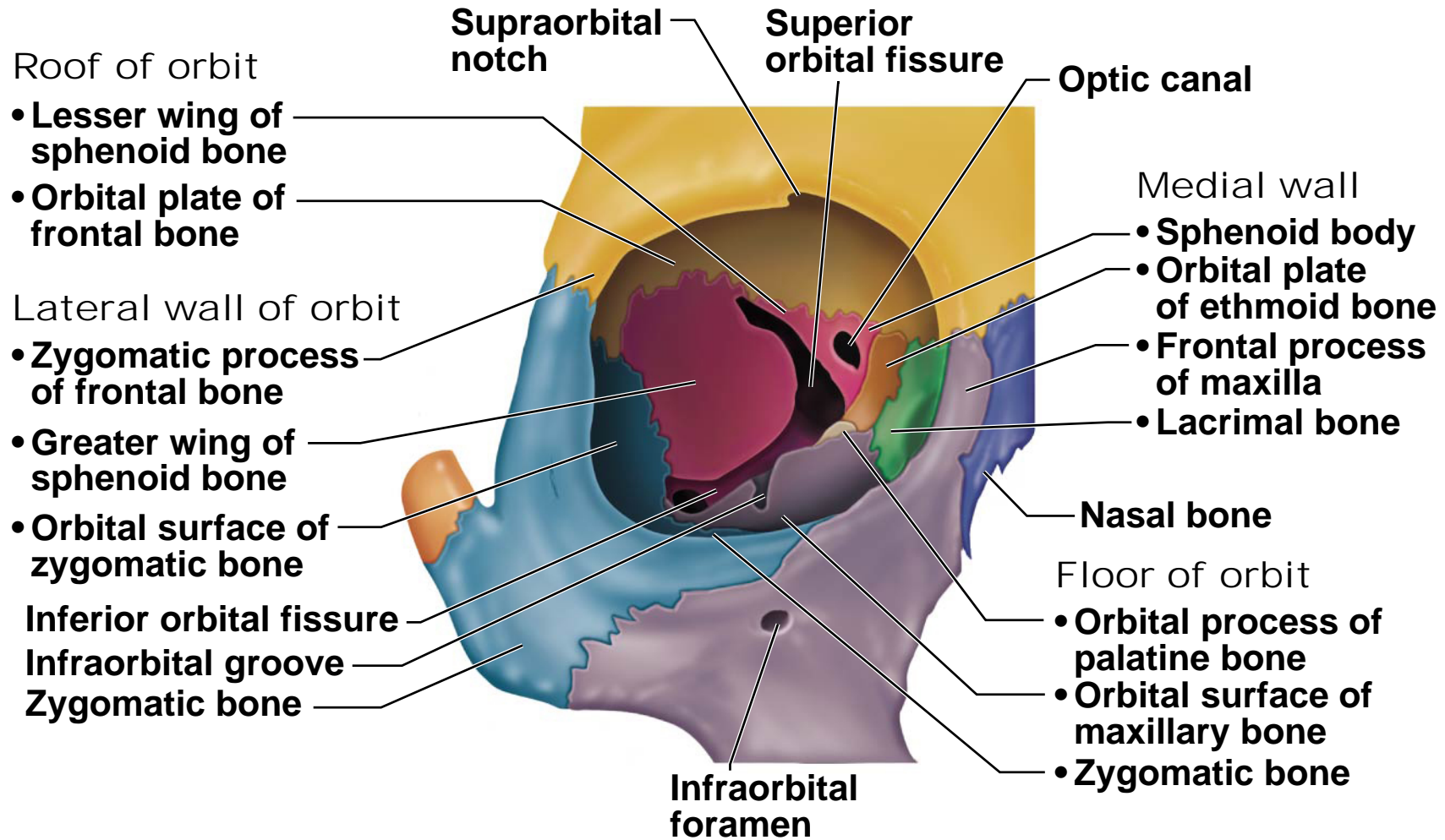
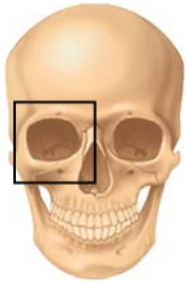
Figure 7.13a Bones that form the orbits.



**(a)** Photograph, right orbit

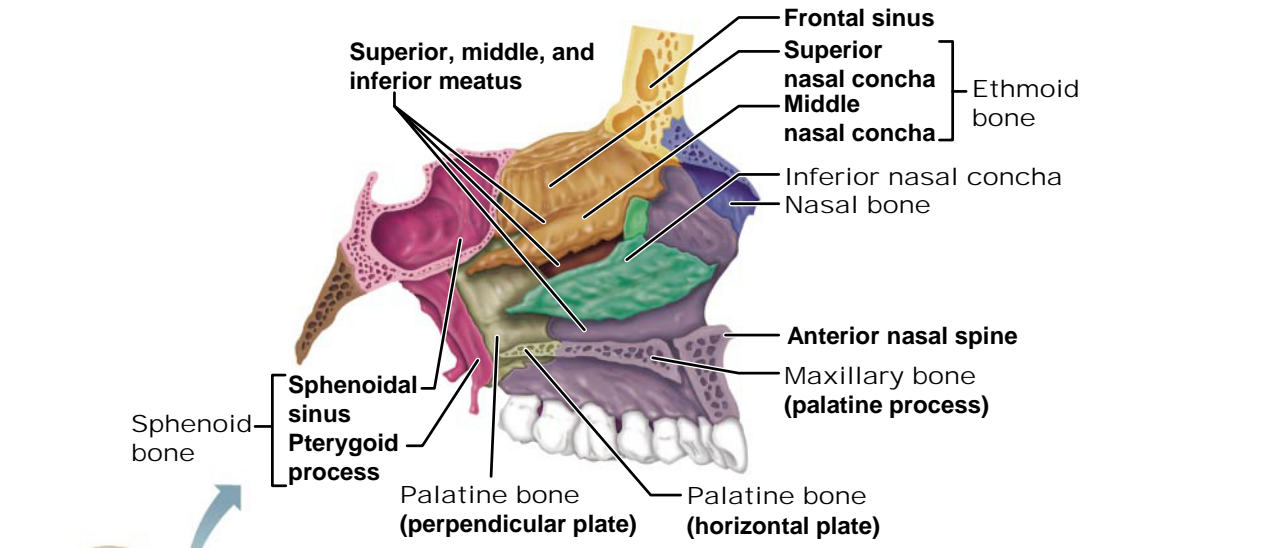


Figure 7.13b Bones that form the orbits.

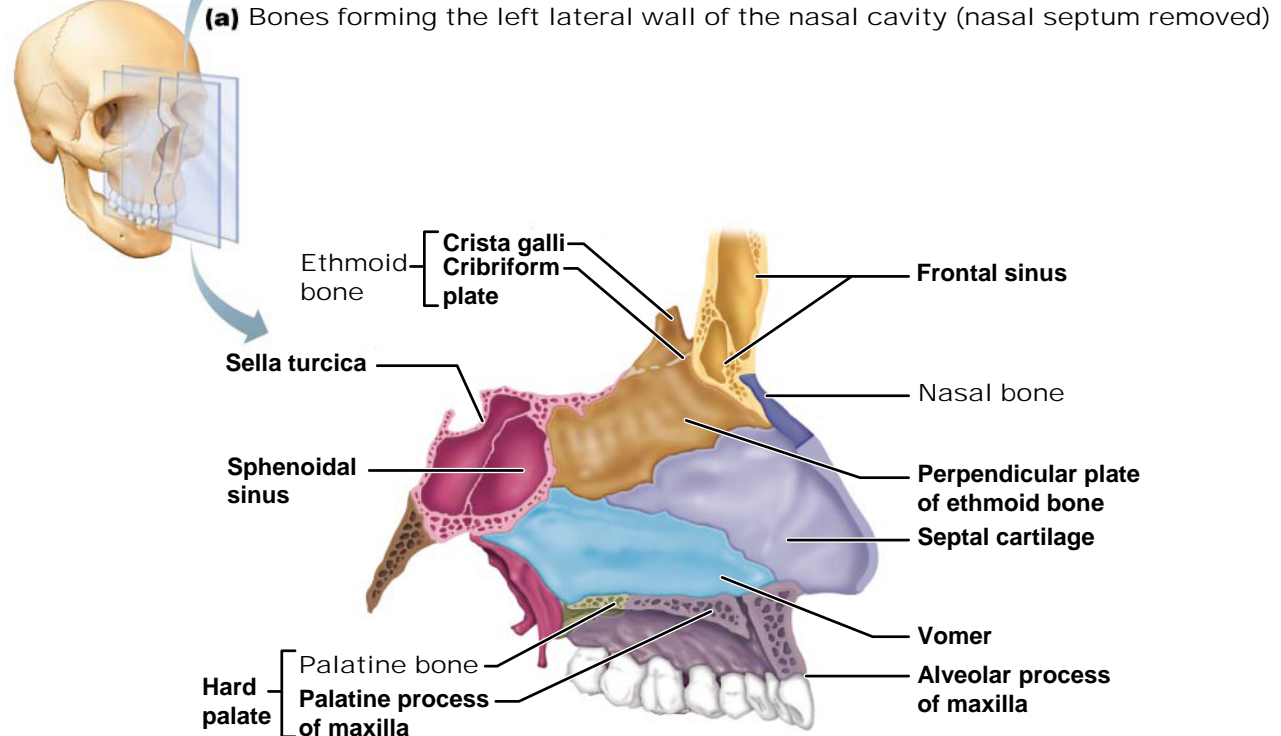


**(b)** Contribution of each of the seven bones forming the right orbit

Figure 7.14 Bones of the nasal cavity.



(a) Bones forming the left lateral wall of the nasal cavity (nasal septum removed)



(b) Nasal cavity with septum in place showing the contributions of the ethmoid bone, the vomer, and septal cartilage

Figure 7.14a Bones of the nasal cavity.

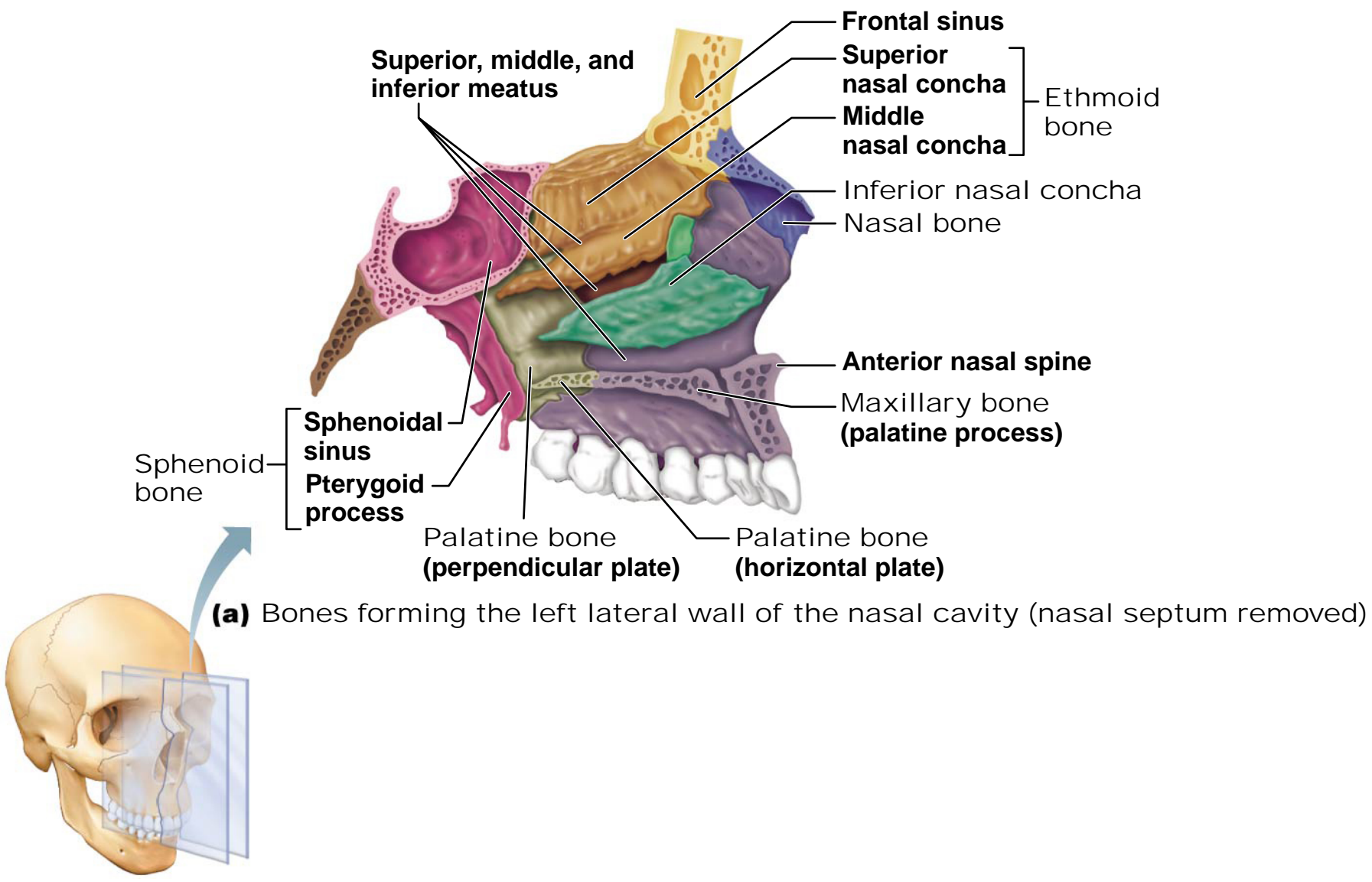
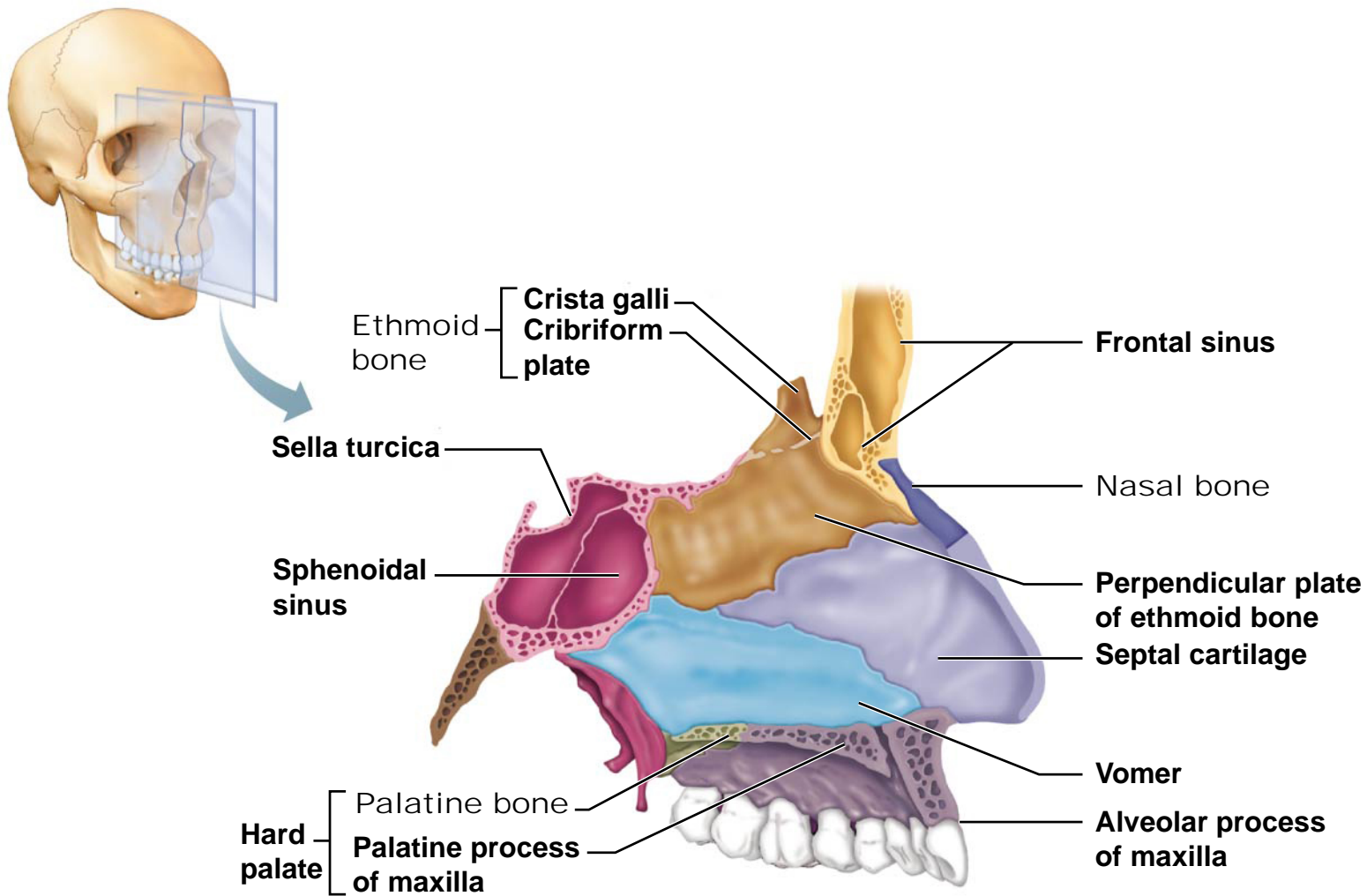
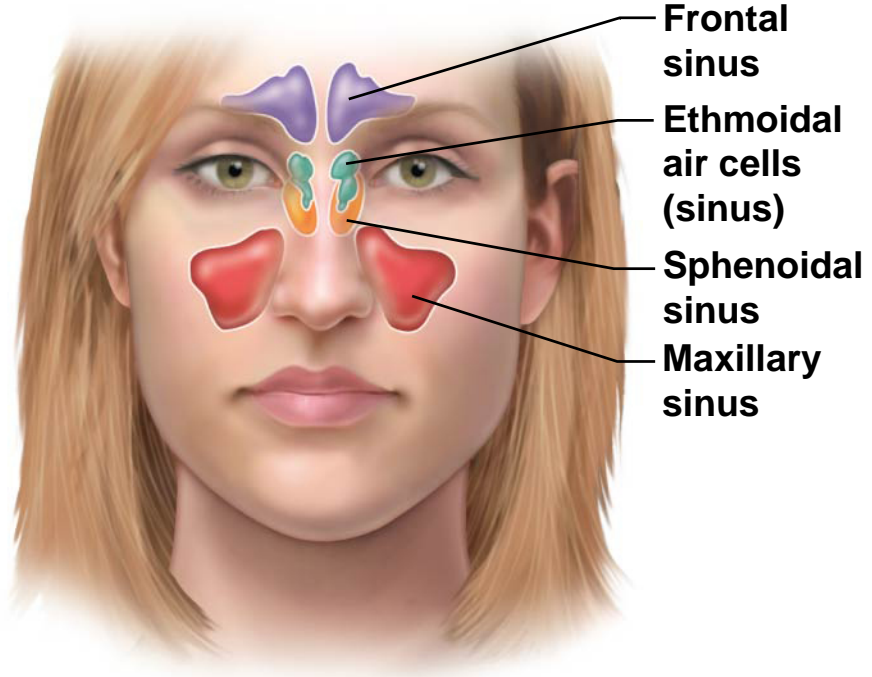


Figure 7.14b Bones of the nasal cavity.

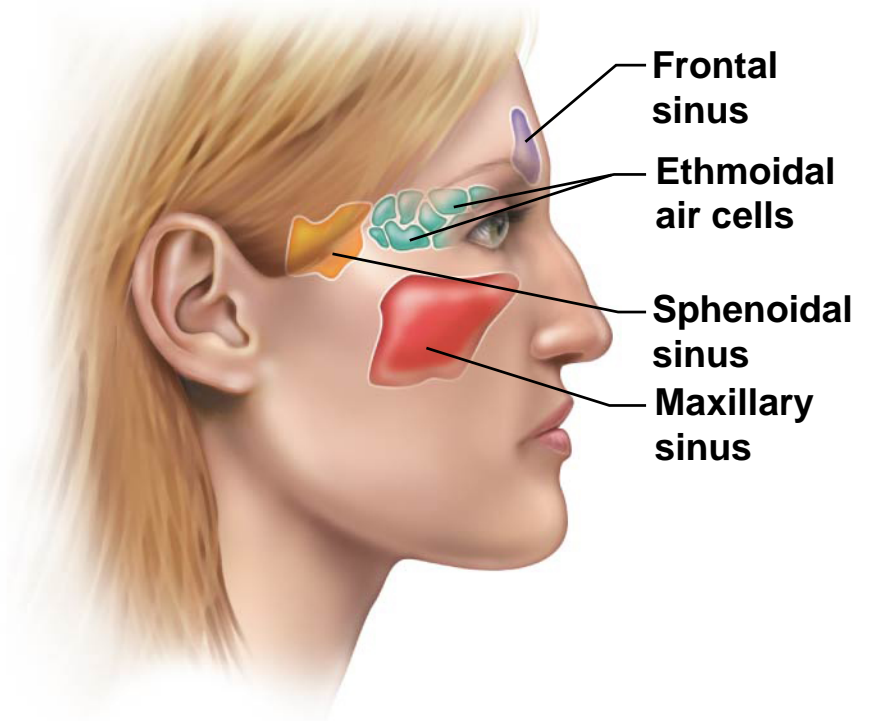


**(b)** Nasal cavity with septum in place showing the contributions of the ethmoid bone, the vomer, and septal cartilage

Figure 7.15 Paranasal sinuses.

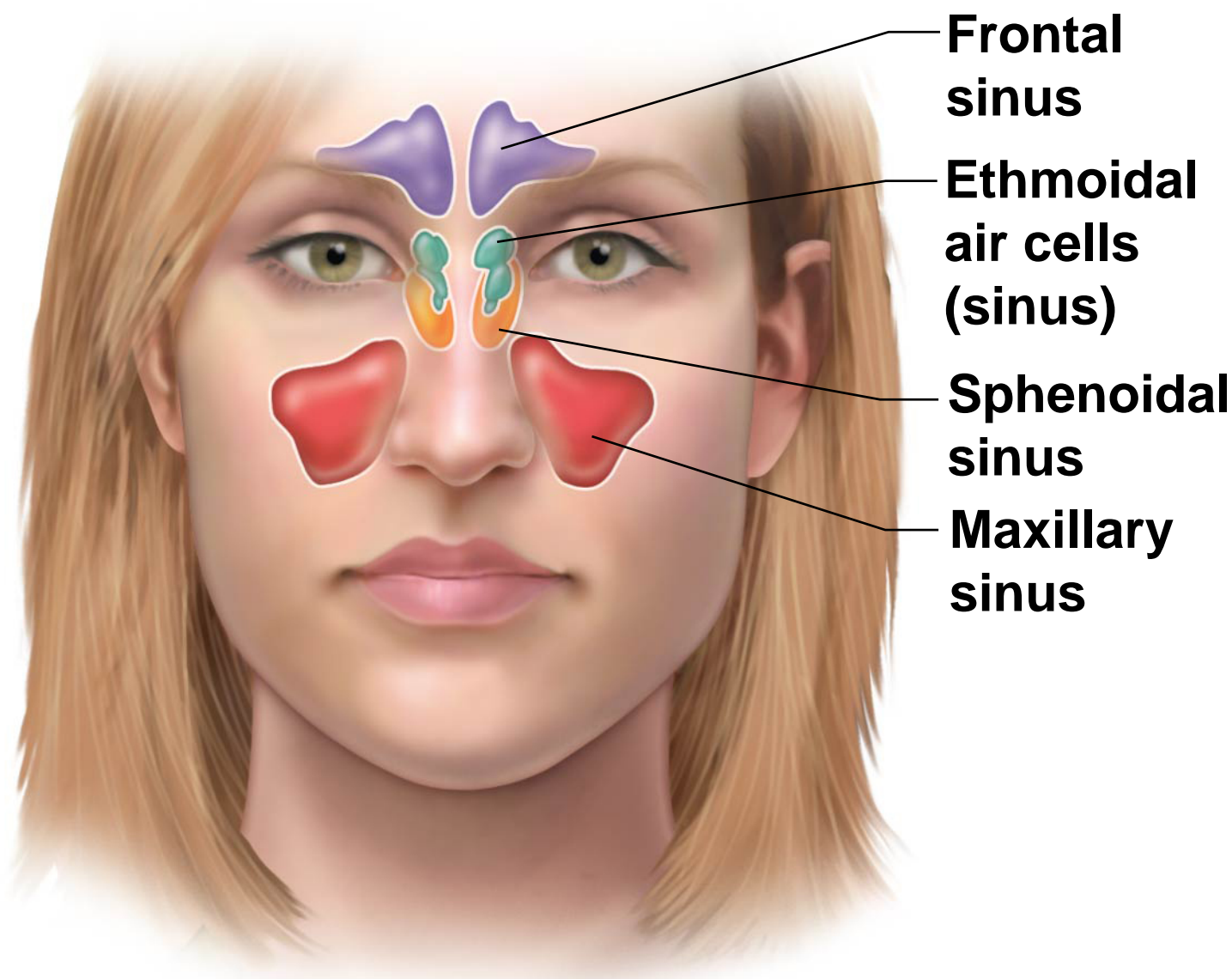


**(a)** Anterior aspect



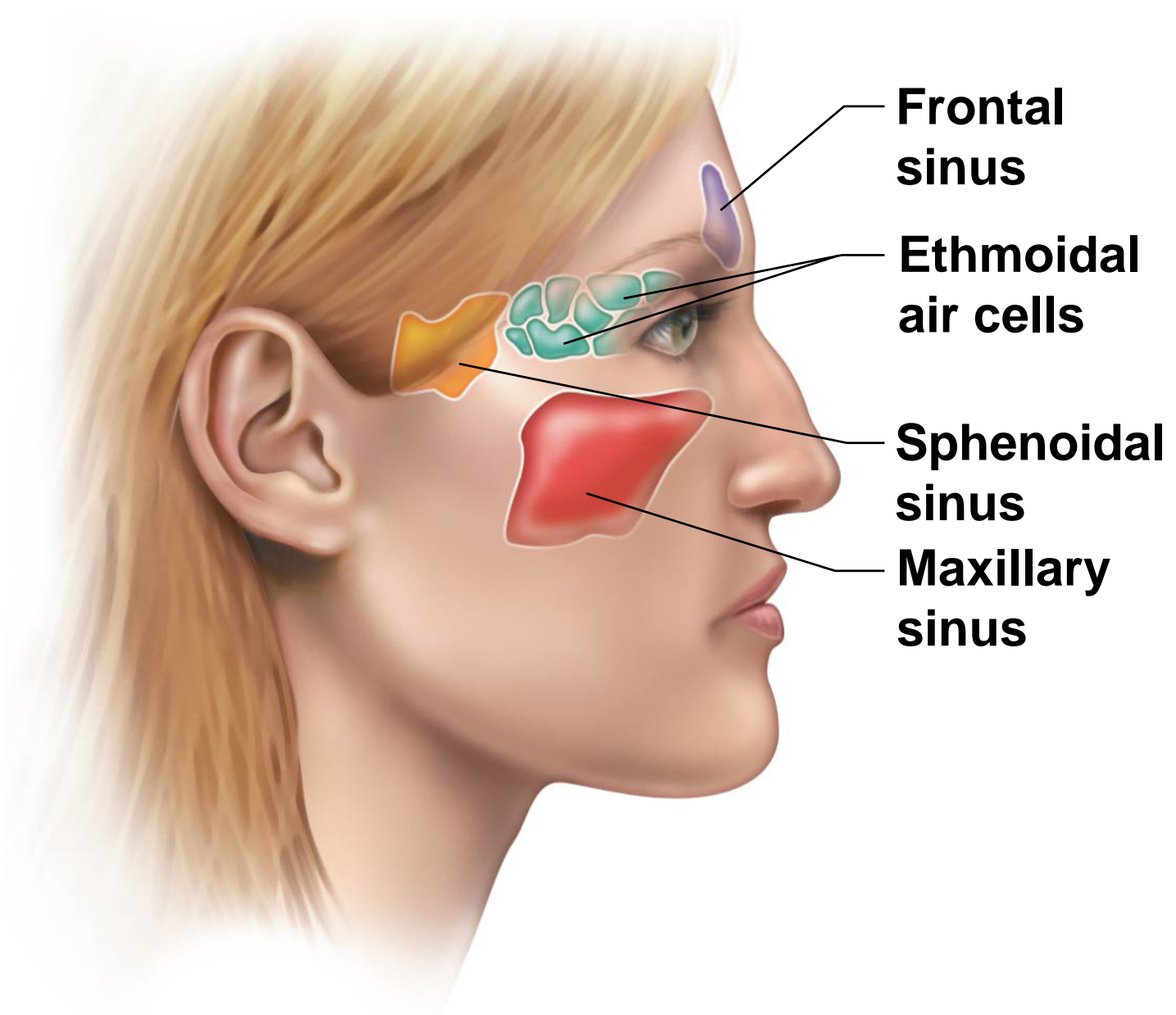
**(b)** Medial aspect

Figure 7.15a Paranasal sinuses.



**(a)** Anterior aspect

Figure 7.15b Paranasal sinuses.



**Frontal sinus**

**Ethmoidal air cells**

**Sphenoidal sinus**

**Maxillary sinus**

**(b)** Medial aspect

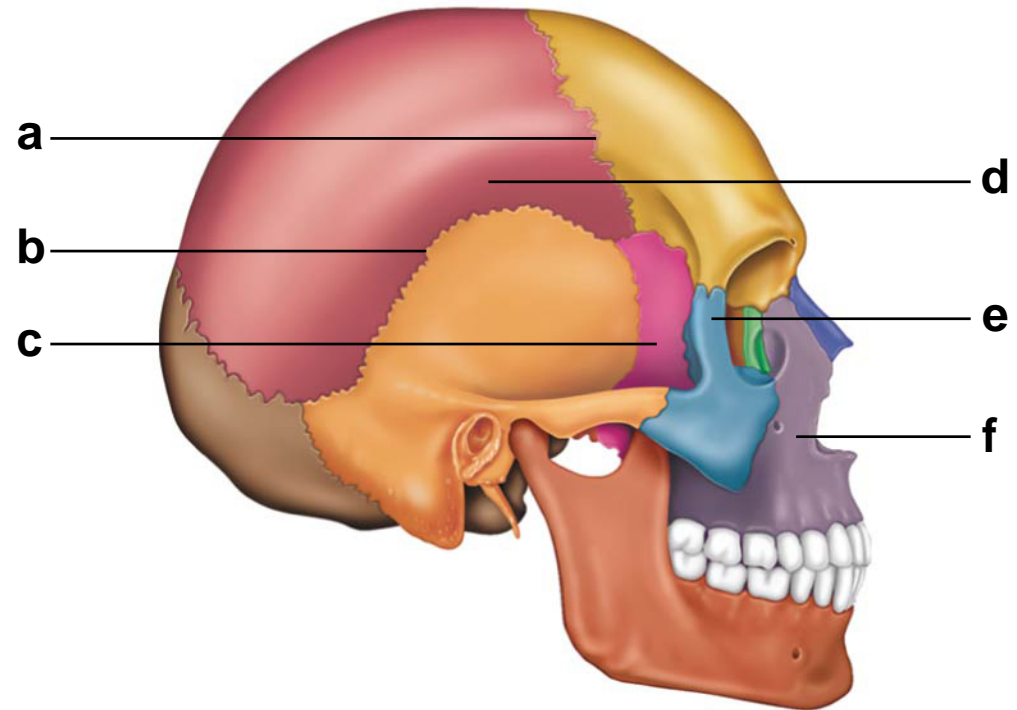
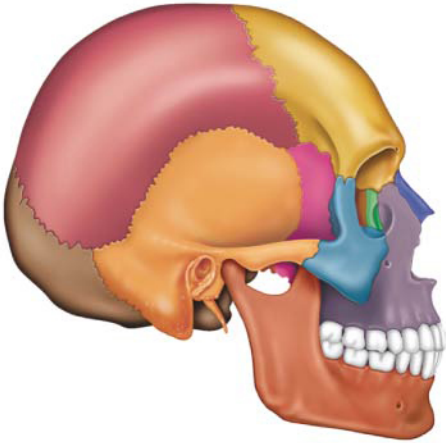





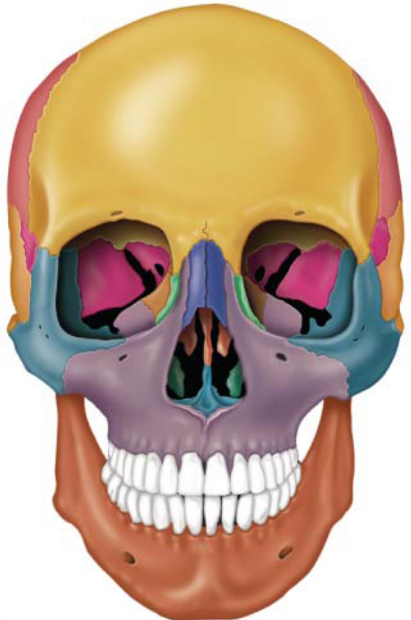
Table 7.1		Bones of the Skull	
VIEW OF SKULL	BONE WITH COMMENTS*	IMPORTANT MARKINGS	
 <p><i>Lateral view of skull (Figure 7.5)</i></p>	<p><b>Cranial bones</b></p>		
	<p><b>Frontal (1)</b> Forms forehead, superior part of orbits, and most of the anterior cranial fossa; contains sinuses</p>	<p><b>Supraorbital foramina (notches):</b> passageway for the supraorbital arteries and nerves</p>	
	<p><b>Parietal (2)</b> Form most of the superior and lateral aspects of the skull</p>	<p><b>Foramen magnum:</b> allows passage of the spinal cord from the brain stem to the vertebral canal</p> <p><b>Hypoglossal canals:</b> passageway for the hypoglossal nerve (cranial nerve XII)</p> <p><b>Occipital condyles:</b> articulate with the atlas (first vertebra)</p> <p><b>External occipital protuberance and nuchal lines:</b> sites of muscle attachment</p> <p><b>External occipital crest:</b> attachment site of ligamentum nuchae</p>	
<p><b>Occipital (1)</b> Forms posterior aspect and most of the base of the skull</p>			

\*The color code beside each bone name corresponds to the bone's color in the illustrations (see Figures 7.4 to 7.14). The number in parentheses ( ) following the bone name indicates the total number of such bones in the body.

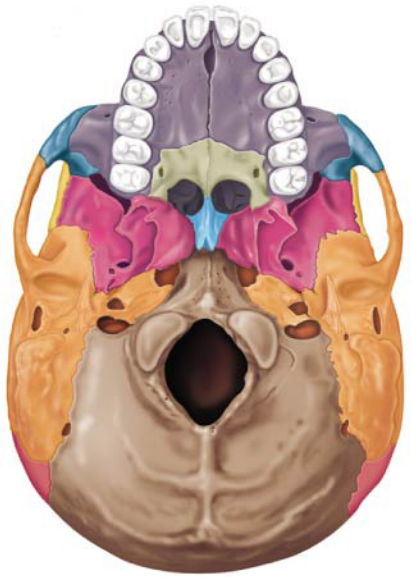


Table 7.1	Bones of the Skull (continued)	
VIEW OF SKULL	BONE WITH COMMENTS*	IMPORTANT MARKINGS
 <p data-bbox="384 992 843 1092"><i>Superior view of skull, calvaria removed (Figure 7.7)</i></p>	<p data-bbox="879 342 1082 371"><b>Cranial bones</b></p> <p data-bbox="879 392 1210 685"> <span style="color: #e91e63;">■</span> <b>Sphenoid (1)</b>            Keystone of the cranium; contributes to the middle cranial fossa and orbits; main parts are the body, greater wings, lesser wings, and pterygoid processes         </p> <p data-bbox="879 799 1210 1092"> <span style="color: #8d6e33;">■</span> <b>Ethmoid (1)</b>            Small contribution to the anterior cranial fossa; forms part of the nasal septum and the lateral walls and roof of the nasal cavity; contributes to the medial wall of the orbit         </p>	<p data-bbox="1261 392 2140 428"><b>Sella turcica:</b> hypophyseal fossa portion is the seat of the pituitary gland</p> <p data-bbox="1261 442 2140 478"><b>Optic canals:</b> passageway for cranial nerve II and the ophthalmic arteries</p> <p data-bbox="1261 492 2140 556"><b>Superior orbital fissures:</b> passageway for cranial nerves III, IV, VI, part of V (ophthalmic division), and ophthalmic vein</p> <p data-bbox="1261 571 2140 635"><b>Foramen rotundum (2):</b> passageway for the maxillary division of cranial nerve V</p> <p data-bbox="1261 649 2140 714"><b>Foramen ovale (2):</b> passageway for the mandibular division of cranial nerve V</p> <p data-bbox="1261 728 2140 763"><b>Foramen spinosum (2):</b> passageway for the middle meningeal artery</p> <p data-bbox="1261 799 2140 863"><b>Crista galli:</b> attachment point for the falx cerebri, a dural membrane fold</p> <p data-bbox="1261 878 2140 942"><b>Cribriform plates:</b> passageways for filaments of the olfactory nerves (cranial nerve I)</p> <p data-bbox="1261 956 2140 1021"><b>Superior and middle nasal conchae:</b> form part of lateral walls of nasal cavity; increase turbulence of air flow</p>

\*The color code beside each bone name corresponds to the bone's color in the illustrations (see Figures 7.4 to 7.14). The number in parentheses ( ) following the bone name indicates the total number of such bones in the body.

Table 7.1	Bones of the Skull (continued)	
VIEW OF SKULL	BONE WITH COMMENTS*	IMPORTANT MARKINGS
 <p data-bbox="402 968 675 1028"><i>Anterior view of skull (Figure 7.4)</i></p>	<p data-bbox="861 292 1031 321"><b>Facial bones</b></p> <ul style="list-style-type: none"> <li data-bbox="861 339 1210 435"> <span style="color: blue;">■</span> <b>Nasal (2)</b> Form the bridge of the nose         </li> <li data-bbox="861 454 1210 549"> <span style="color: green;">■</span> <b>Lacrimal (2)</b> Form part of the medial orbit wall         </li> <li data-bbox="861 568 1210 664"> <span style="color: blue;">■</span> <b>Zygomatic (2)</b> Form the cheek and part of the orbit         </li> <li data-bbox="861 682 1210 778"> <span style="color: green;">■</span> <b>Inferior nasal concha (2)</b> Form part of the lateral walls of the nasal cavity         </li> <li data-bbox="861 796 1082 863"> <span style="color: orange;">■</span> <b>Mandible (1)</b> The lower jaw         </li> </ul>	<p data-bbox="1281 456 2127 521"><b>Lacrimal fossa:</b> houses the lacrimal sac, which helps to drain tears into the nasal cavity</p> <p data-bbox="1281 796 2051 828"><b>Coronoid processes:</b> insertion points for the temporalis muscles</p> <p data-bbox="1281 846 2102 911"><b>Condylar processes:</b> articulate with the temporal bones to form the jaw (temporomandibular) joints</p> <p data-bbox="1281 929 2114 961"><b>Mandibular symphysis:</b> medial fusion point of the mandibular bones</p> <p data-bbox="1281 979 1719 1011"><b>Dental alveoli:</b> sockets for the teeth</p> <p data-bbox="1281 1029 2076 1061"><b>Mandibular foramina:</b> passageway for the inferior alveolar nerves</p> <p data-bbox="1281 1079 2076 1139"><b>Mental foramina:</b> passageway for blood vessels and nerves to the chin and lower lip</p>

\*The color code beside each bone name corresponds to the bone's color in the illustrations (see Figures 7.4 to 7.14). The number in parentheses ( ) following the bone name indicates the total number of such bones in the body.

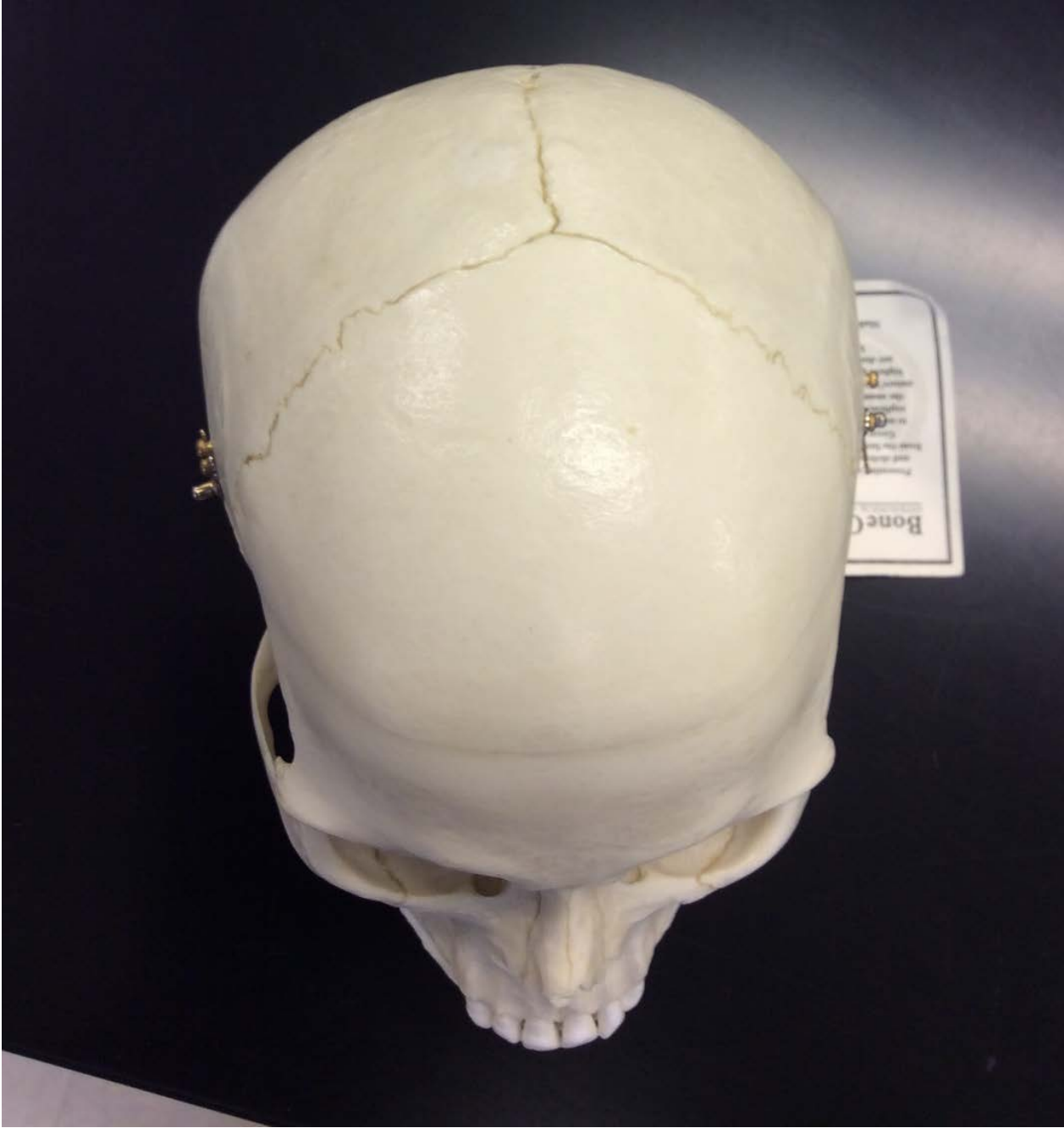
Table 7.1	Bones of the Skull (continued)	
VIEW OF SKULL	BONE WITH COMMENTS*	IMPORTANT MARKINGS
 <p data-bbox="402 835 810 892"><i>Inferior view of skull, mandible removed (Figure 7.6)</i></p>	<p data-bbox="871 192 1031 221"><b>Facial bones</b></p> <ul style="list-style-type: none"> <li data-bbox="871 235 1268 435"> <p><b>Maxilla (2)</b> Keystone bones of the face; form the upper jaw and parts of the hard palate, orbits, and nasal cavity walls</p> </li> <li data-bbox="871 685 1268 849"> <p><b>Palatine (2)</b> Form posterior part of the hard palate and a small part of nasal cavity and orbit walls</p> </li> <li data-bbox="871 863 1268 963"> <p><b>Vomer (1)</b> Inferior part of the nasal septum</p> </li> </ul> <p data-bbox="904 999 1268 1249"> <b>Auditory ossicles</b> (malleus, incus, and stapes) (2 each)  Found in middle ear cavity; involved in sound transmission (see Chapter 15)         </p>	<p data-bbox="1286 235 1668 264"><b>Dental alveoli:</b> sockets for teeth</p> <p data-bbox="1286 285 1911 314"><b>Zygomatic process:</b> helps form the zygomatic arches</p> <p data-bbox="1286 335 2089 392"><b>Palatine process:</b> forms the anterior hard palate; the two processes meet medially in the intermaxillary suture</p> <p data-bbox="1286 414 2025 442"><b>Frontal process:</b> forms part of lateral aspect of bridge of nose</p> <p data-bbox="1286 464 2076 521"><b>Incisive fossa and incisive canal:</b> passageway for blood vessels and nerves through anterior hard palate (fused palatine processes)</p> <p data-bbox="1286 542 2076 599"><b>Inferior orbital fissure:</b> passageway for maxillary branch of cranial nerve V, the zygomatic nerve, and blood vessels</p> <p data-bbox="1286 621 2038 678"><b>Infraorbital foramen:</b> passageway for infraorbital nerve to skin of face</p>

\*The color code beside each bone name corresponds to the bone's color in the illustrations (see Figures 7.4 to 7.14). The number in parentheses ( ) following the bone name indicates the total number of such bones in the body.

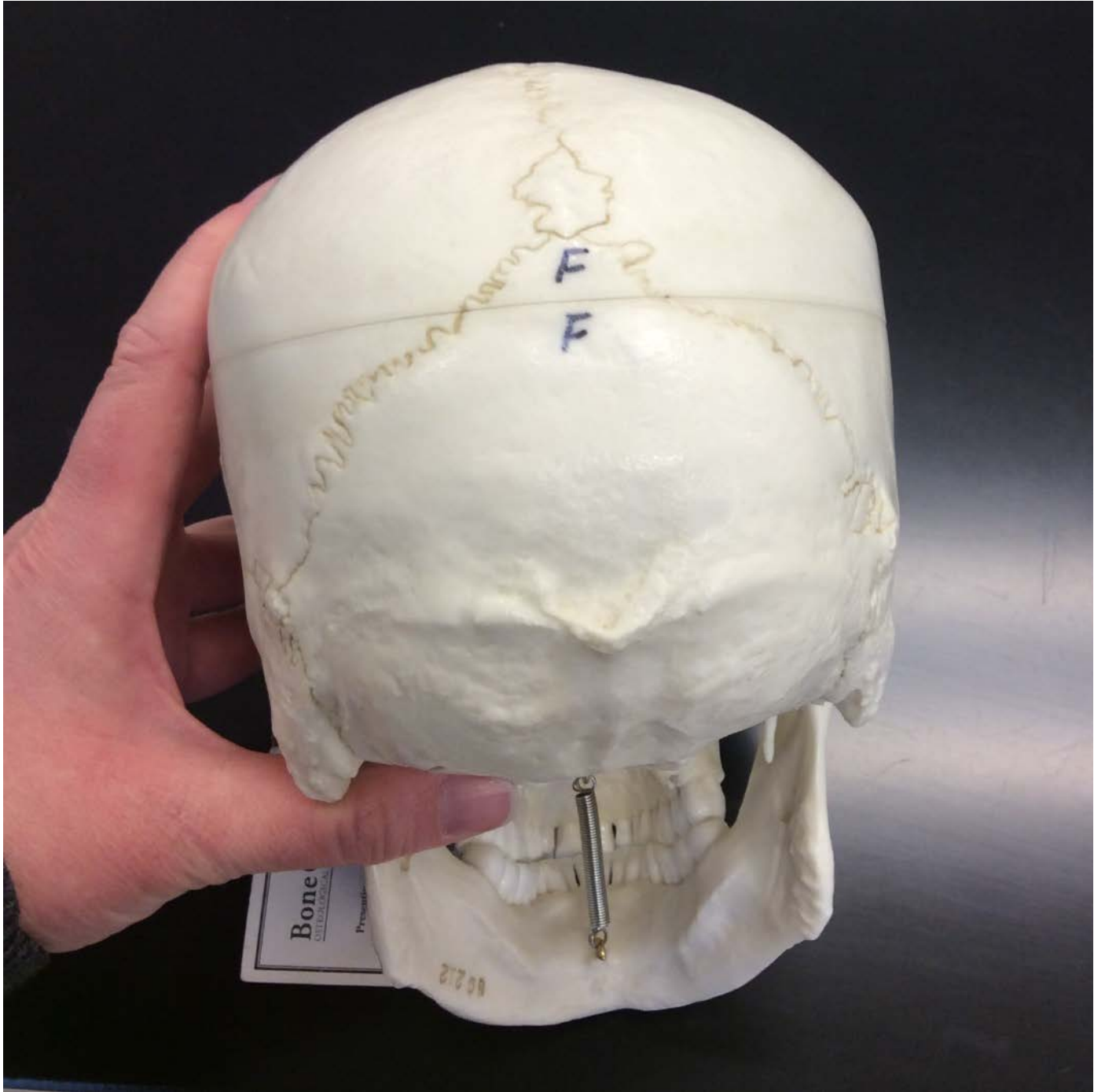Use the following pictures to help you practice finding the terms from the lab term handout on unlabeled images.

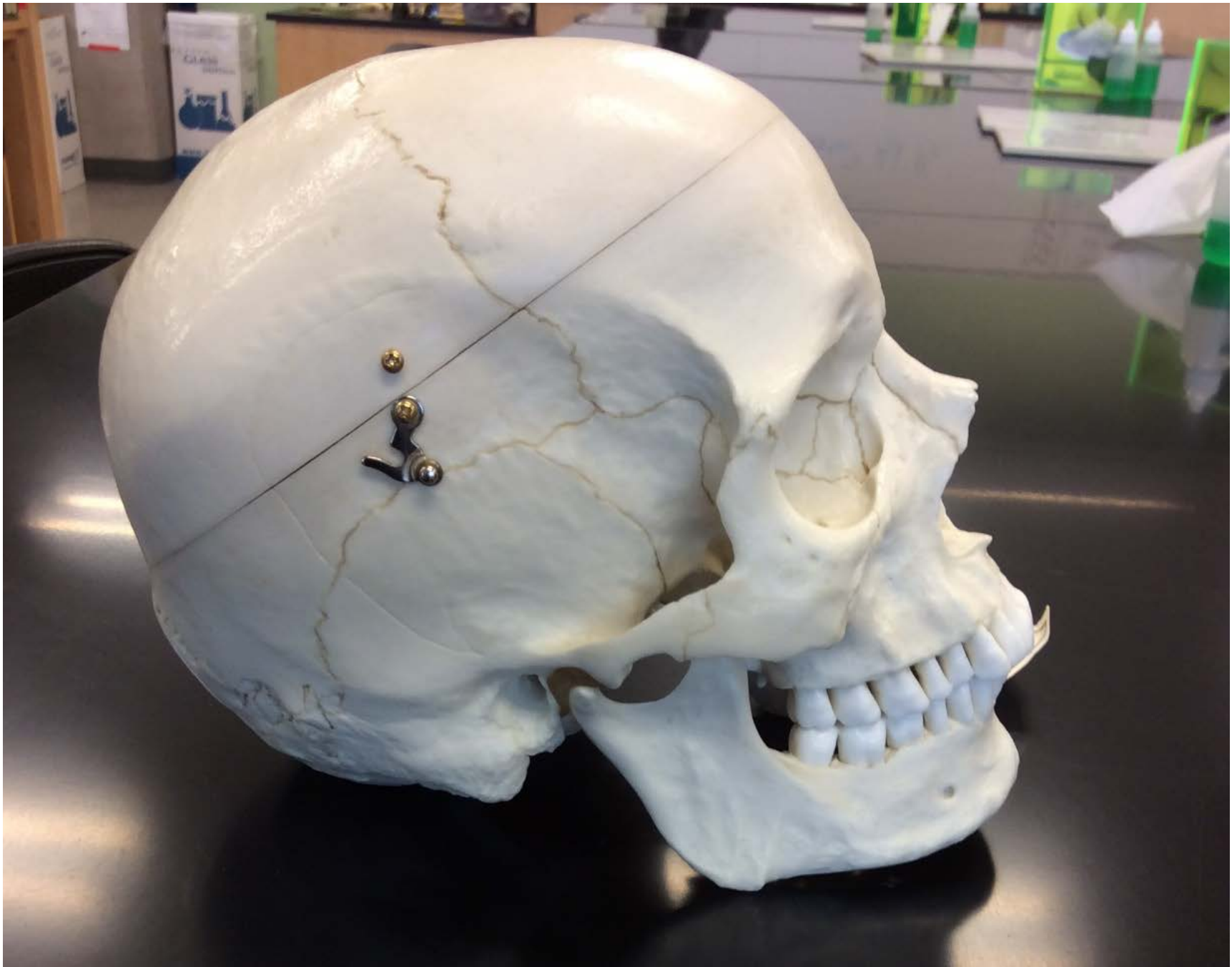- Remember, you won't learn them if you don't take plenty of time to practice!
- Also, be sure to mix up the order once you get comfortable with the unlabeled slides.
- Over the weekend, once you are feeling confident with the pictures here, do the bone model quizzes in PAL (from the Pearson website) to get practice with new pictures that you haven't seen.

Skull: Sutures

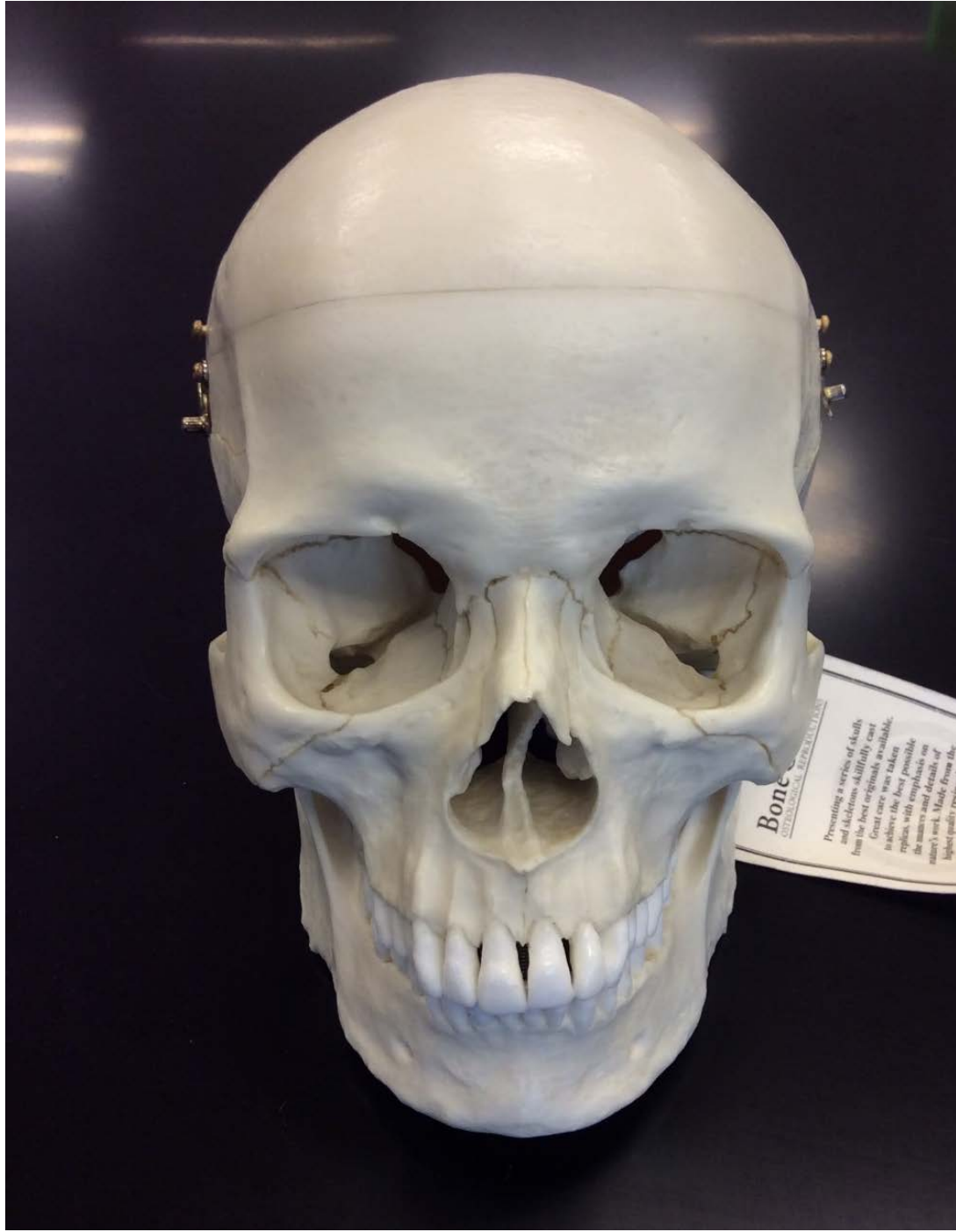






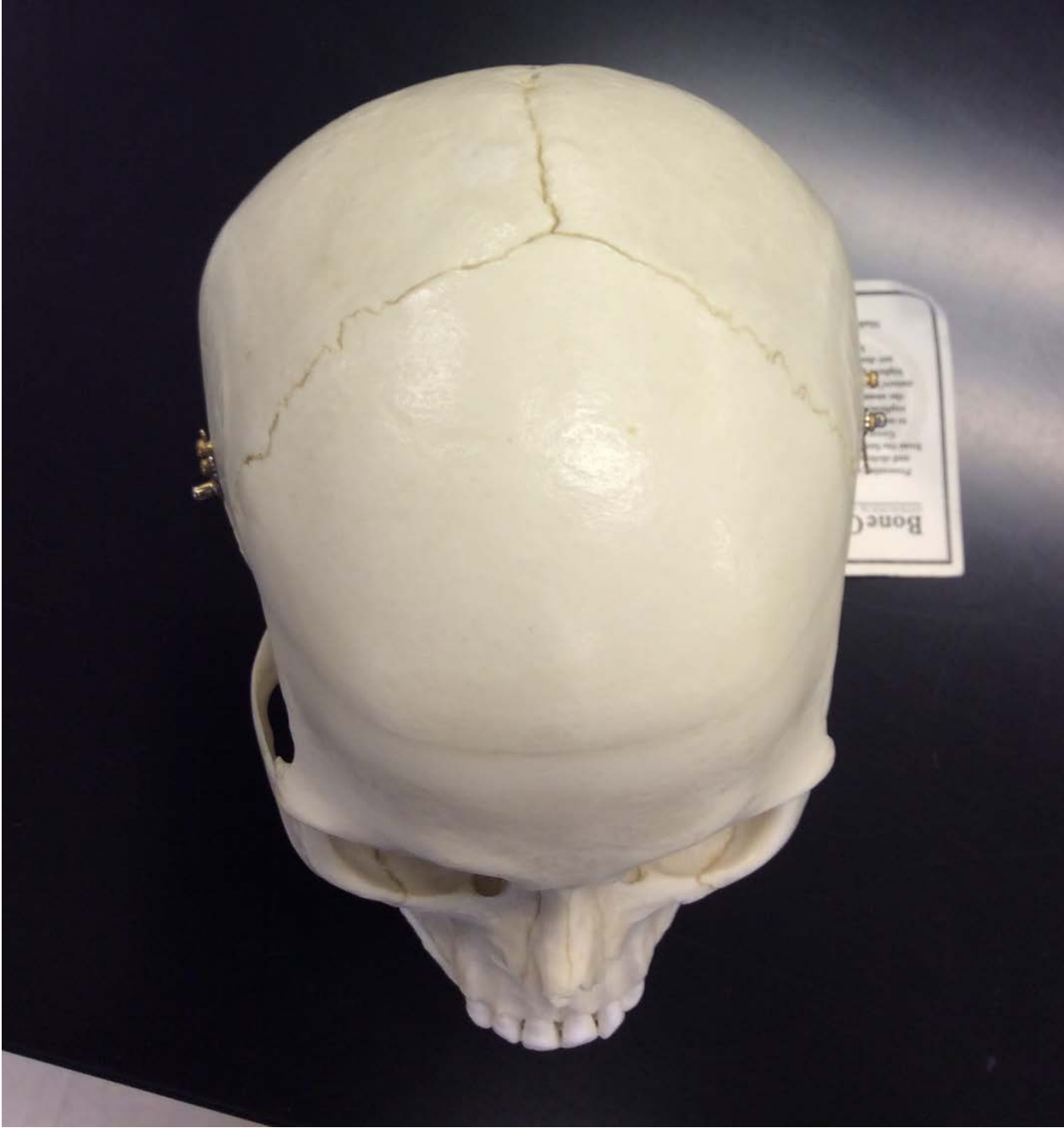


Skull: Cranial Bones and  
Features (projections, foramina, and fissures)



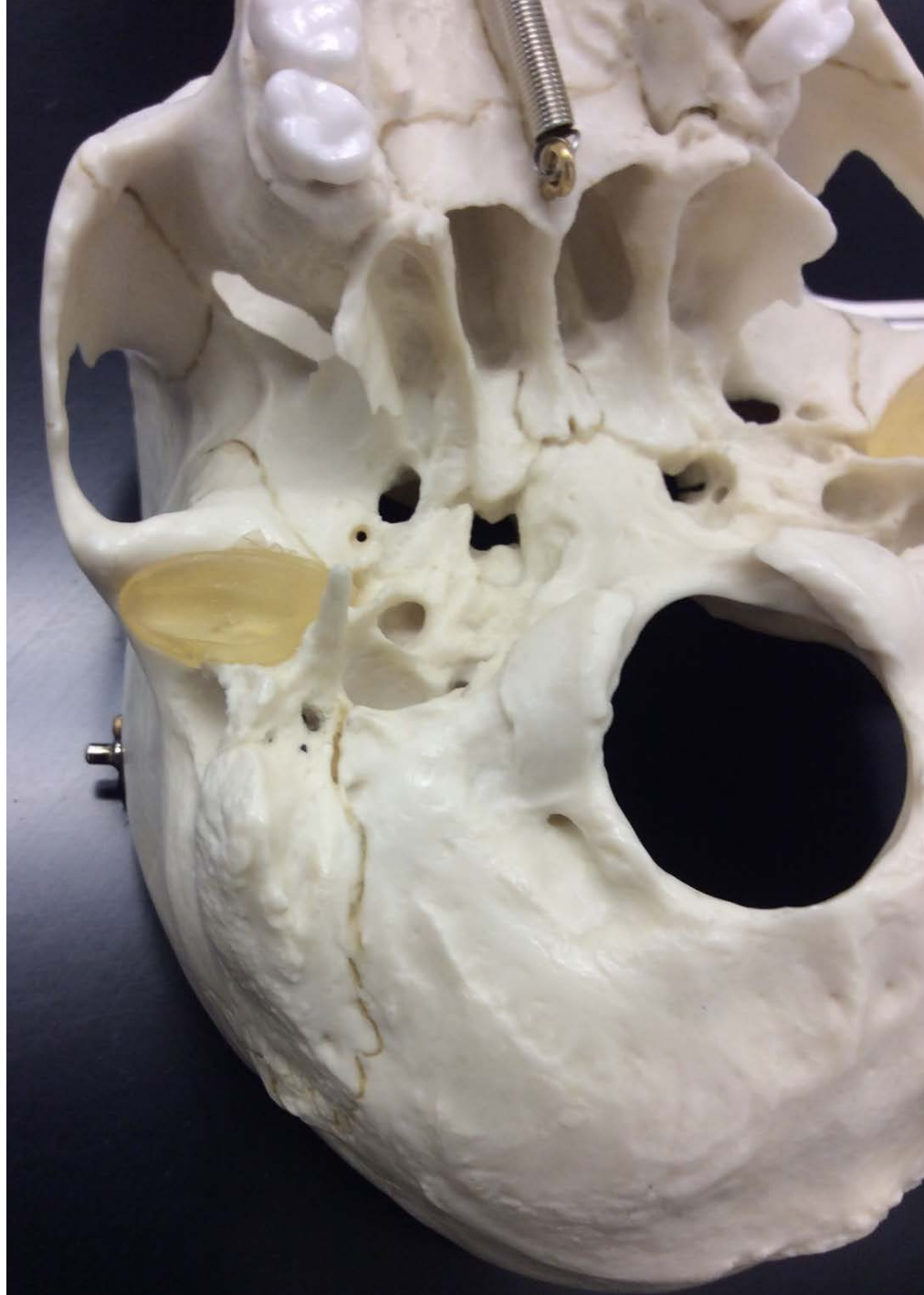**Bone**  
ANTHROPOMORPHIC REPRODUCTION

Presenting a series of skulls and skeletons skillfully cast from the best originals available. Great care was taken to achieve the best possible replicas, with emphasis on the manner and details of nature's work. Made from the highest quality resin.

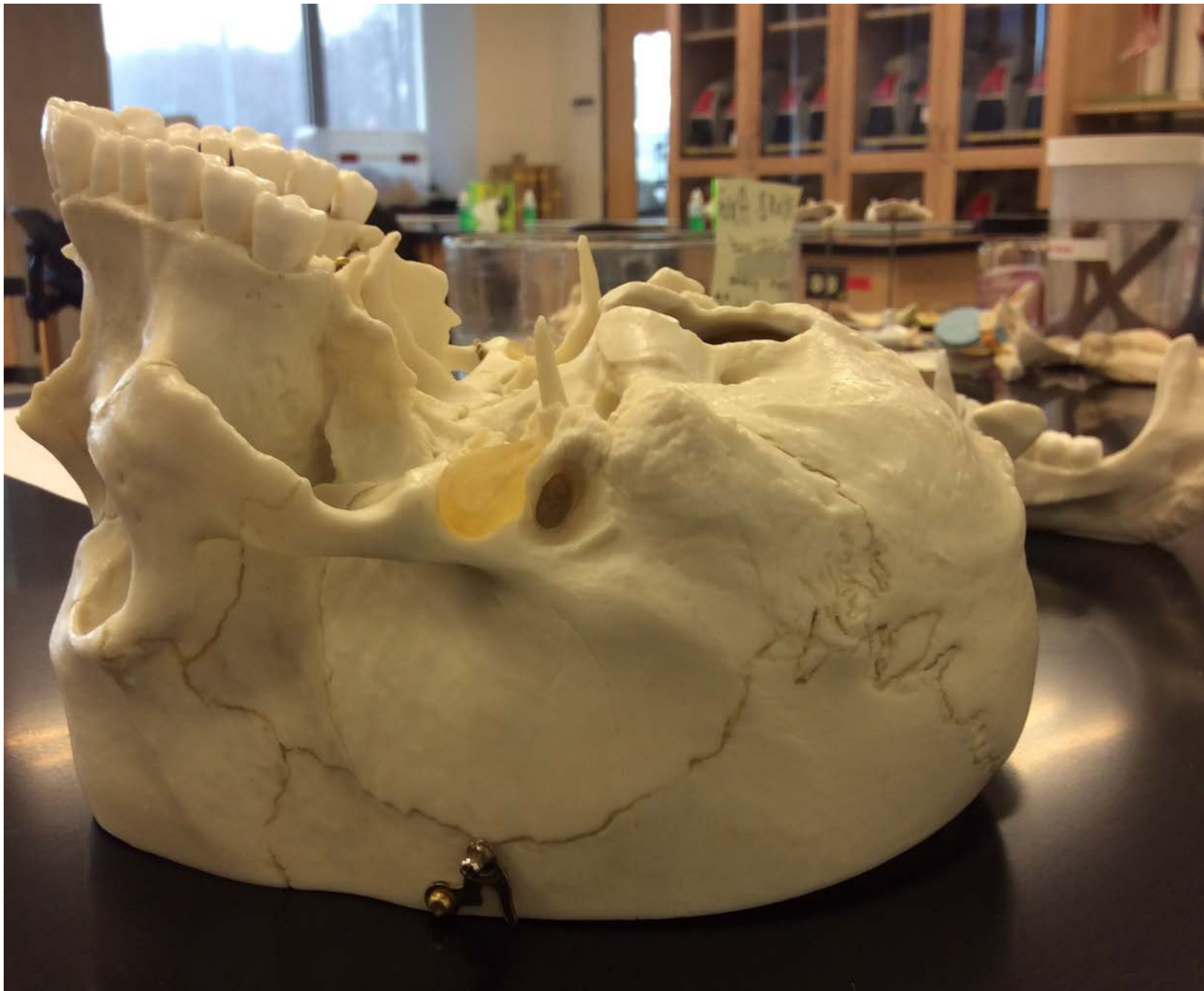

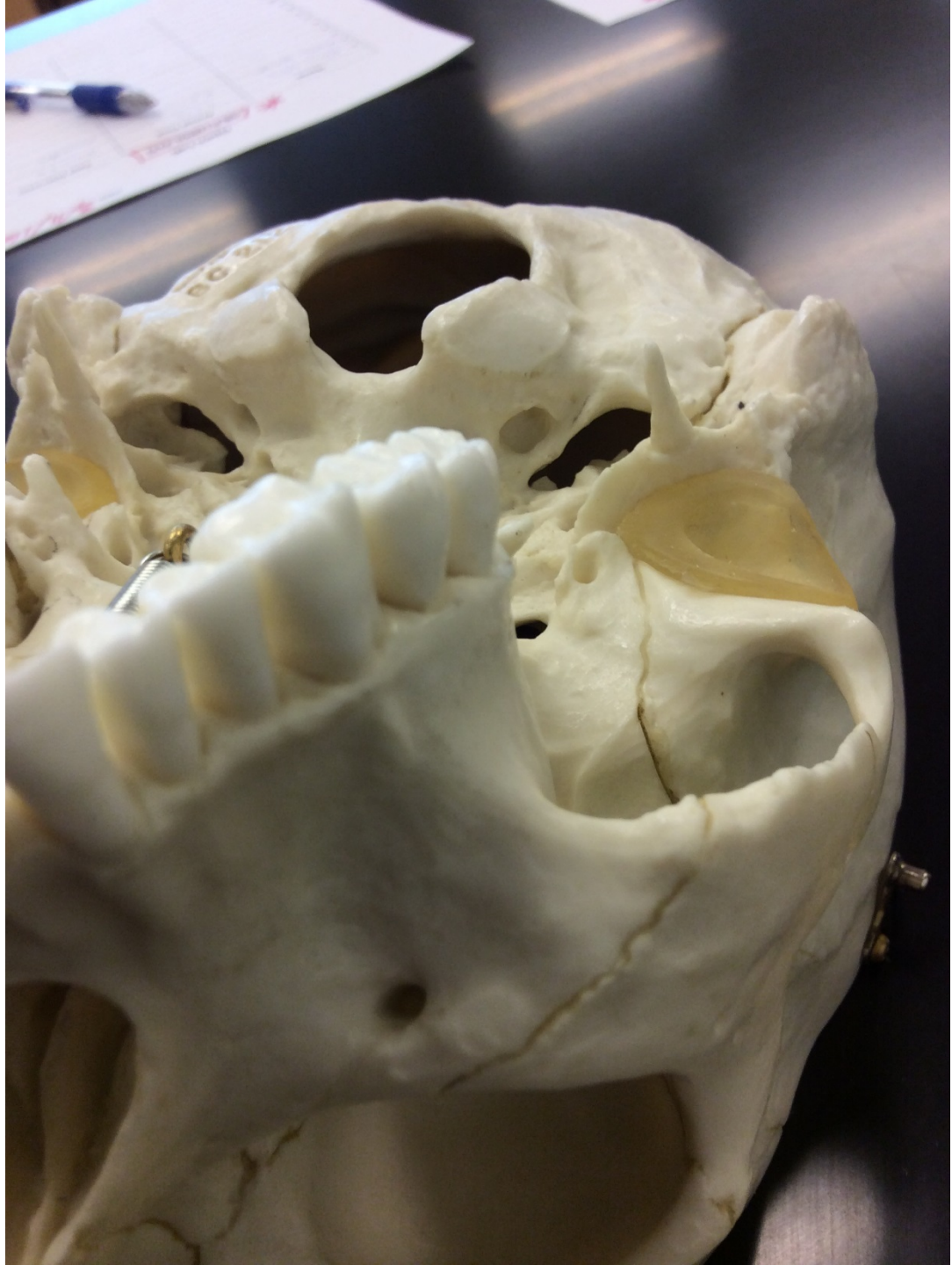


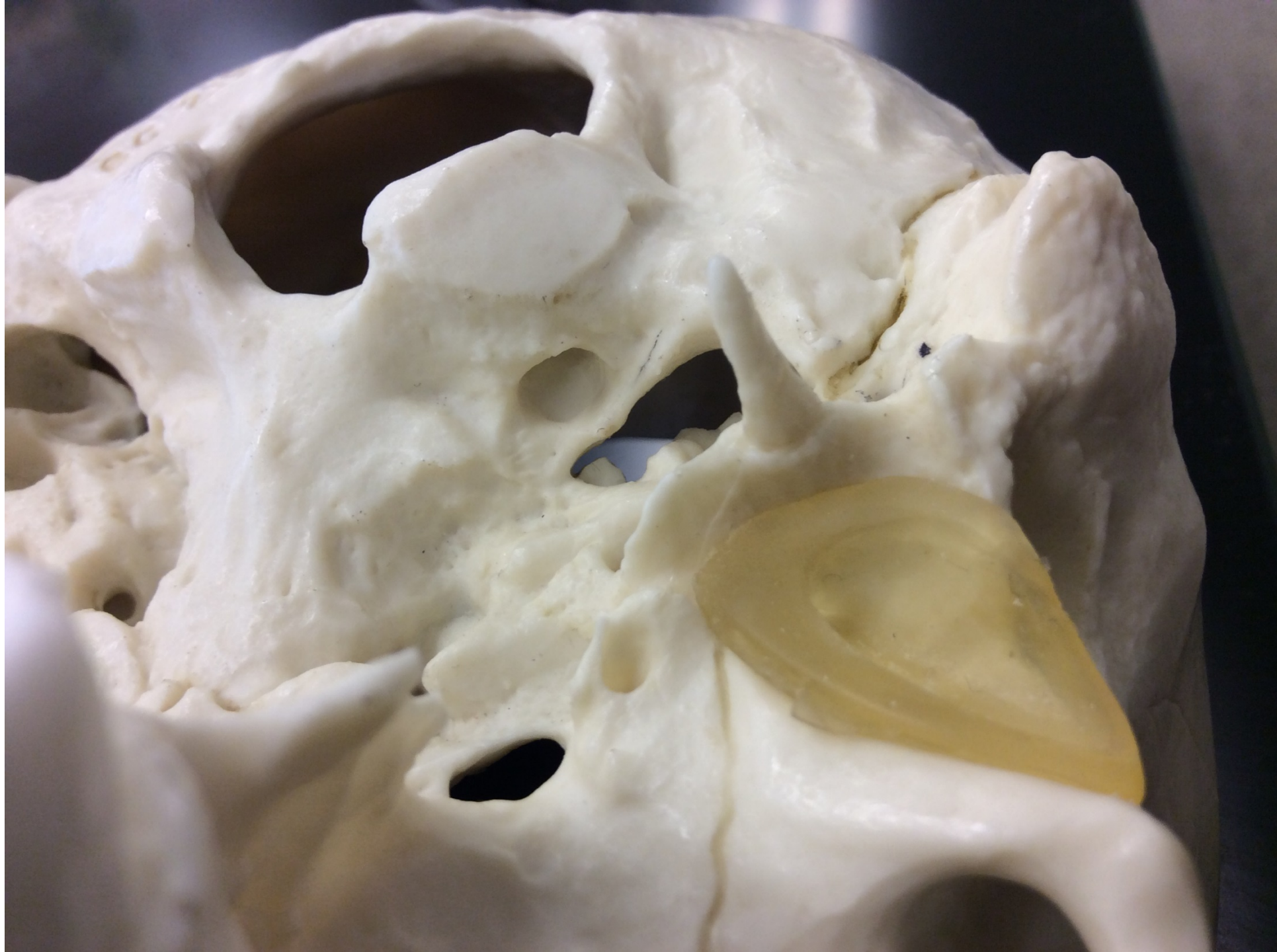


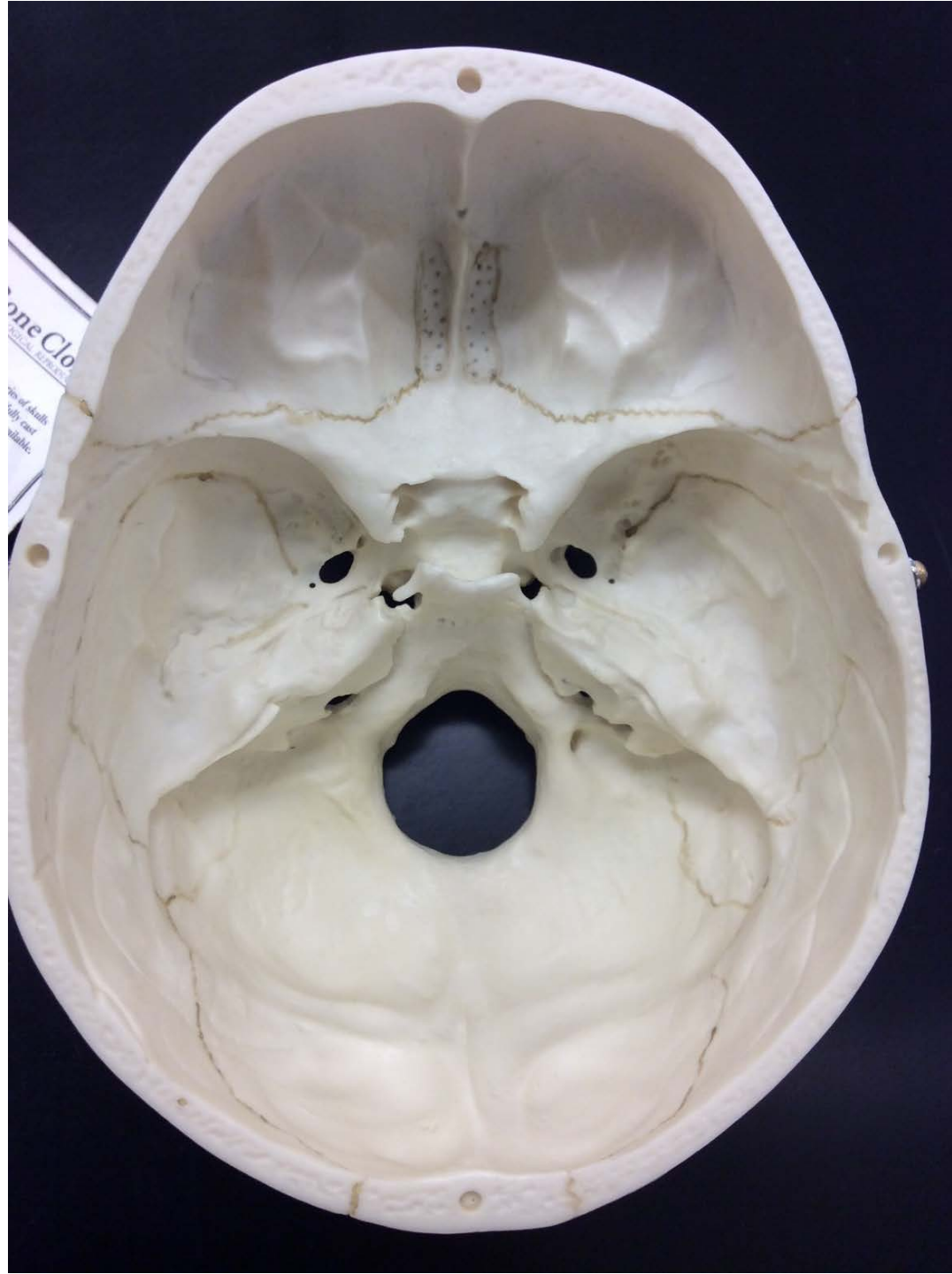






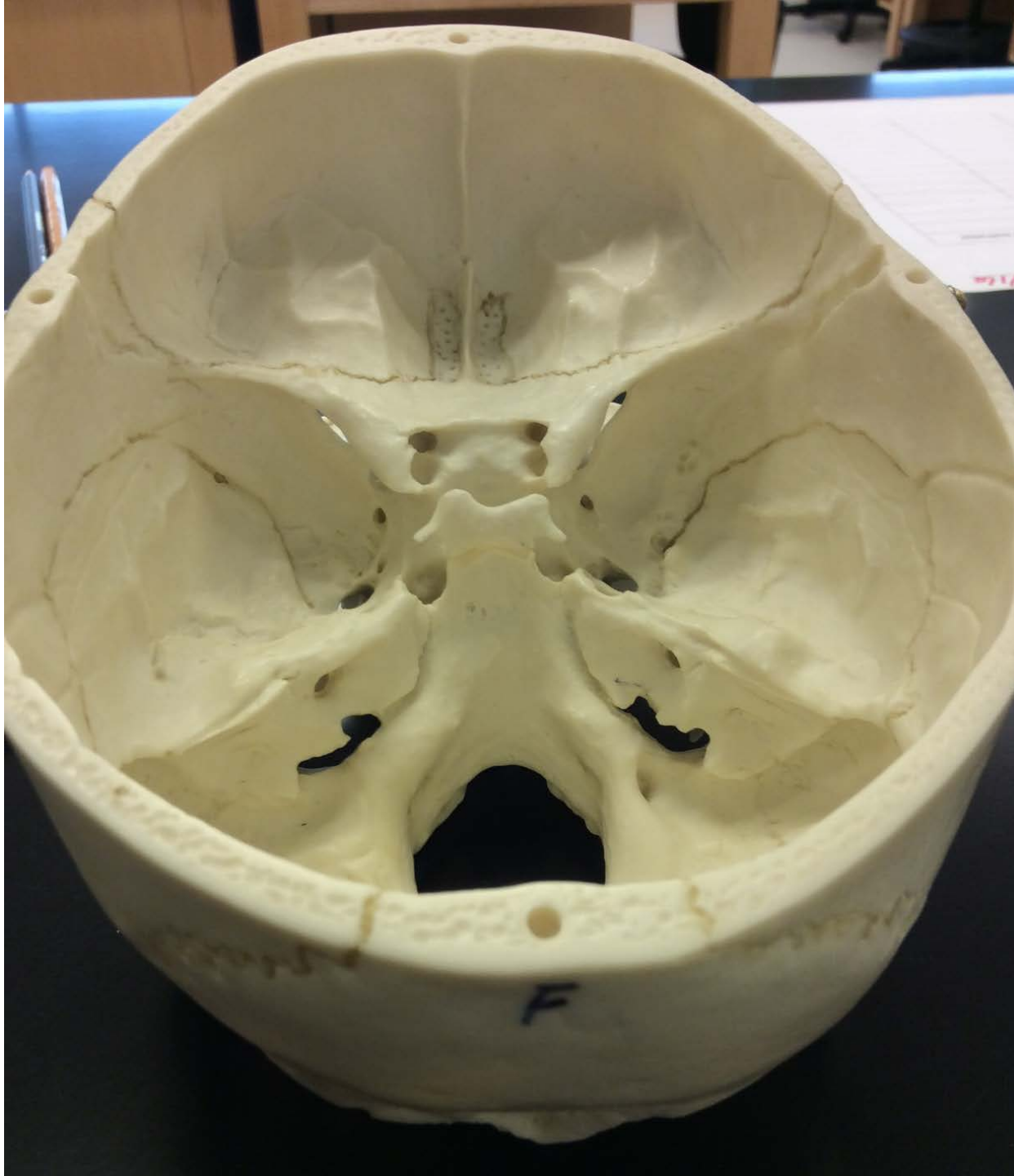


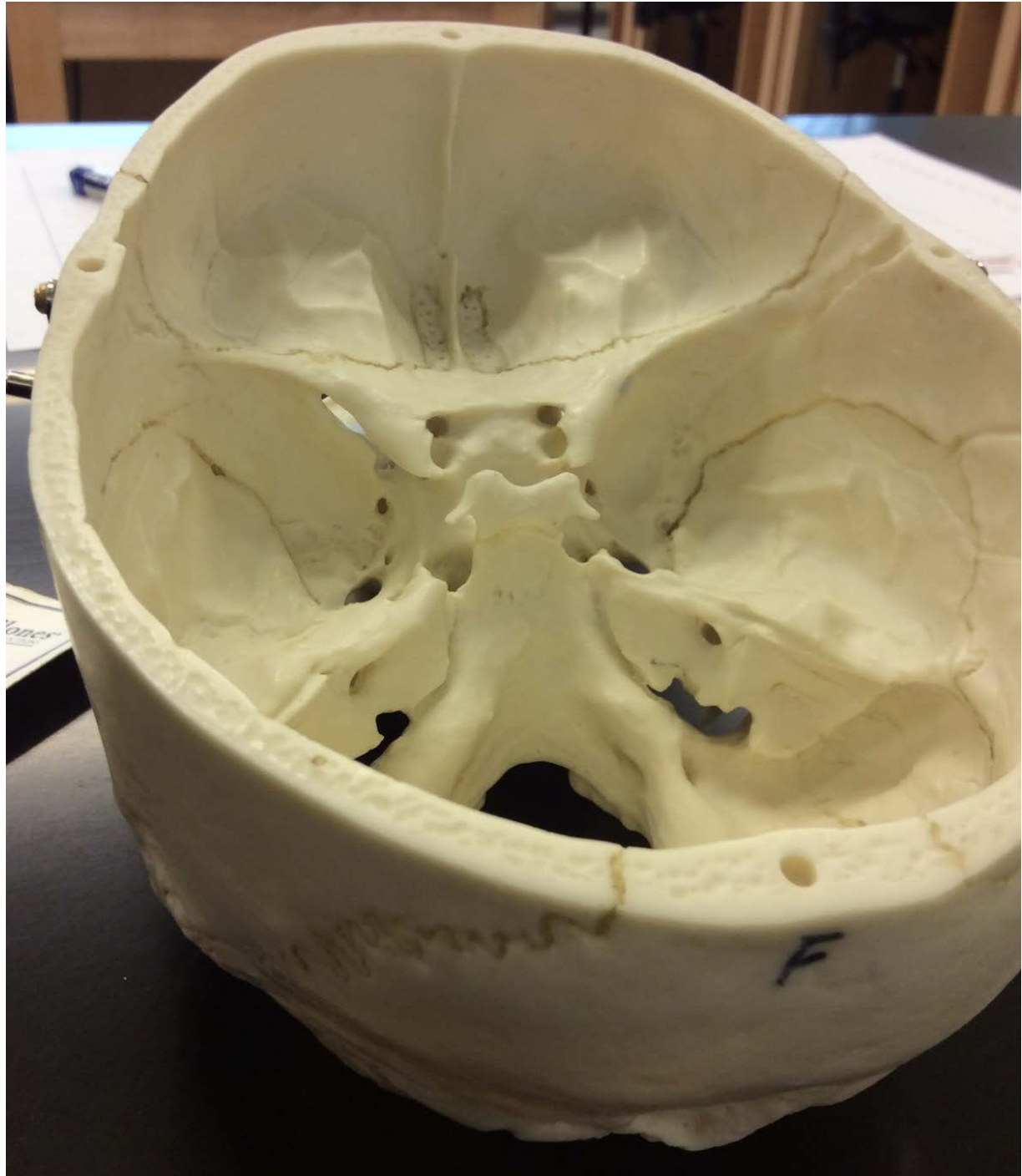


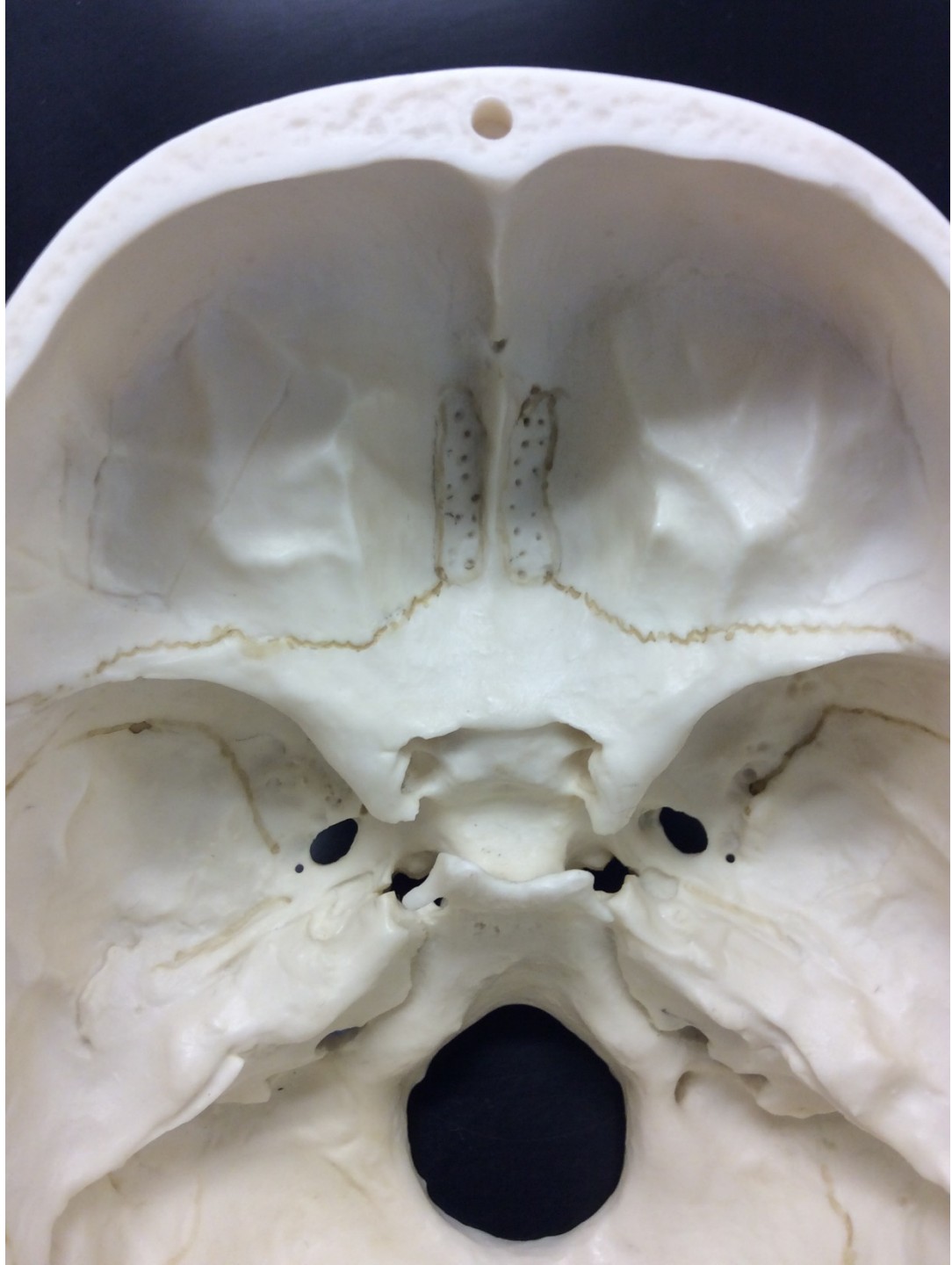


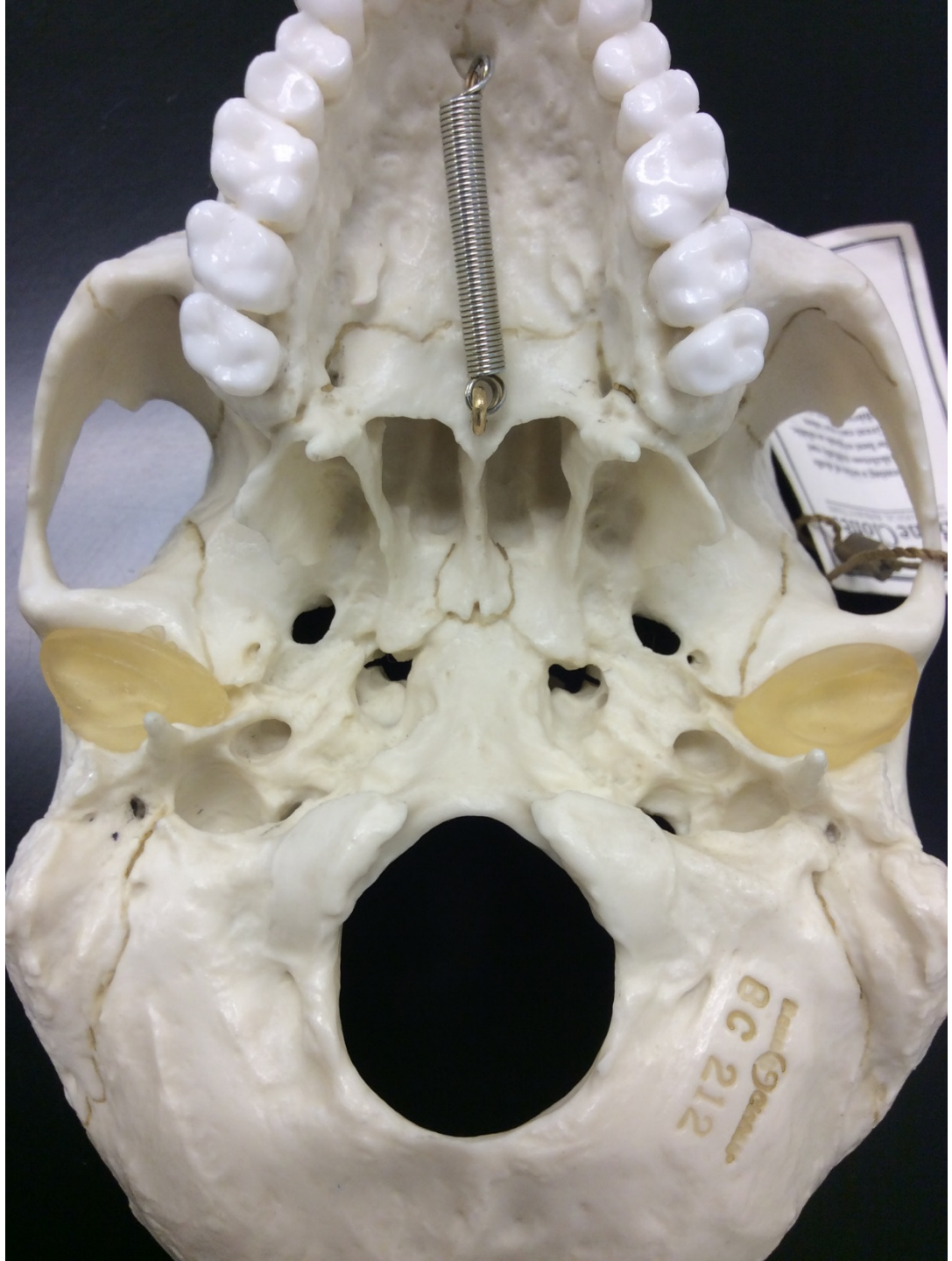one Clo  
ANATOMICAL

one of skulls  
fully ear  
available



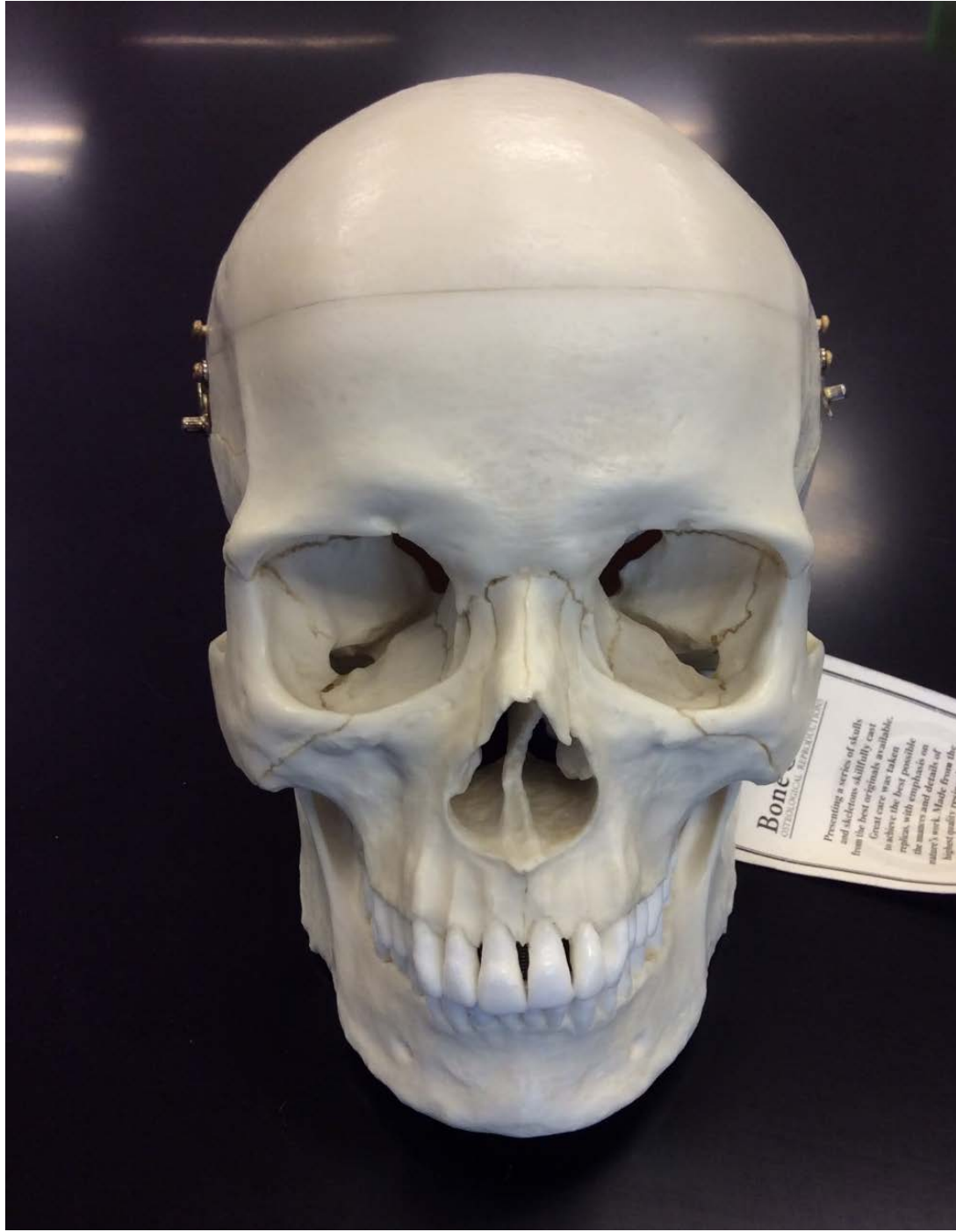






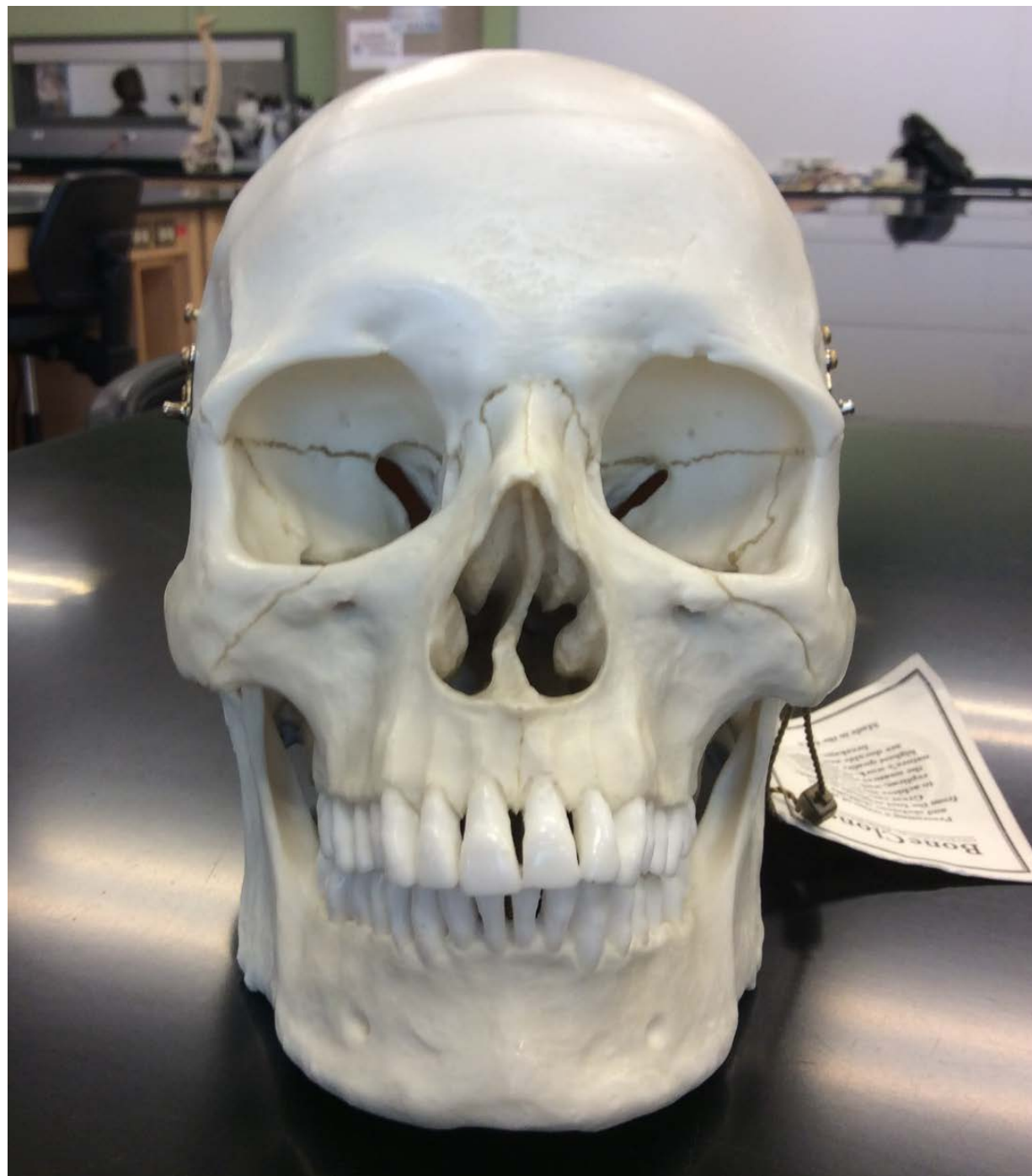

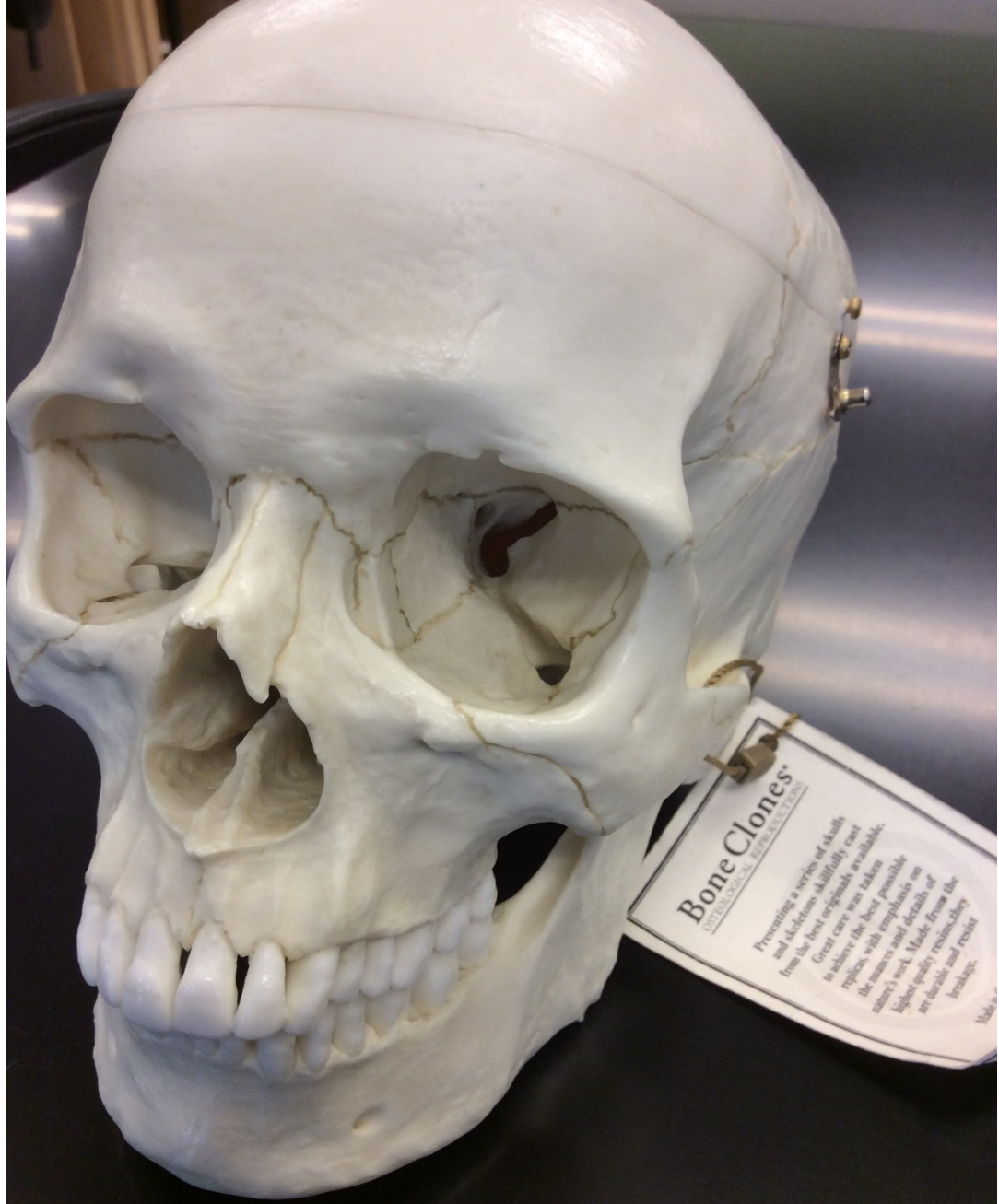# Skull: Facial Bones



**Bone**  
ANTHROPOMORPHIC REPRODUCTION

Presenting a series of skulls and skeletons skillfully cast from the best originals available. Great care was taken to achieve the best possible replicas, with emphasis on the manner and details of nature's work. Made from the highest quality resin.



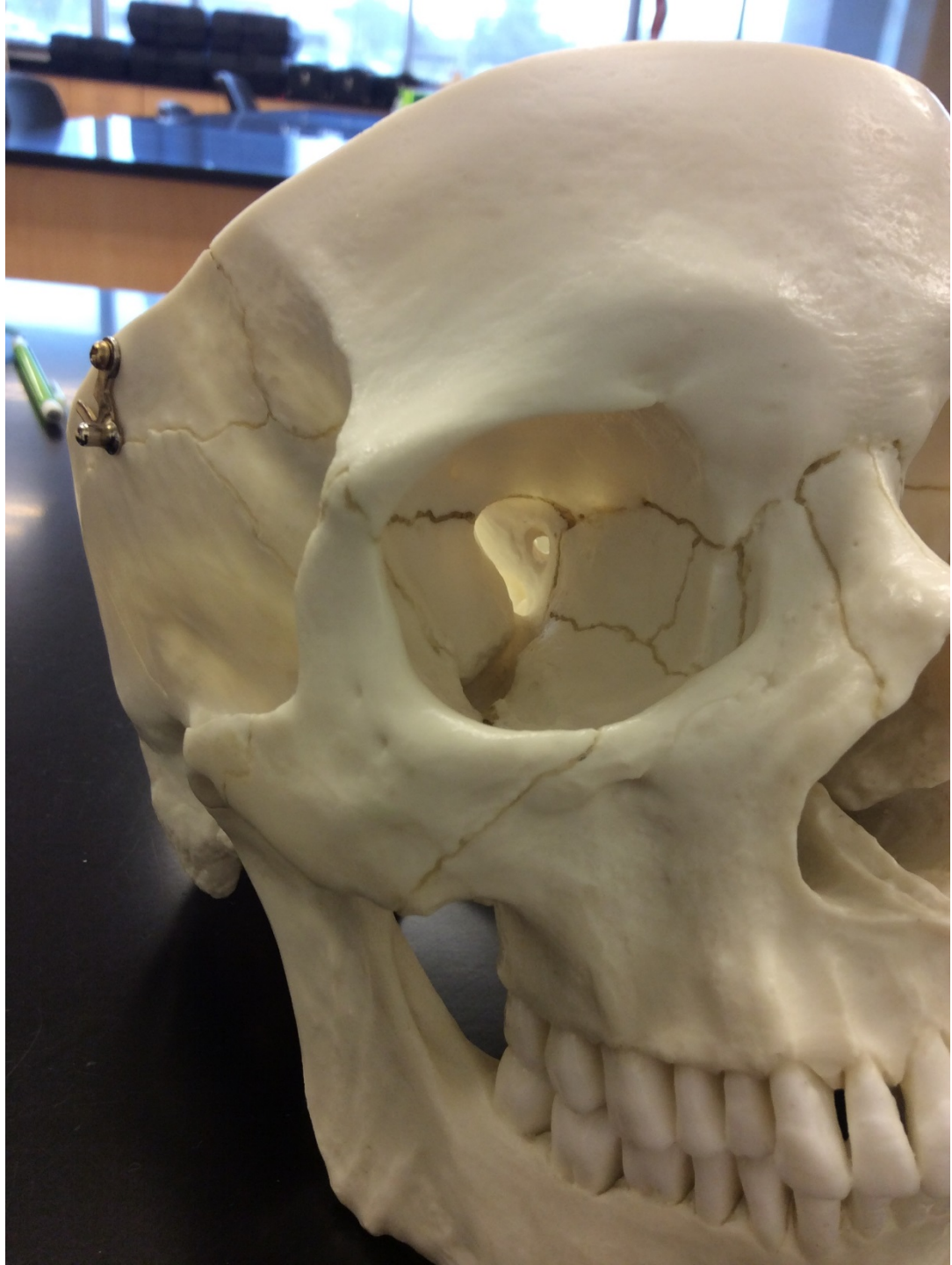

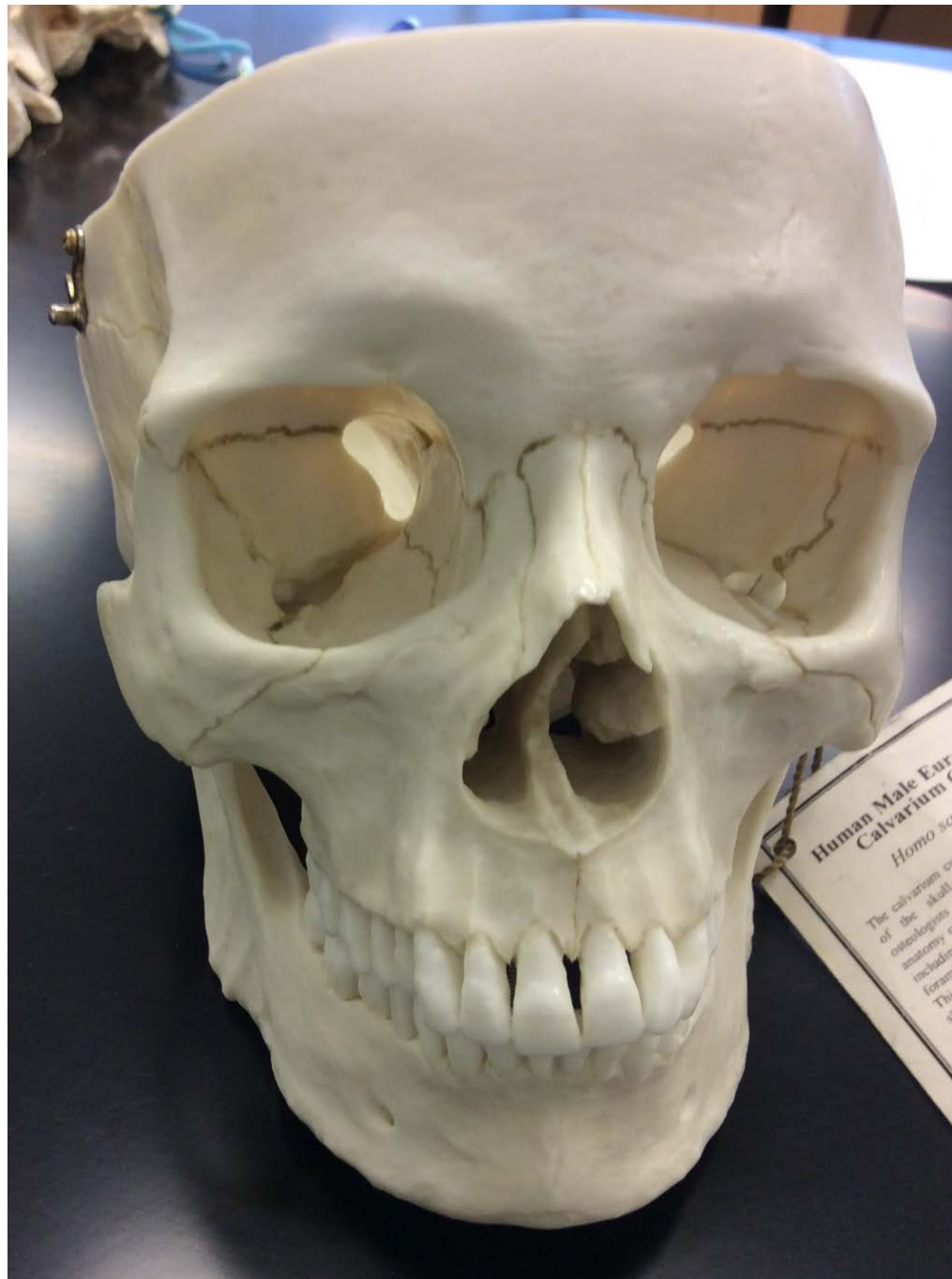
**Bone Clones®**  
ANATOMICAL REPLICAS

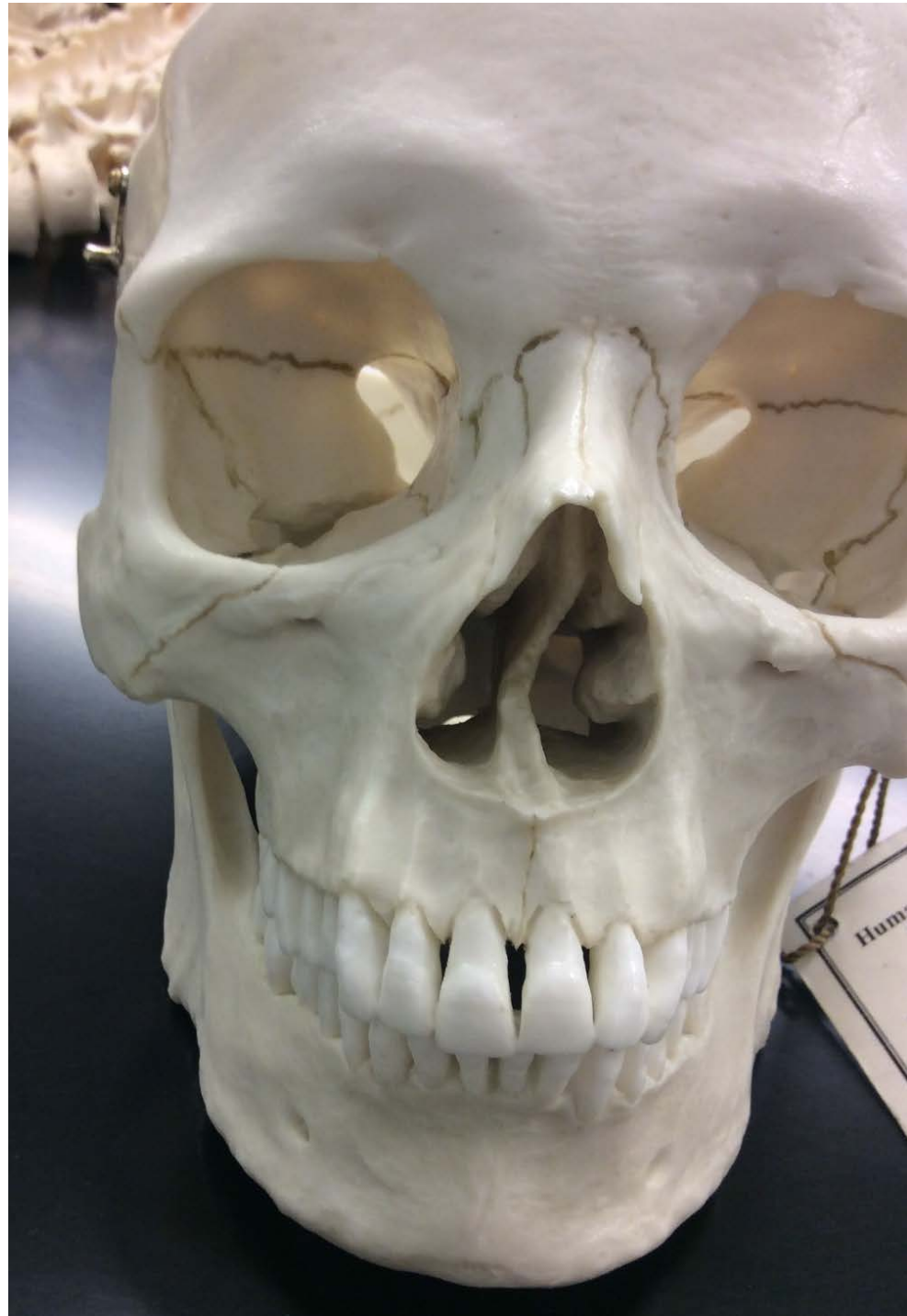
Presenting a series of skulls and skeletons skillfully cast from the best originals available. Great care was taken to achieve the best possible replicas with emphasis on the sinuses and details of sutures' work. Made from the highest quality resins, they are durable and resist breakage.

Model

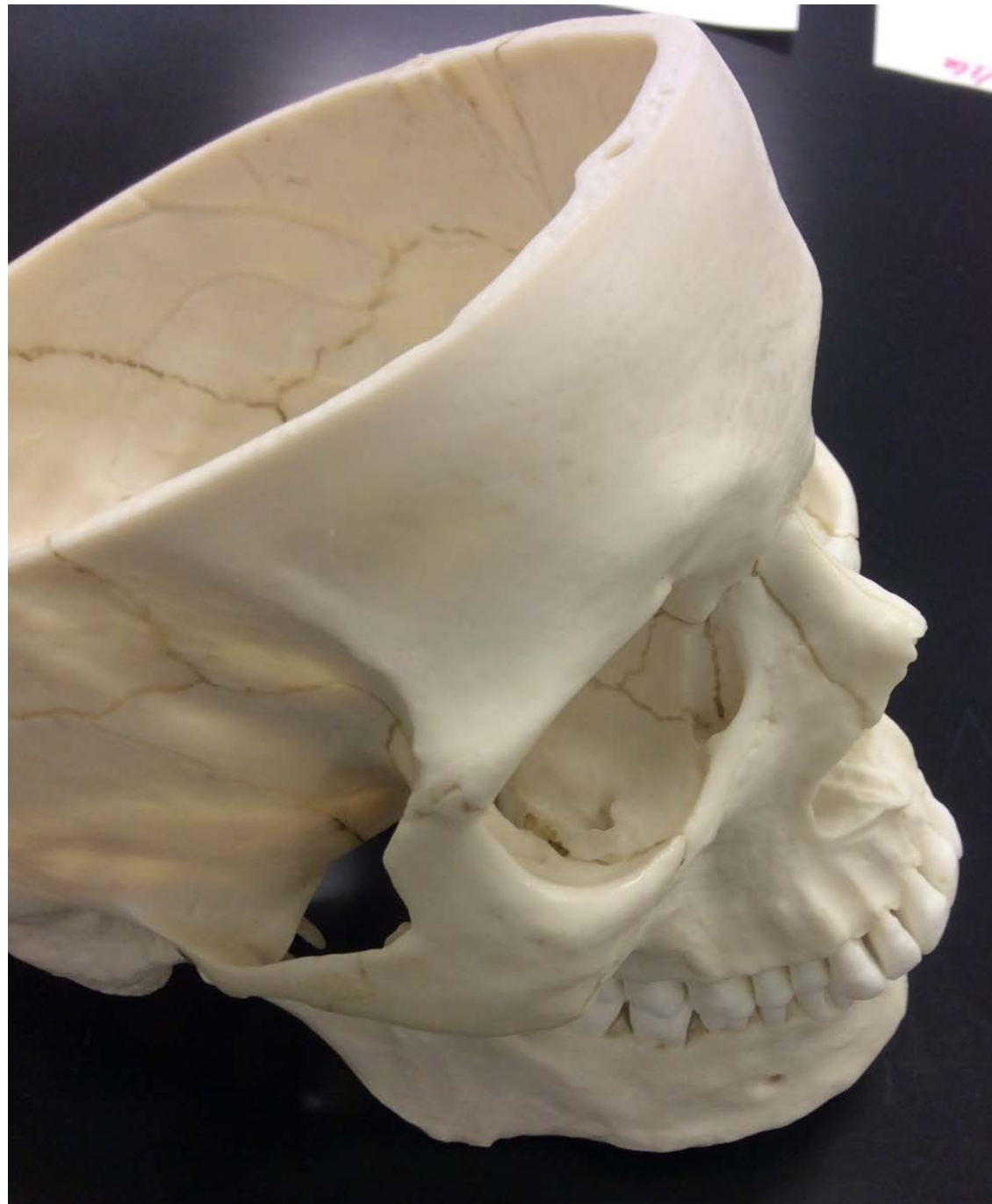





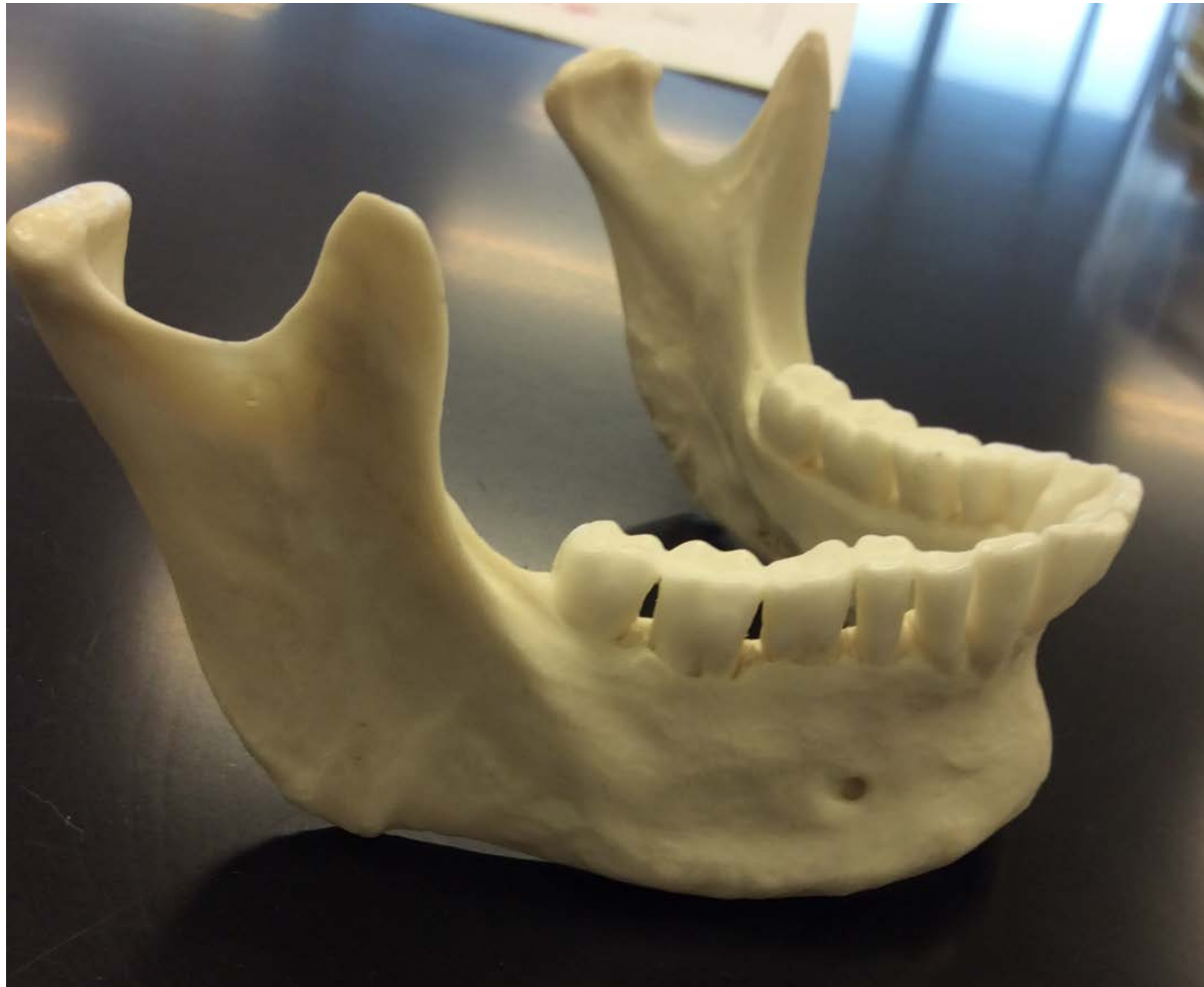


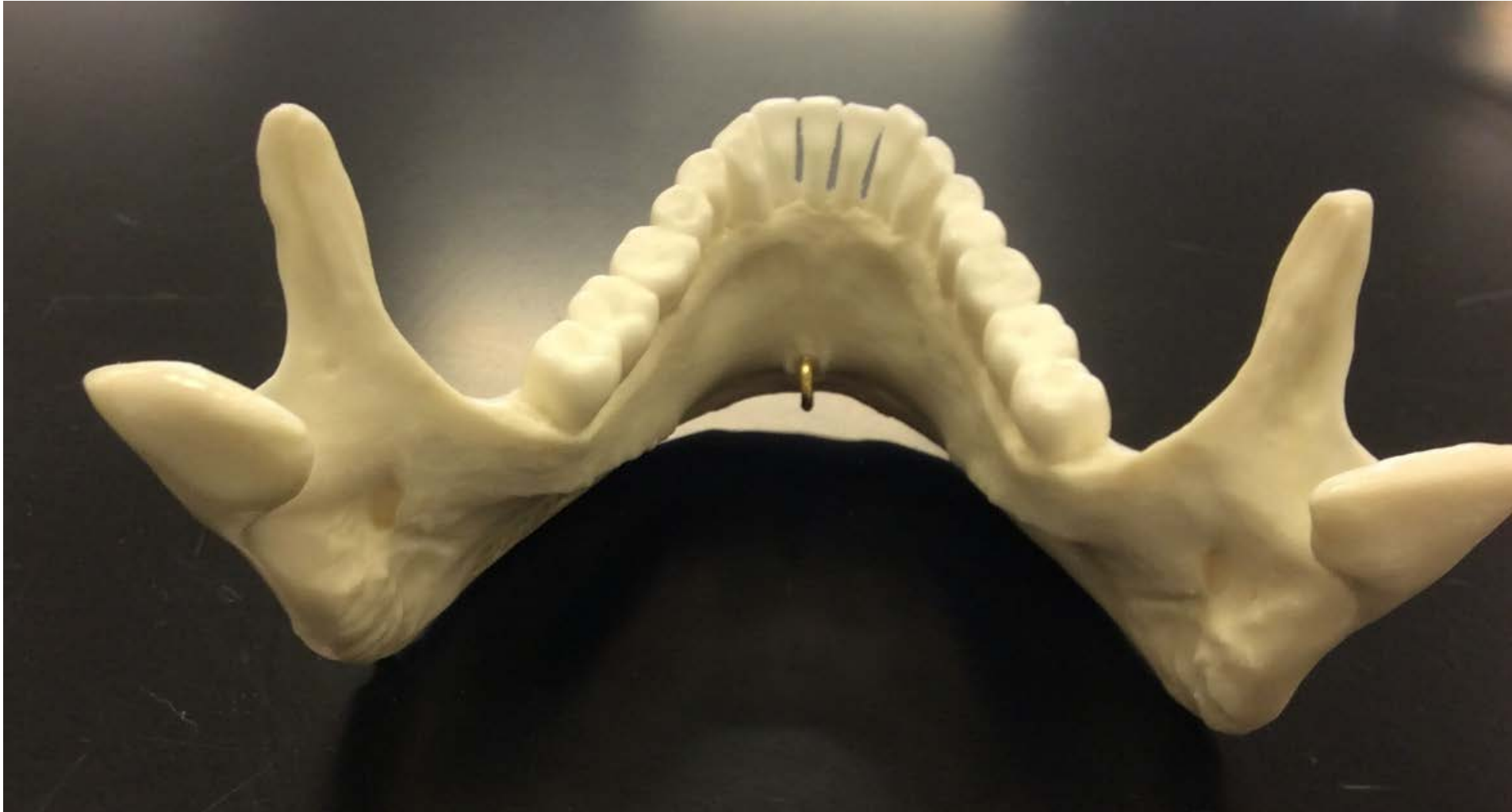
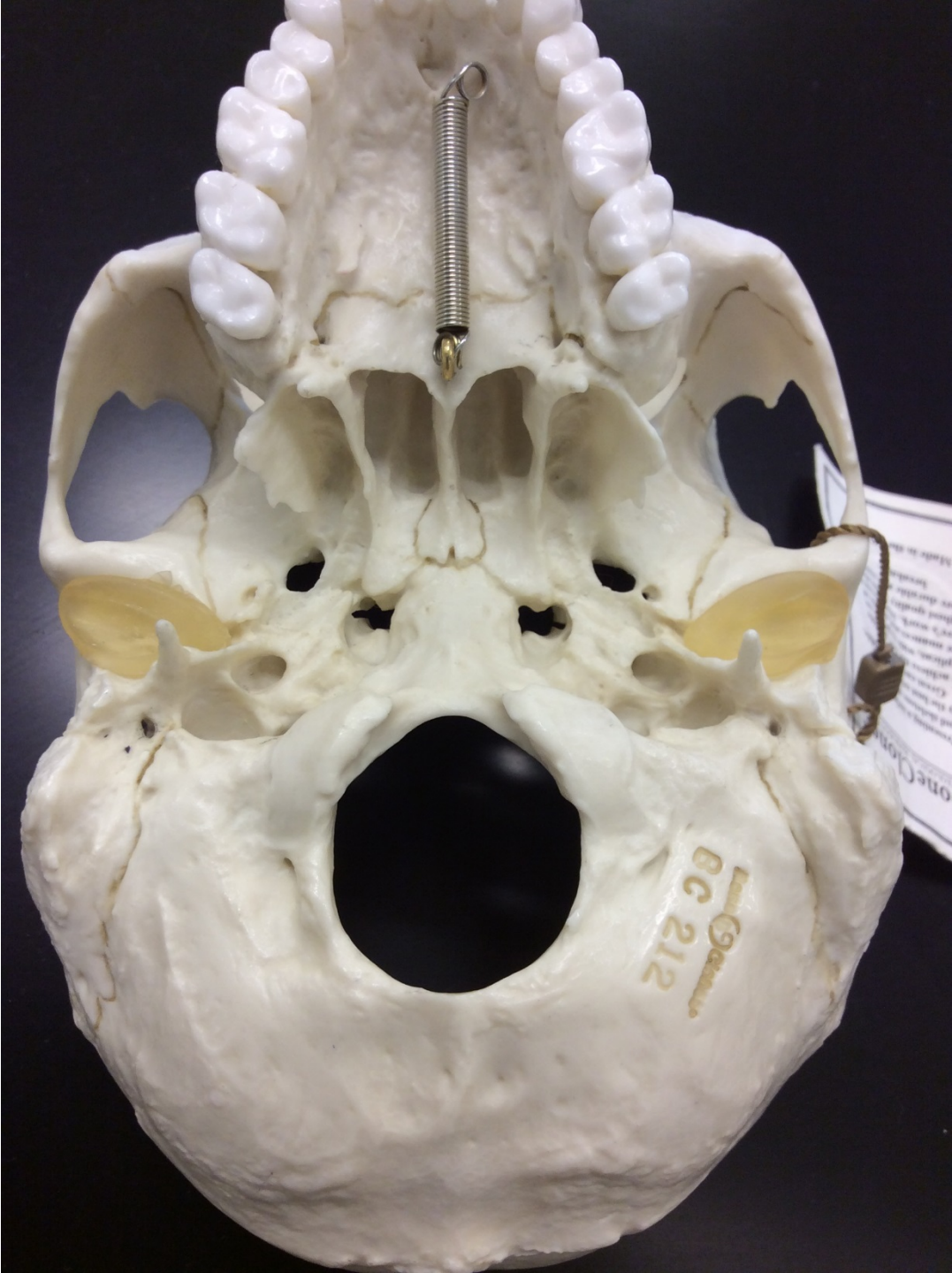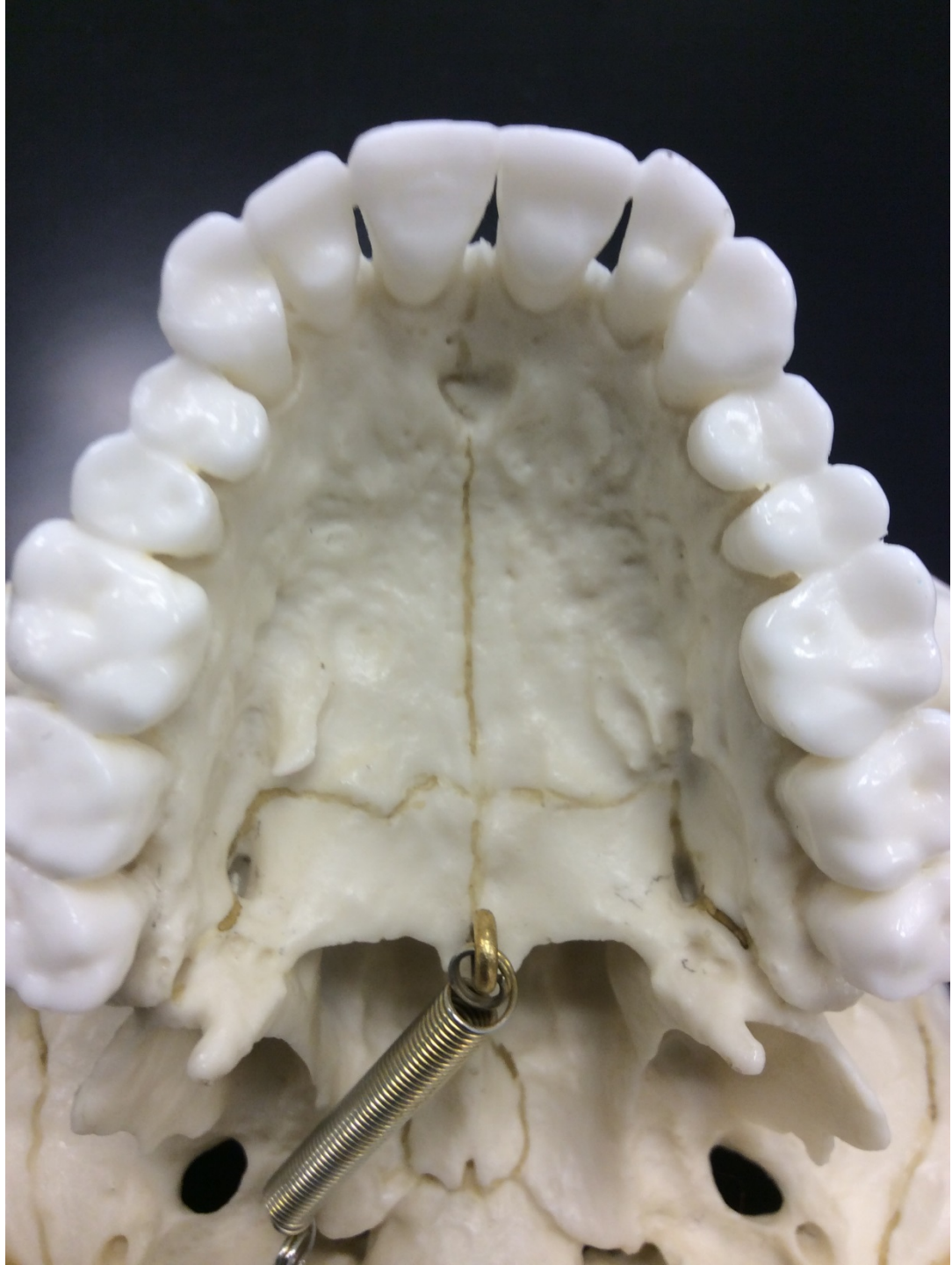








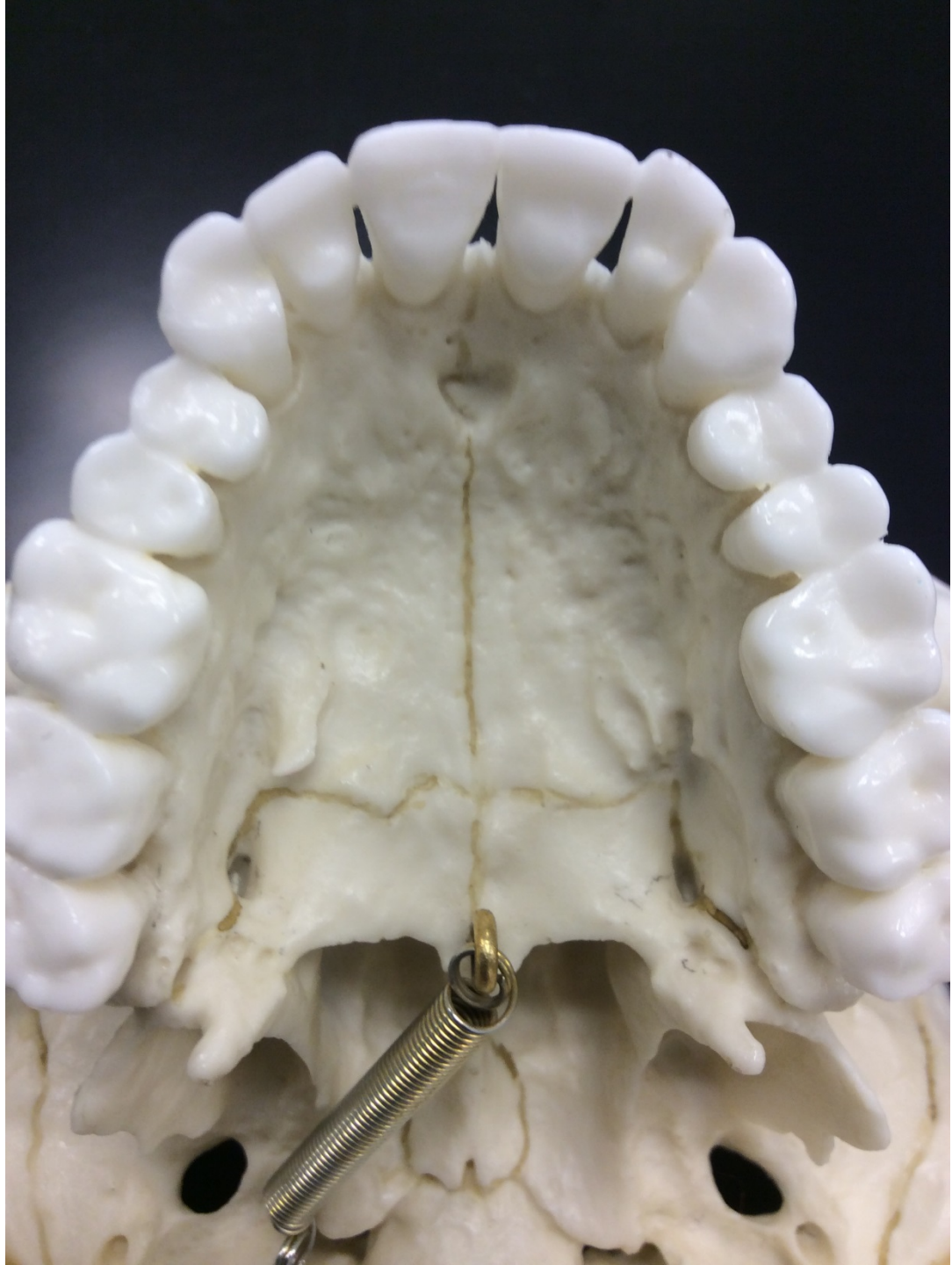




Skull: Regions composed of two bones

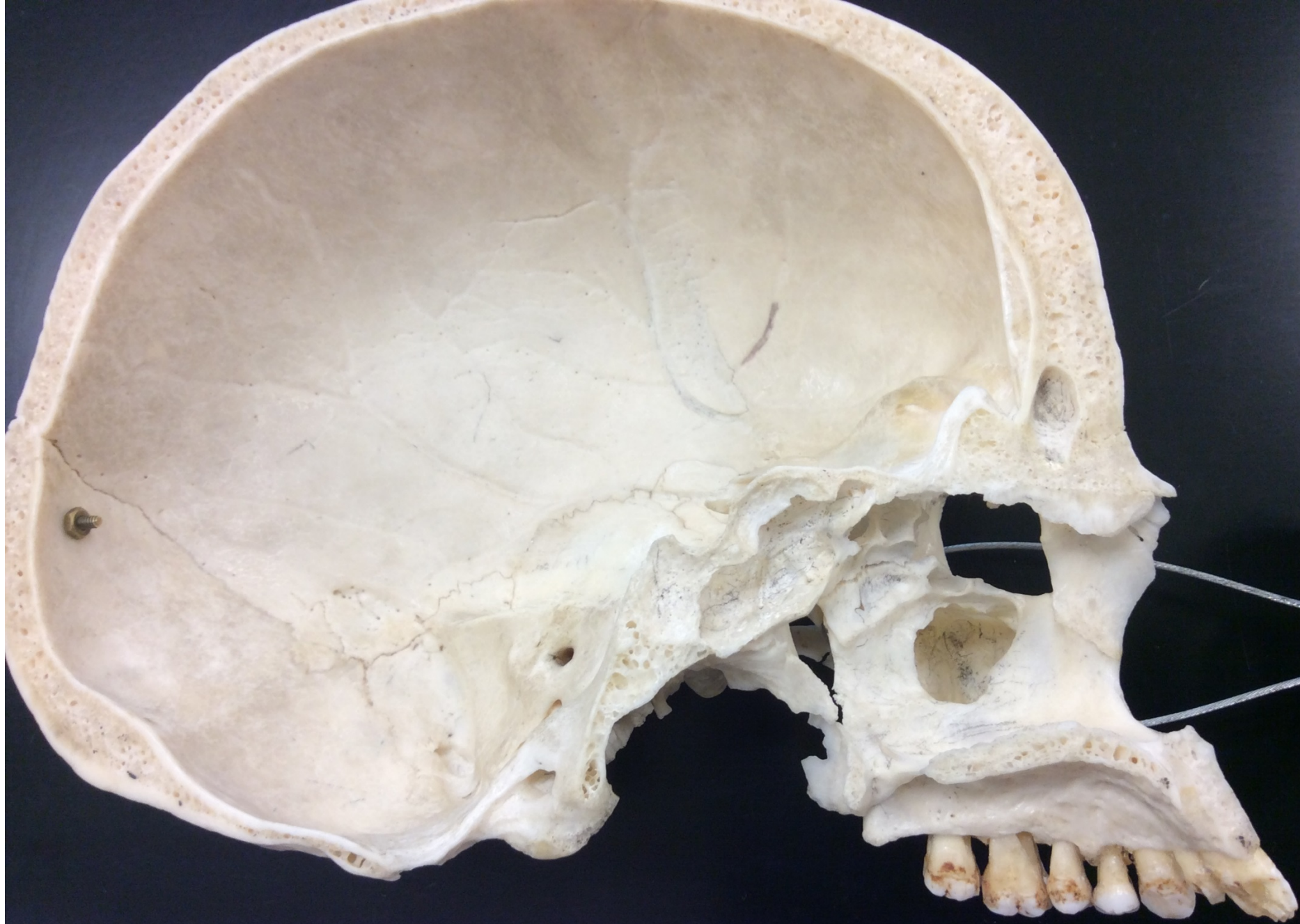

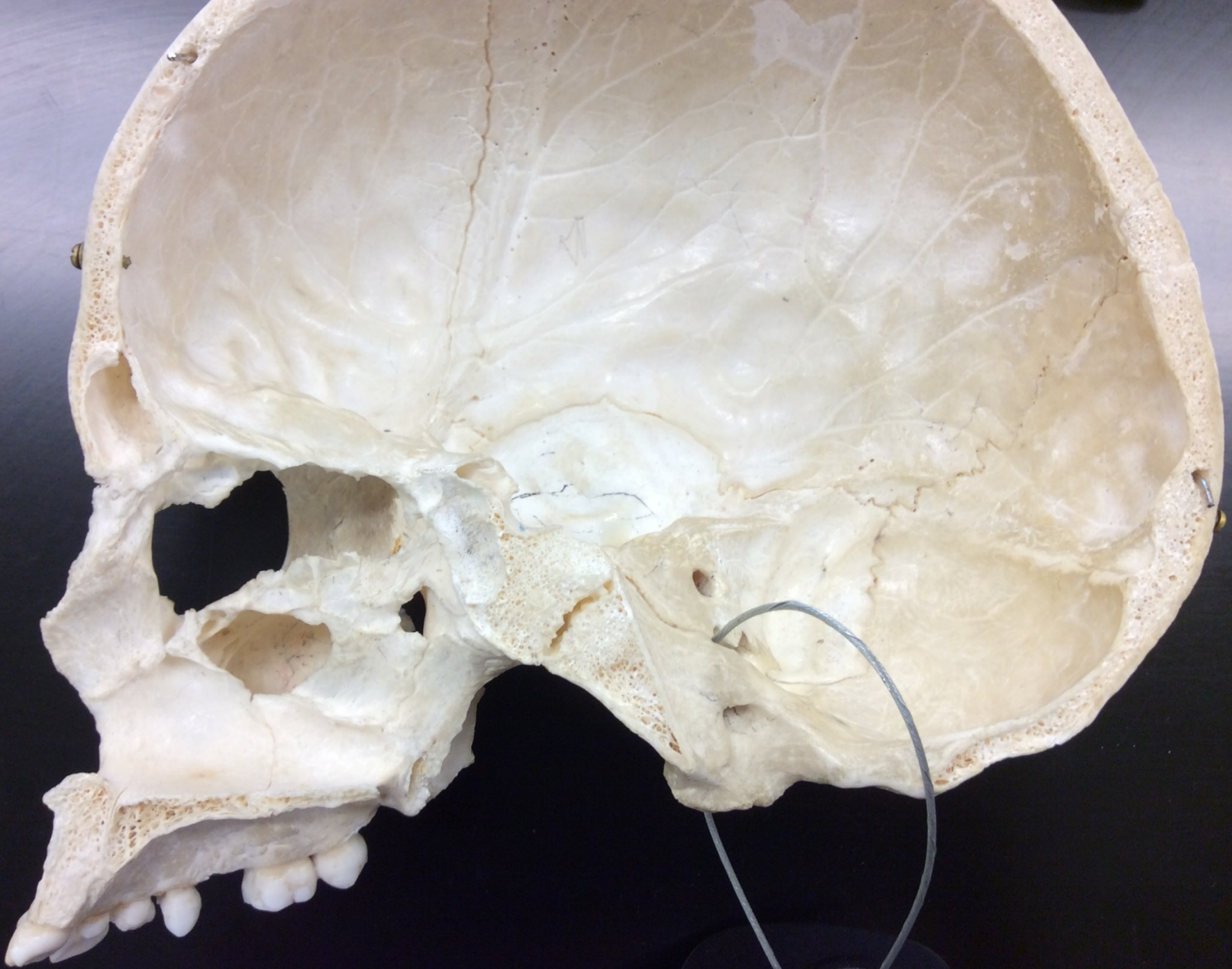



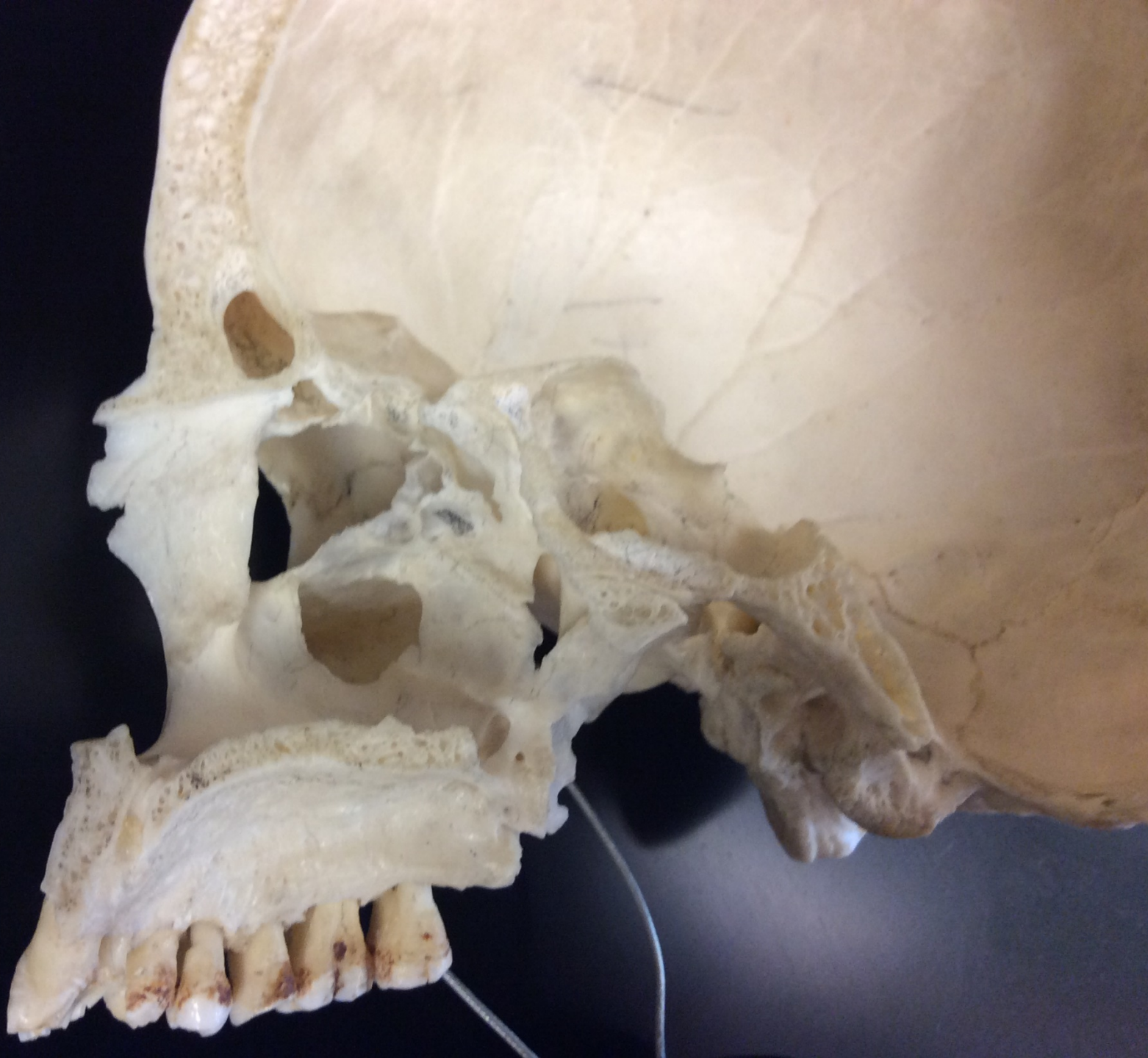


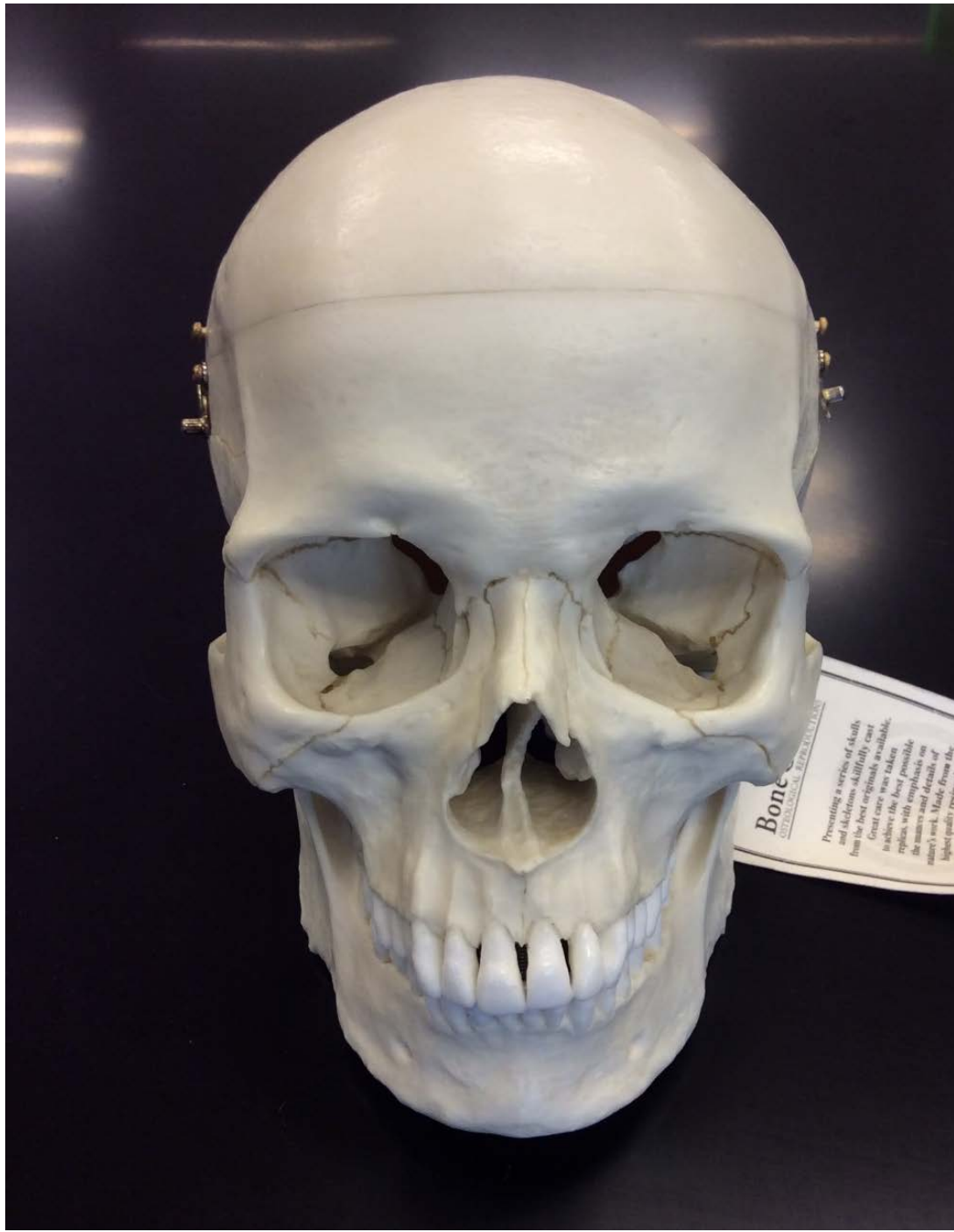Skull: Sinuses







# Skull: Bones of the Orbit



**Bone**  
ANTHROPOMORPHIC REPRODUCTION

Presenting a series of skulls and skeletons skillfully cast from the best originals available. Great care was taken to achieve the best possible replicas, with emphasis on the manner and details of nature's work. Made from the highest quality resins.





**Bone Clones®**  
ANATOMICAL REPLICAS

Presenting a series of skulls and skeletons skillfully cast from the best originals available. Great care was taken to achieve the best possible replicas with emphasis on the anatomy and details of nature's work. Made from the highest quality resins, they are durable and resist breakage.

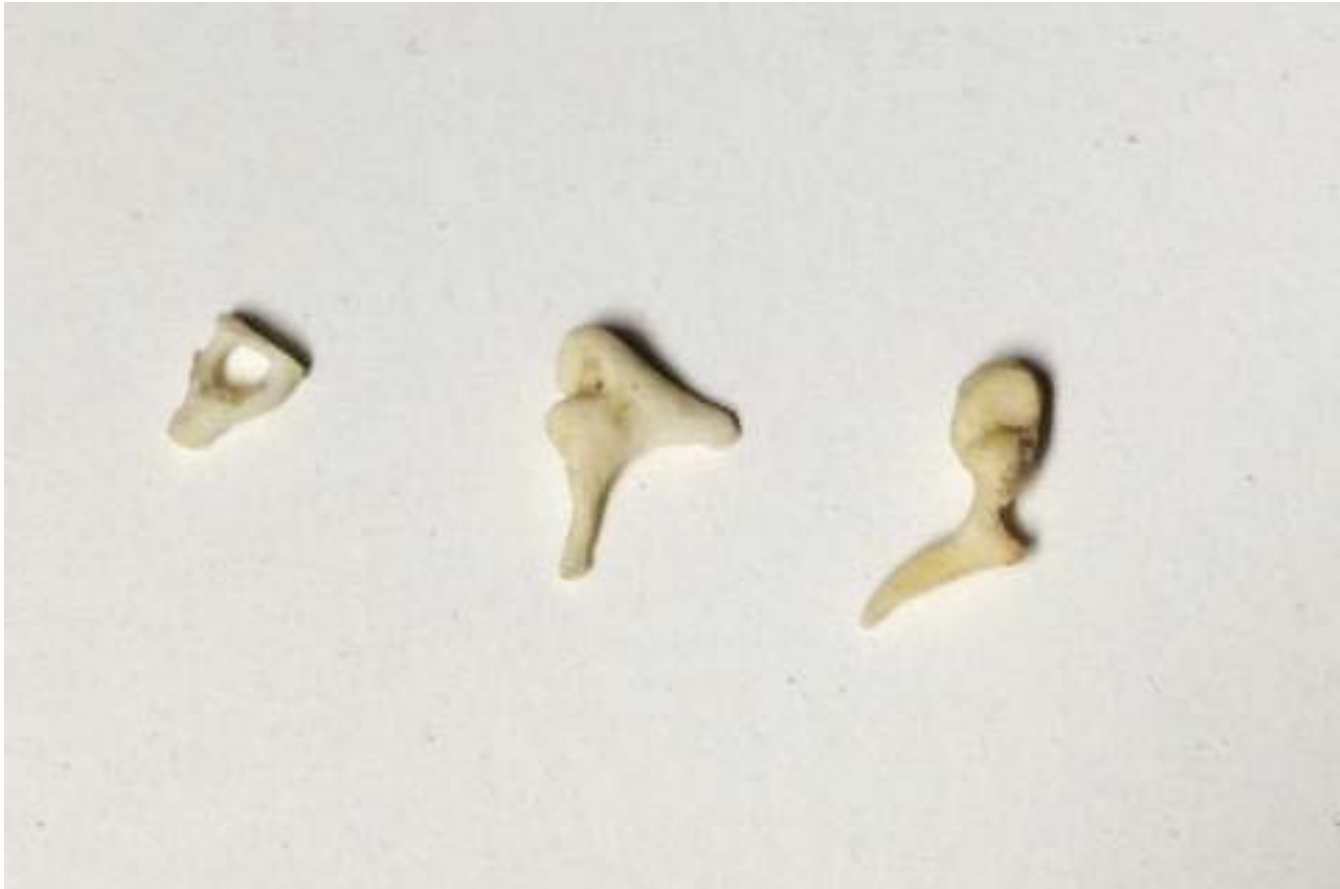Model

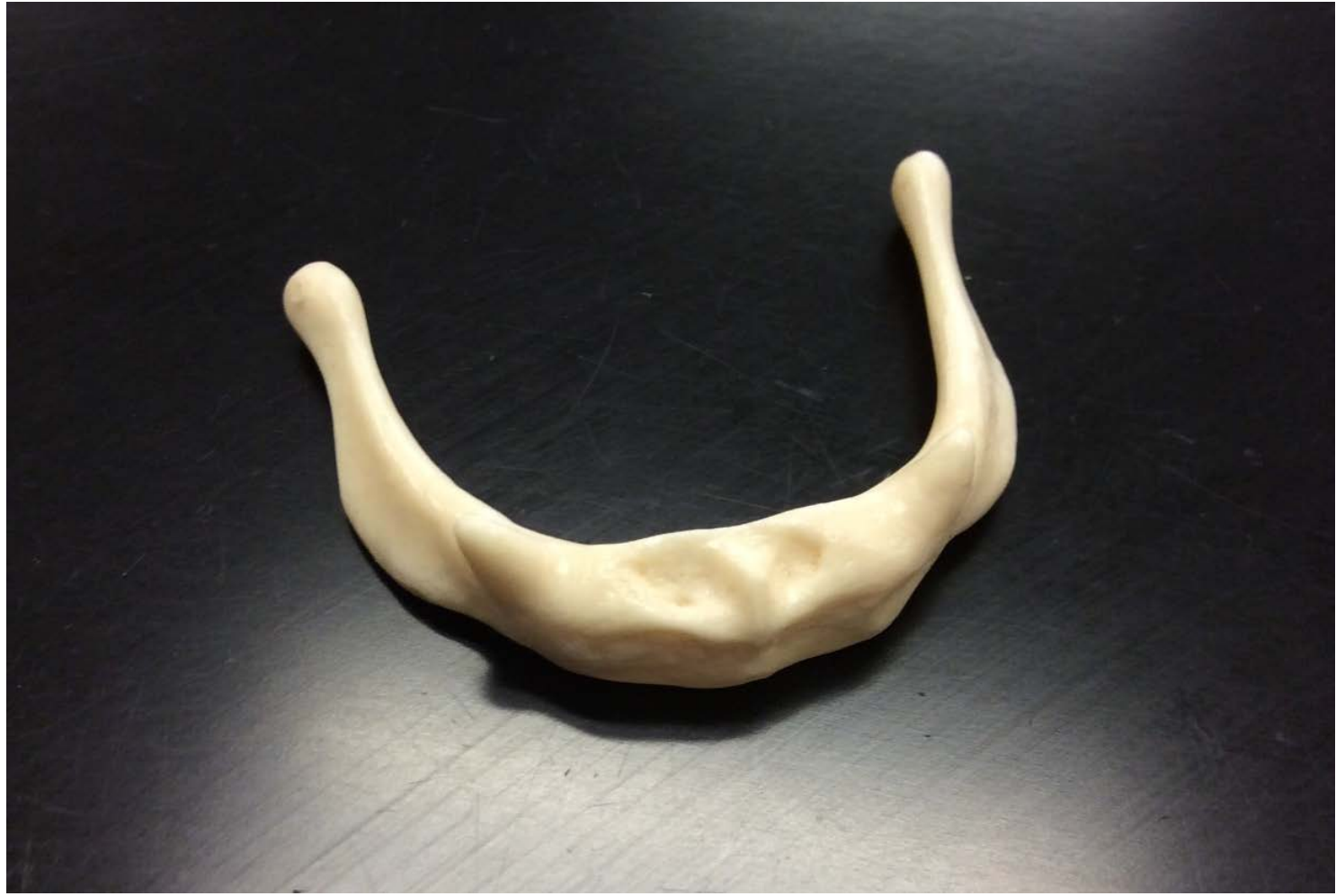





Skull: Bones associated with it...the ossicles  
and hyoid





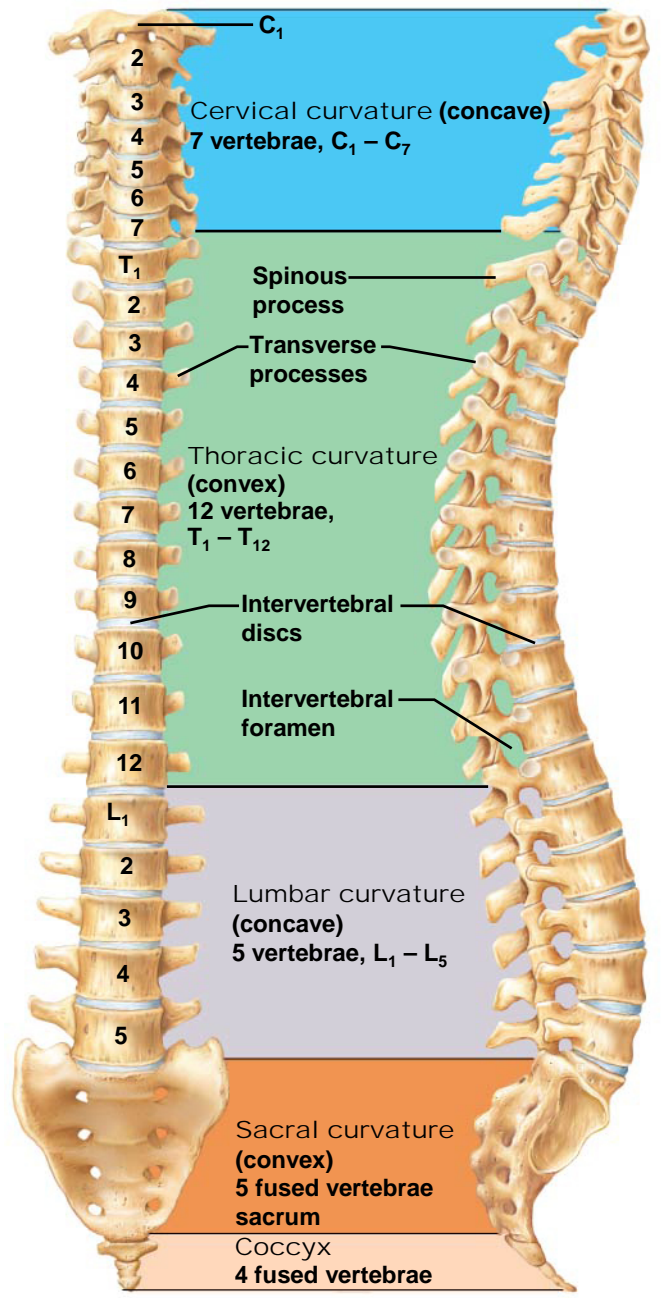
# Use the following pictures to help you identify terms from the lab term handout.

Another good resource is the Visible Body app: <http://skeleton.visiblebody.com>

Don't forget that to use the link to download to a personal device, the device must first be connected to the MCPA Wi-Fi at the Rockville campus.



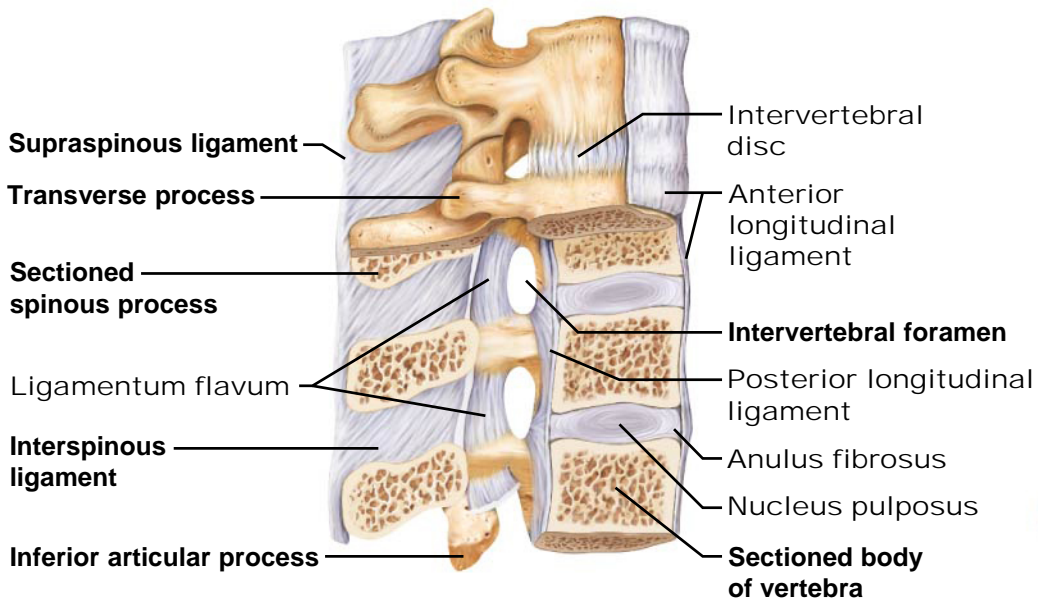
Figure 7.16 The vertebral column.



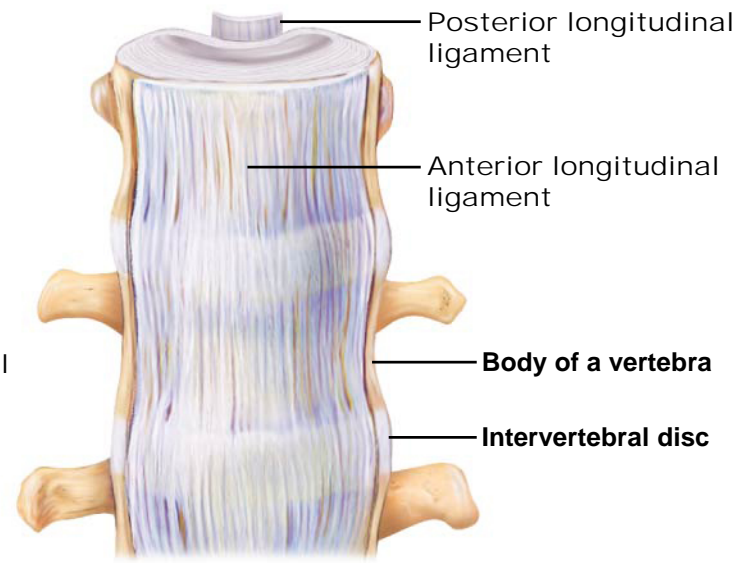
Anterior view

Right lateral view

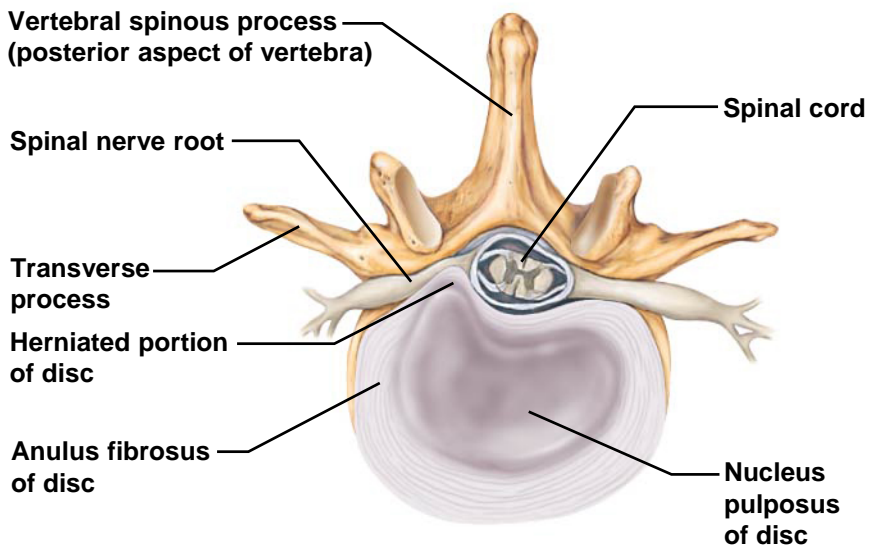
**Figure 7.17 Ligaments and fibrocartilage discs uniting the vertebrae.**



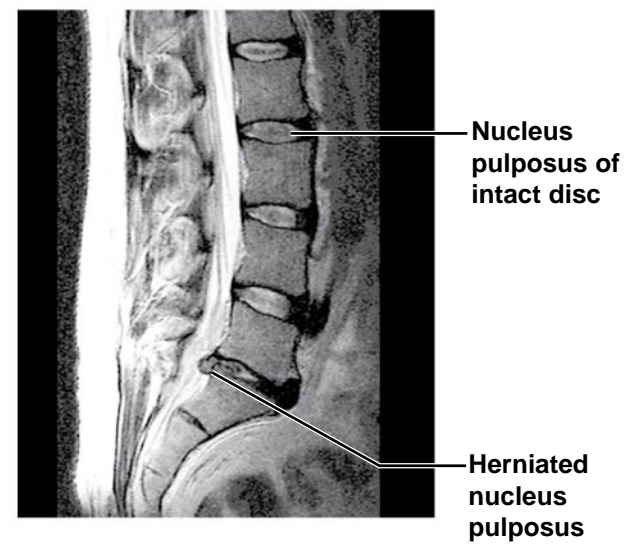
**(a)** Median section of three vertebrae



**(b)** Anterior view of part of the spinal column

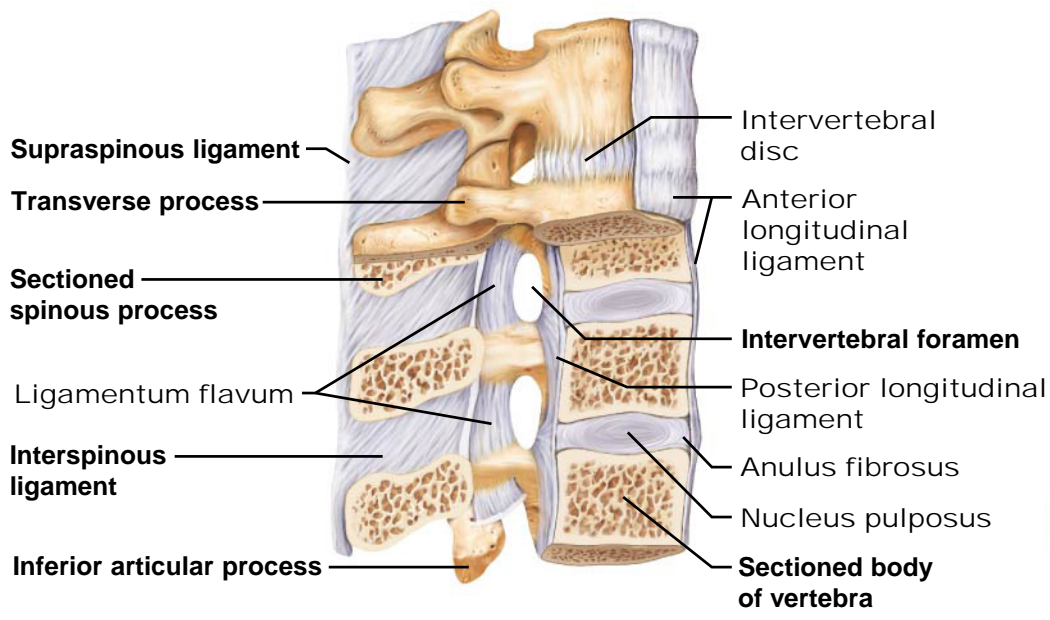


**(c)** Superior view of a herniated intervertebral disc

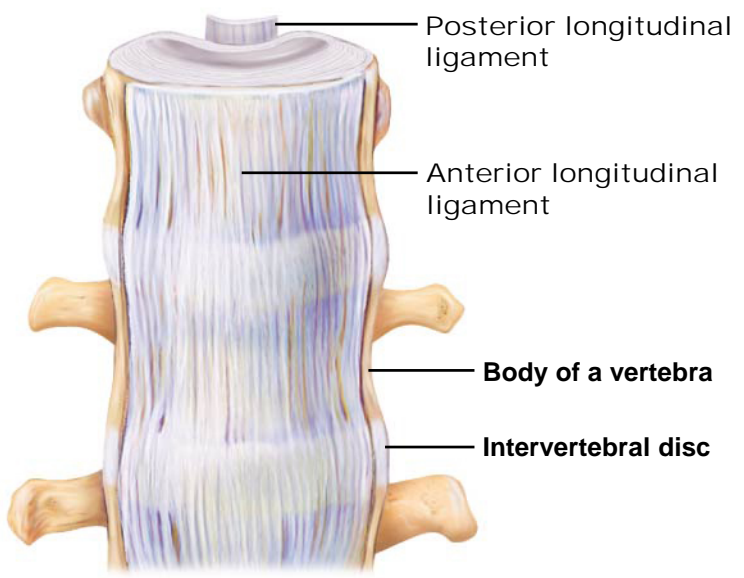


**(d)** MRI of lumbar region of vertebral column in sagittal section showing herniated disc

Figure 7.17a-b Ligaments and fibrocartilage discs uniting the vertebrae.

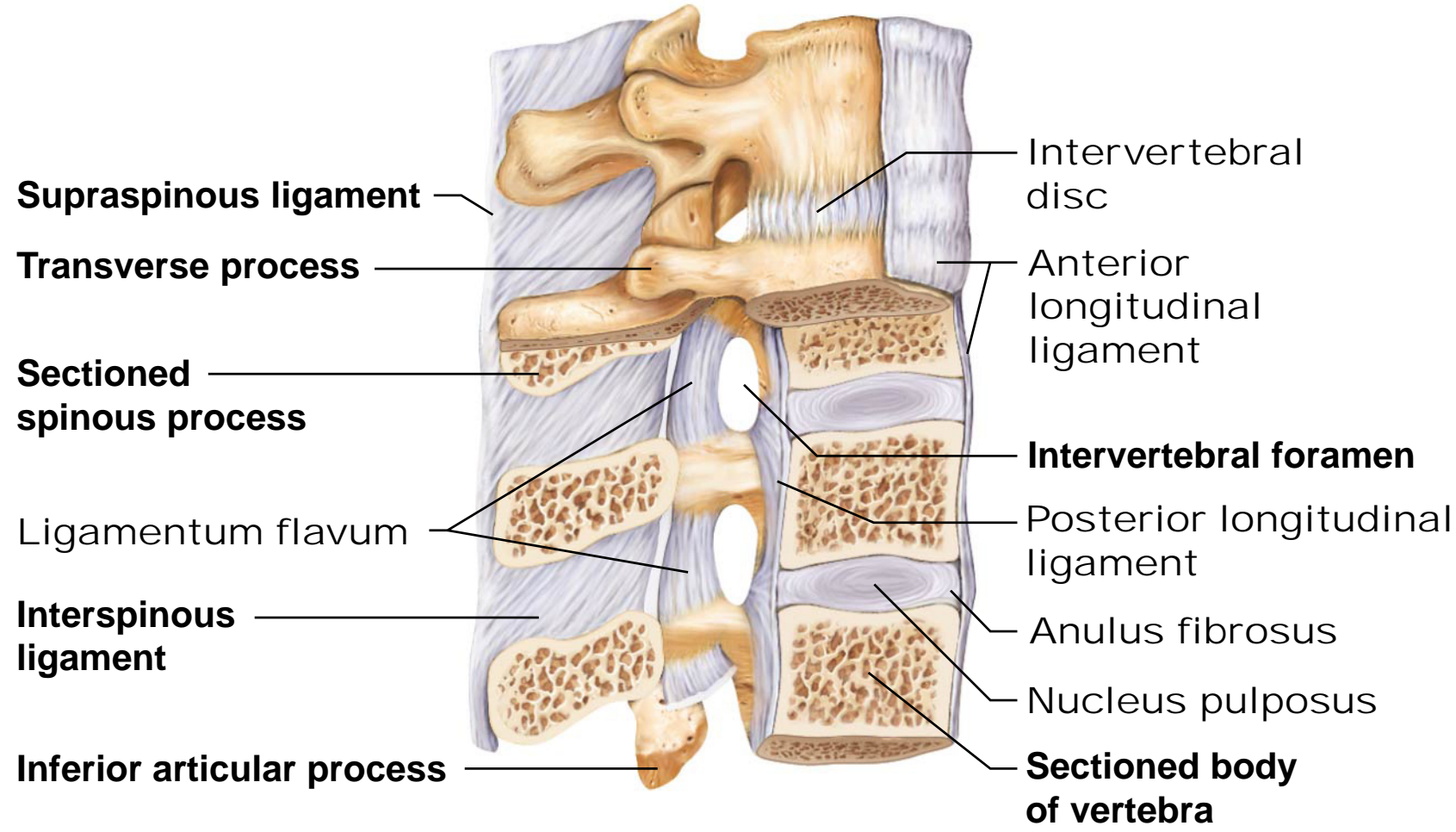


(a) Median section of three vertebrae



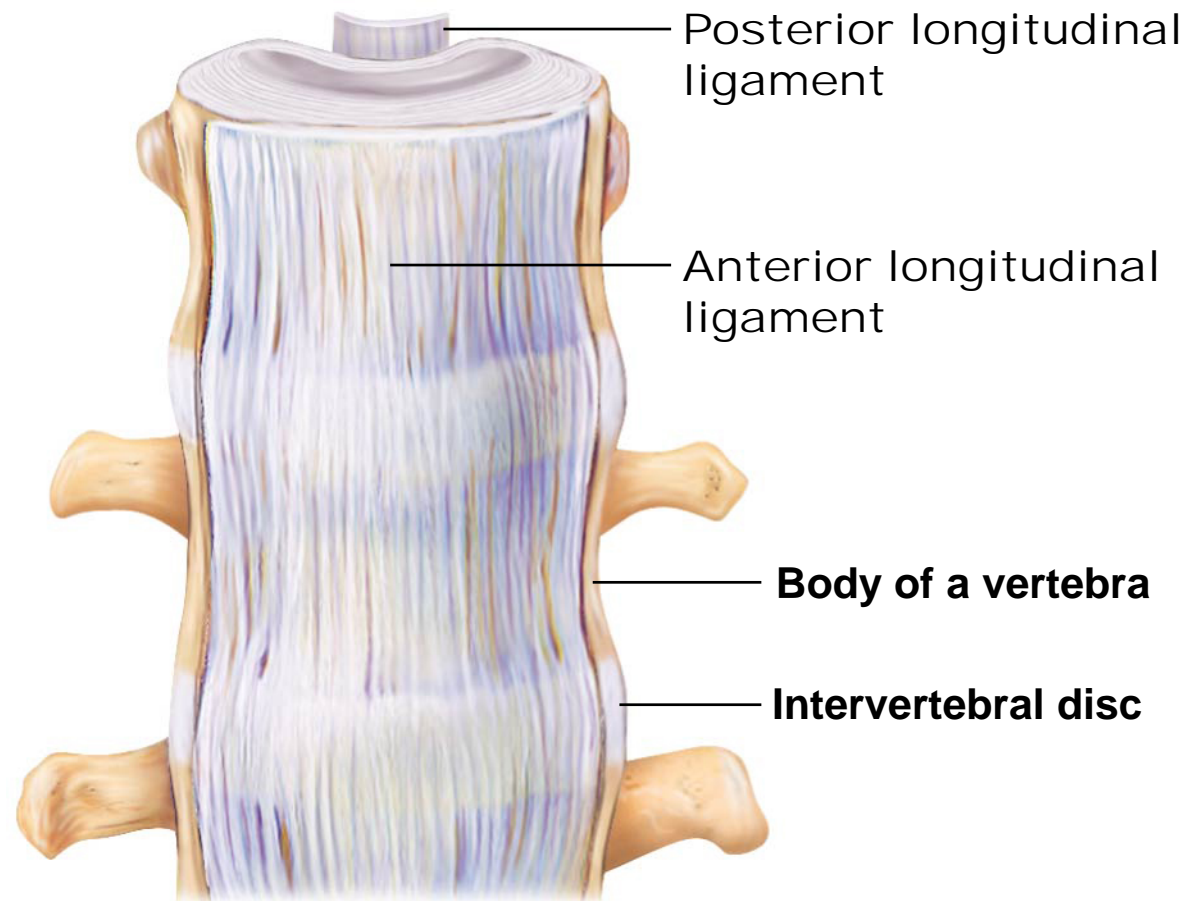
(b) Anterior view of part of the spinal column

Figure 7.17a Ligaments and fibrocartilage discs uniting the vertebrae.



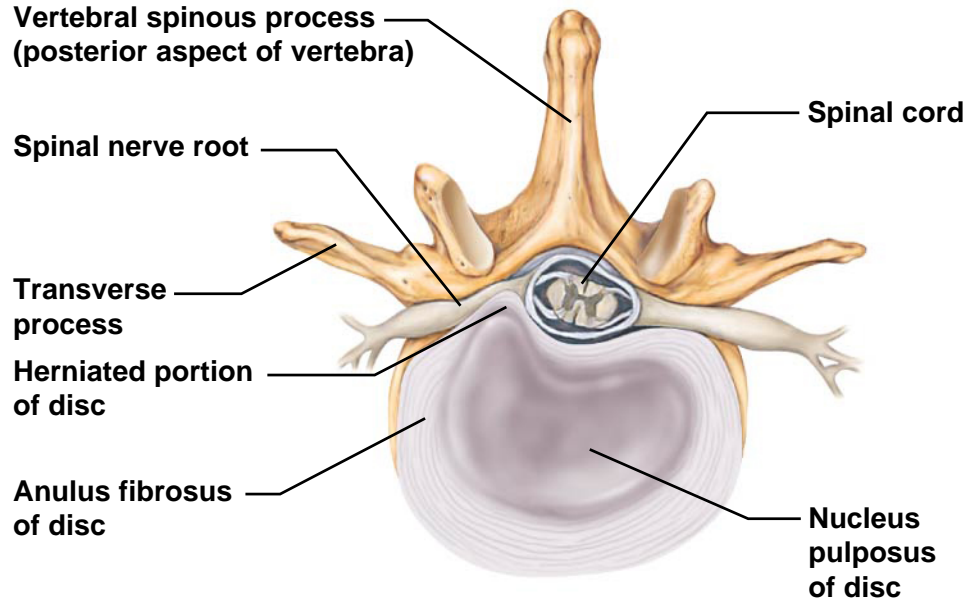
**(a)** Median section of three vertebrae

Figure 7.17b Ligaments and fibrocartilage discs uniting the vertebrae.

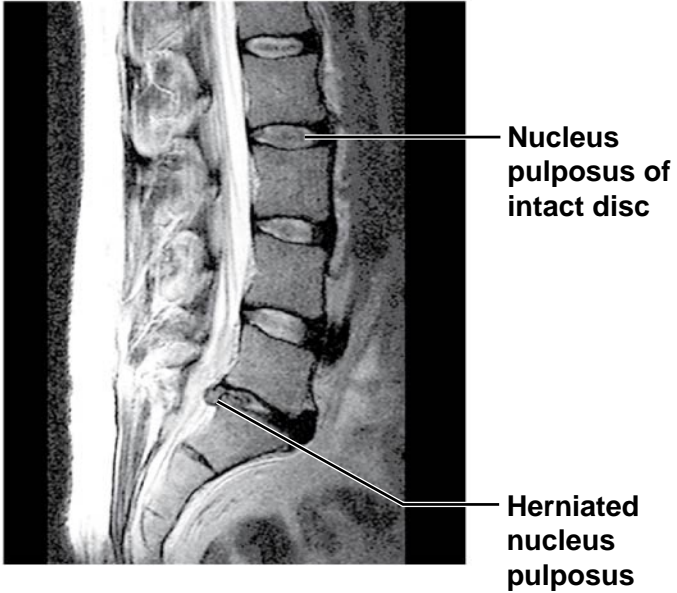


**(b)** Anterior view of part of the spinal column

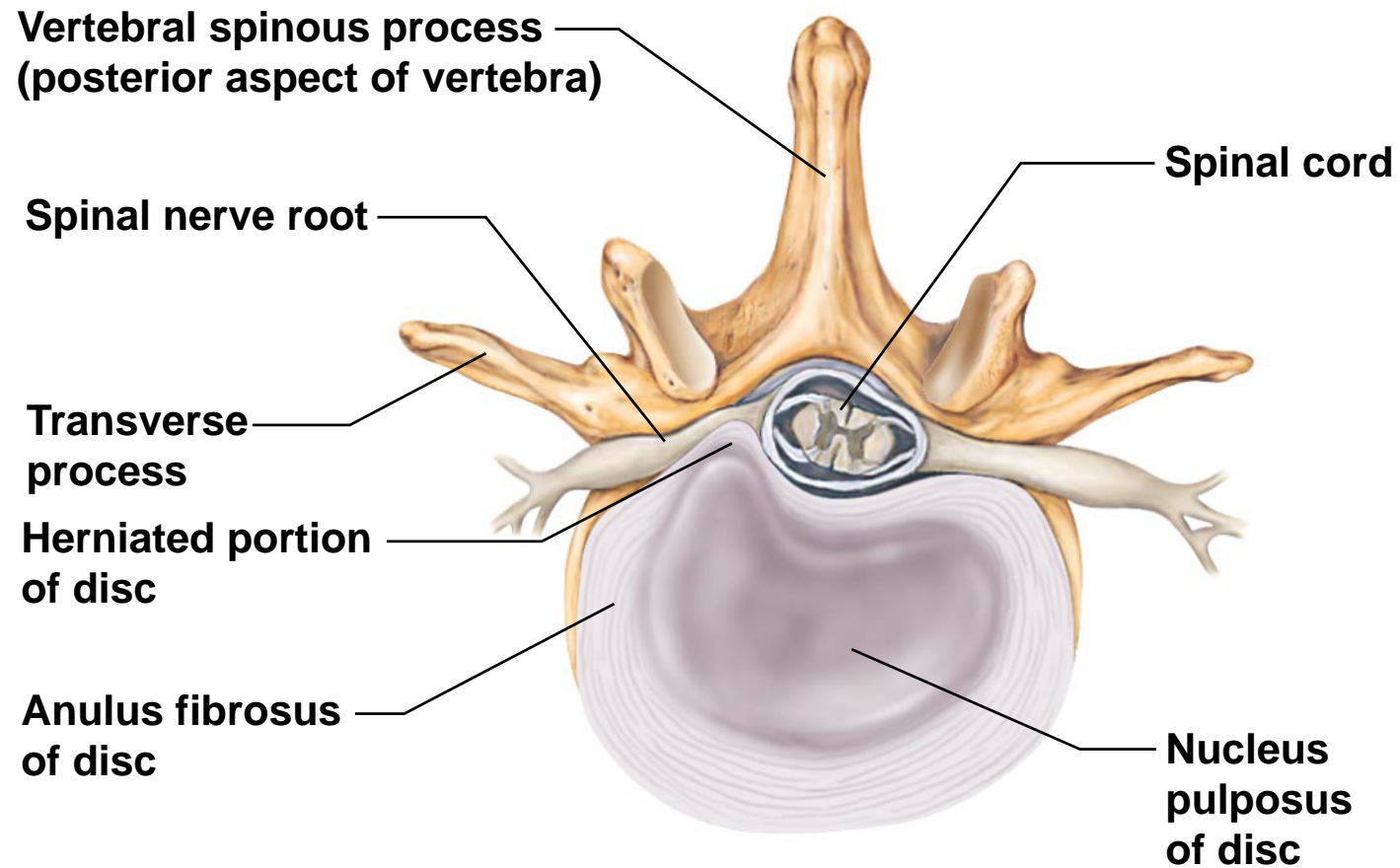
Figure 7.17c-d Ligaments and fibrocartilage discs uniting the vertebrae.



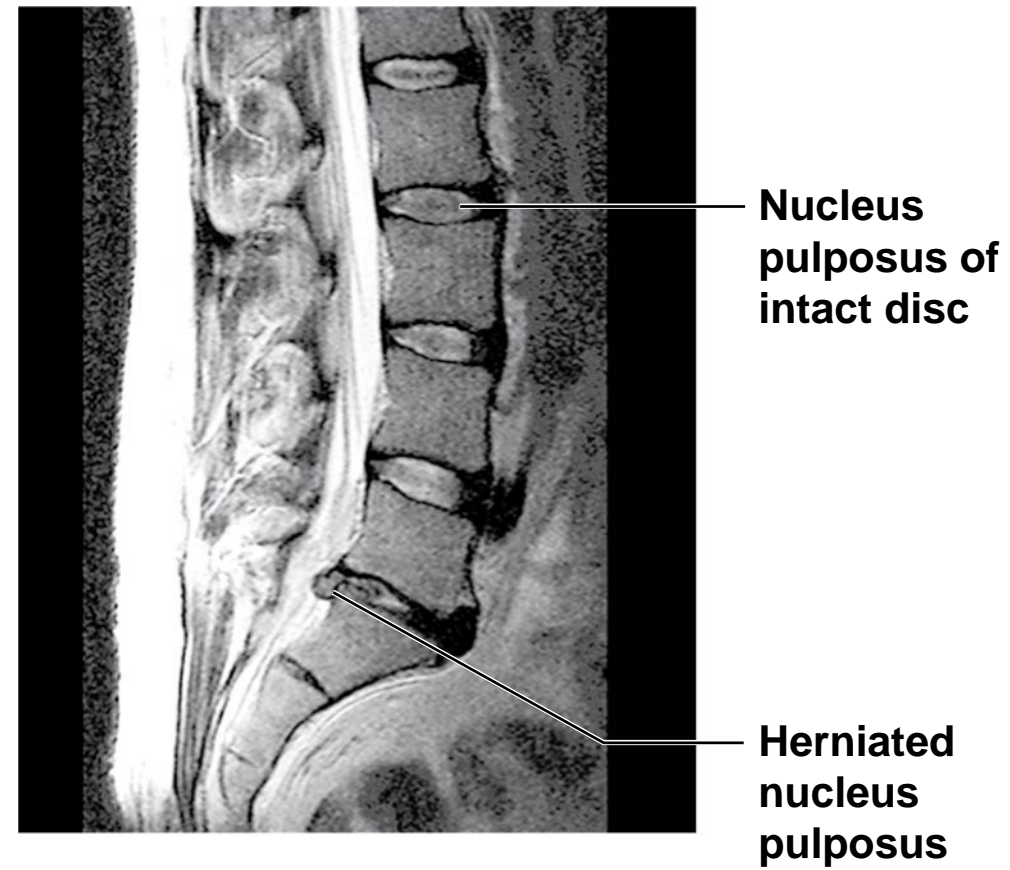
(c) Superior view of a herniated intervertebral disc



(d) MRI of lumbar region of vertebral column in sagittal section showing herniated disc



**(c)** Superior view of a herniated intervertebral disc



**(d)** MRI of lumbar region of vertebral column in sagittal section showing herniated disc



Figure 7.19 Typical vertebral structures.

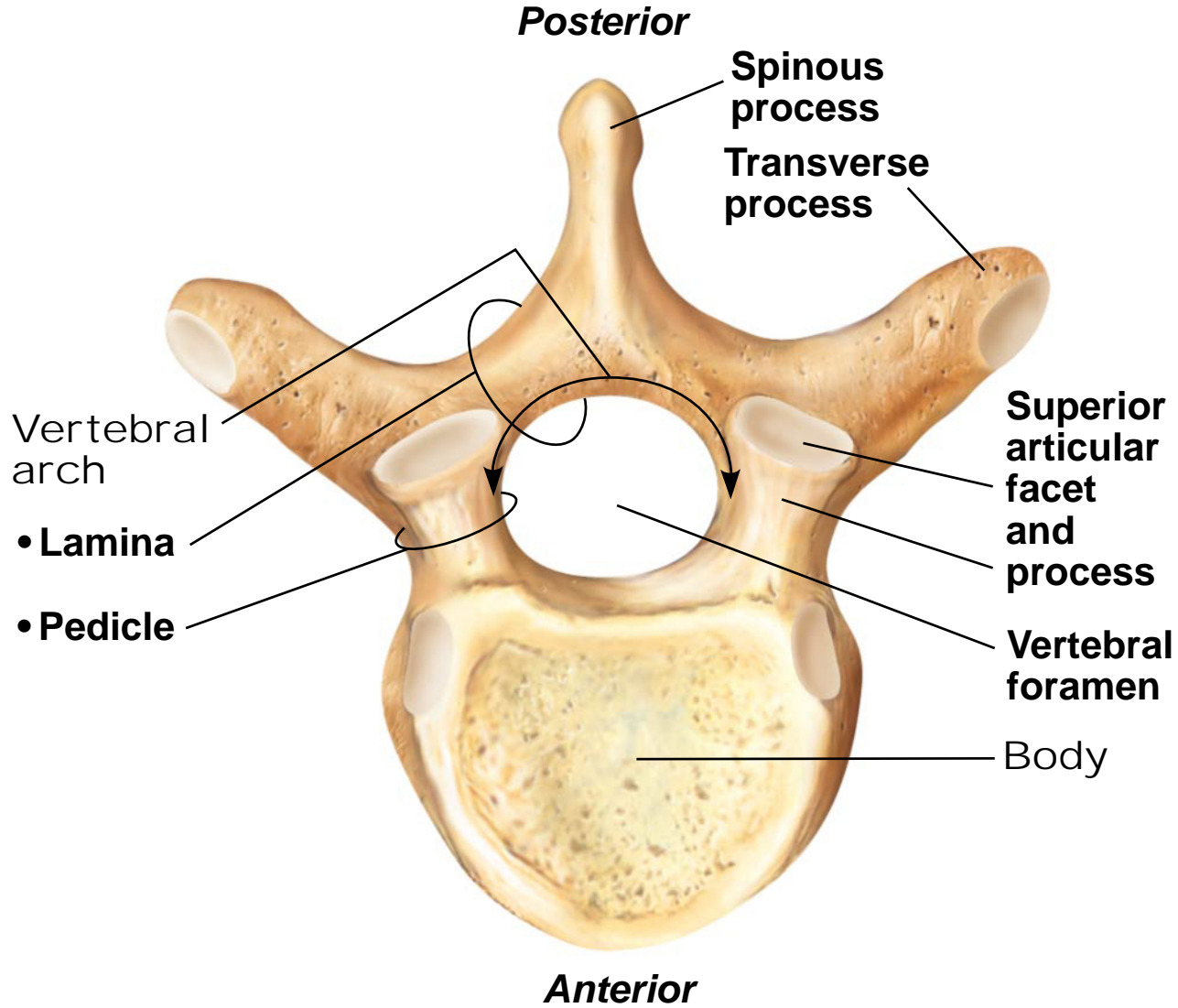
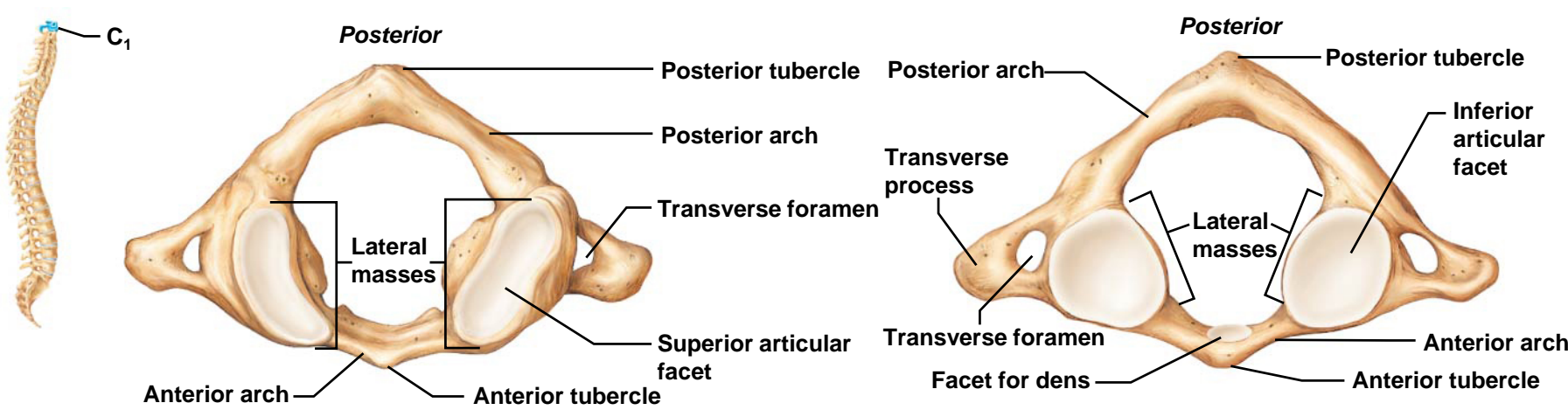
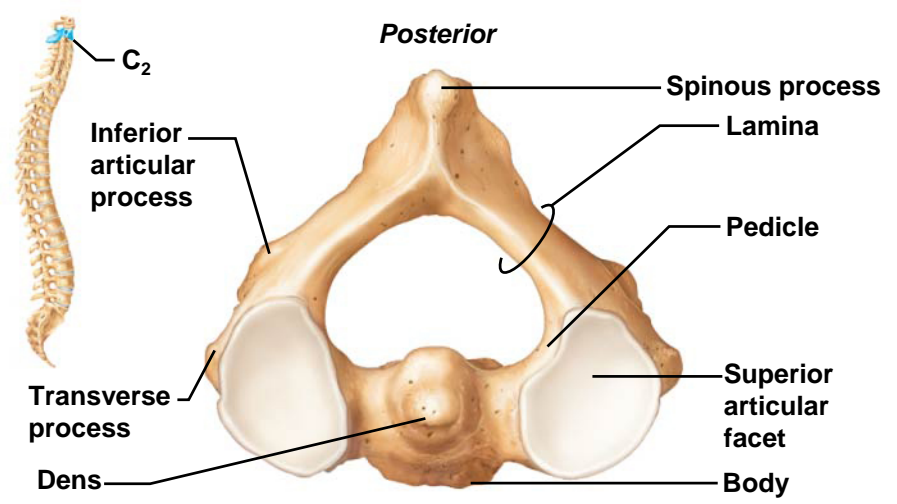


Figure 7.20 The first and second cervical vertebrae.

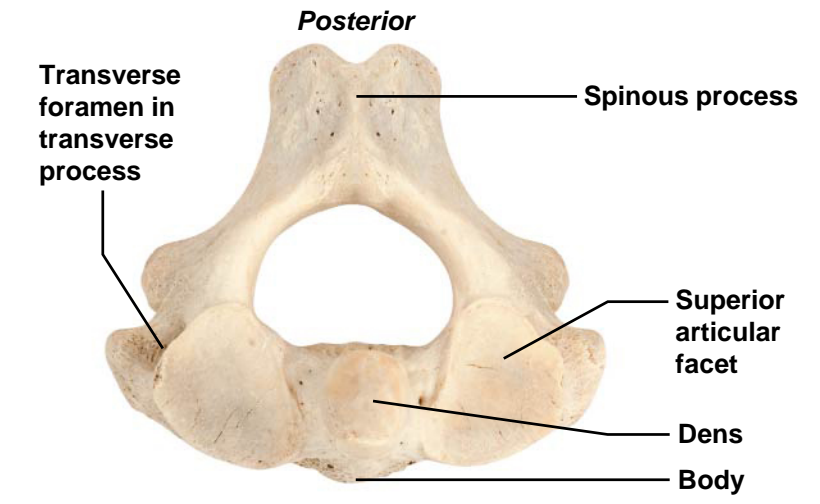


(a) Superior view of atlas (C<sub>1</sub>)

(b) Inferior view of atlas (C<sub>1</sub>)

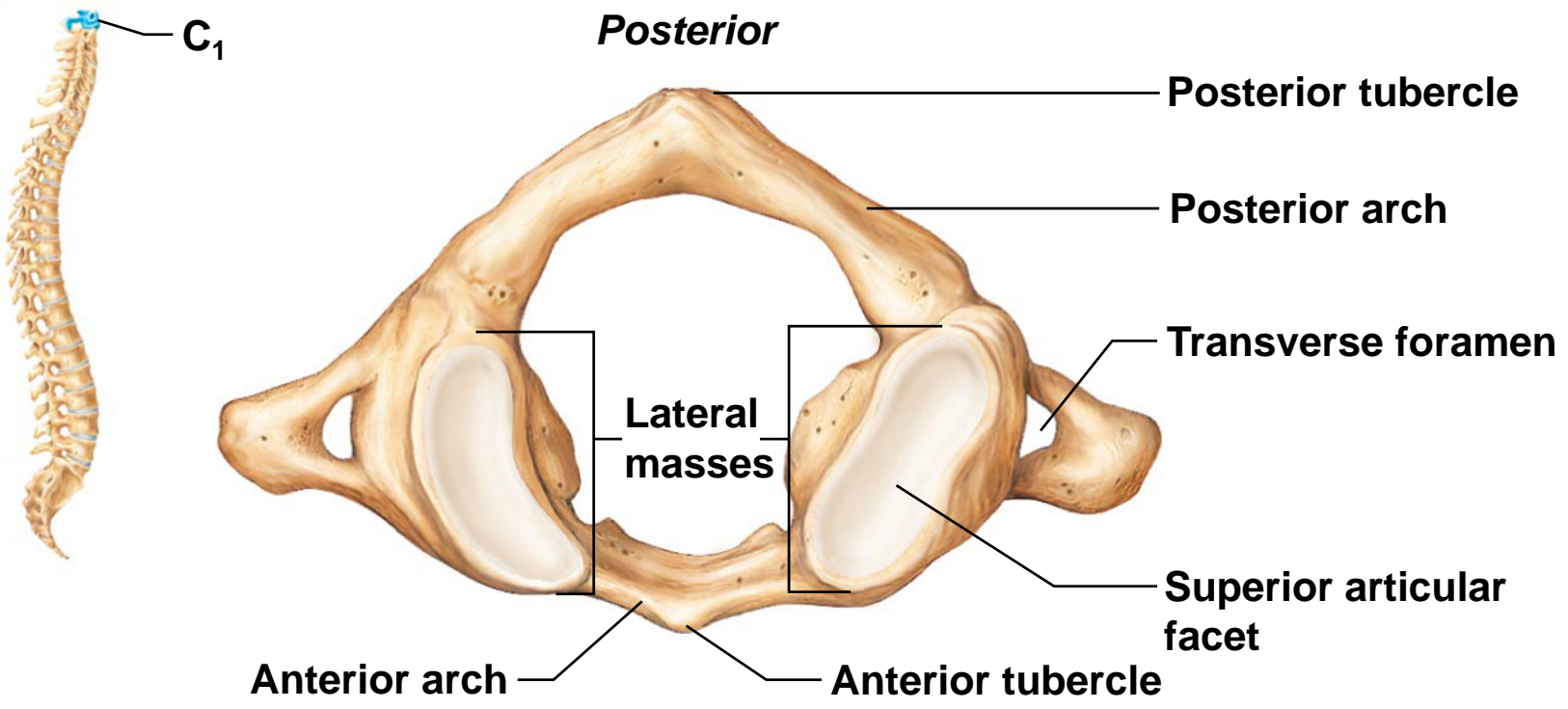


(c) Superior view of axis (C<sub>2</sub>)



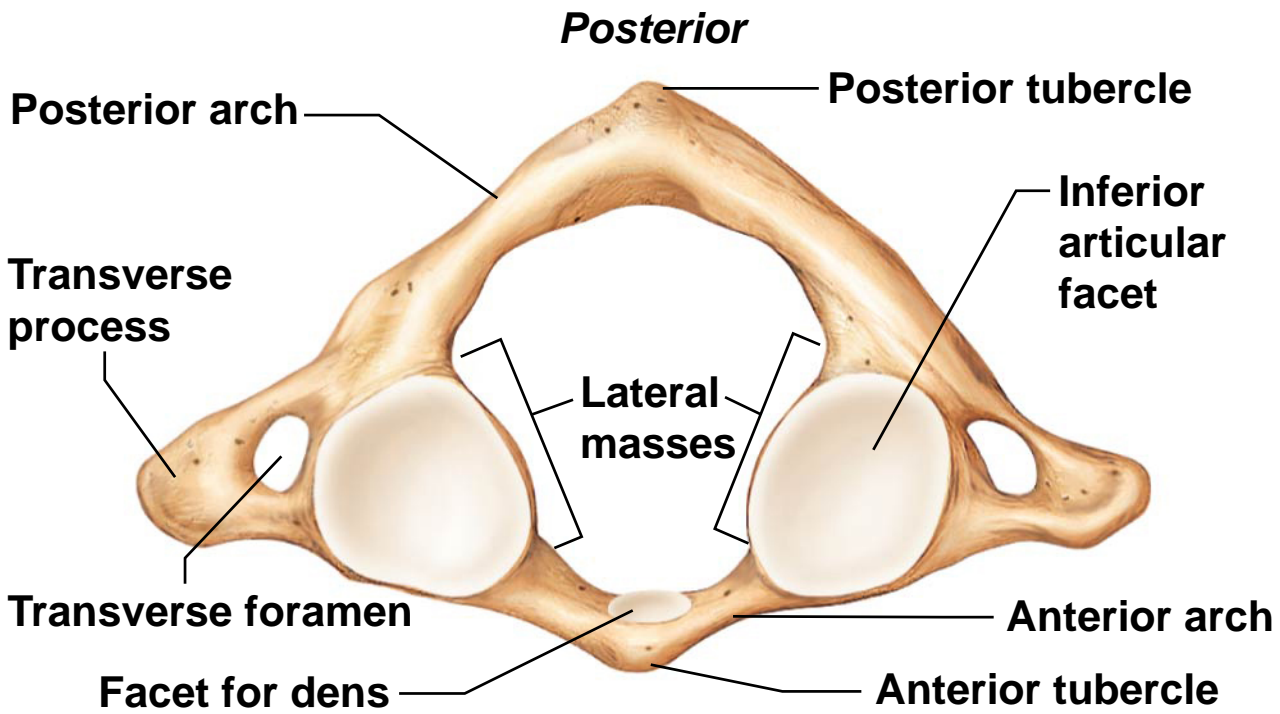
(d) Photo of axis (C<sub>2</sub>), superior view

Figure 7.20a The first and second cervical vertebrae.



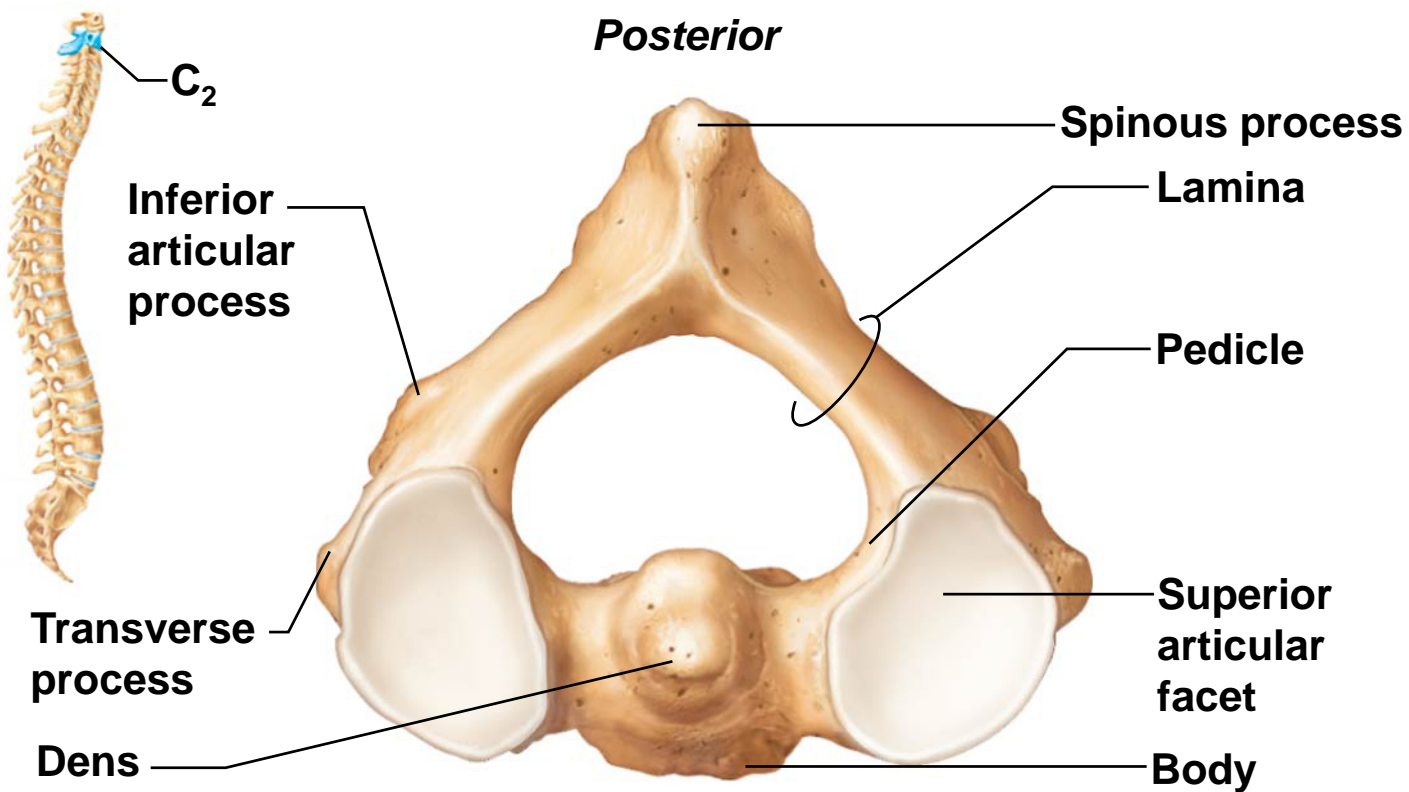
**(a)** Superior view of atlas (C<sub>1</sub>)

Figure 7.20b The first and second cervical vertebrae.

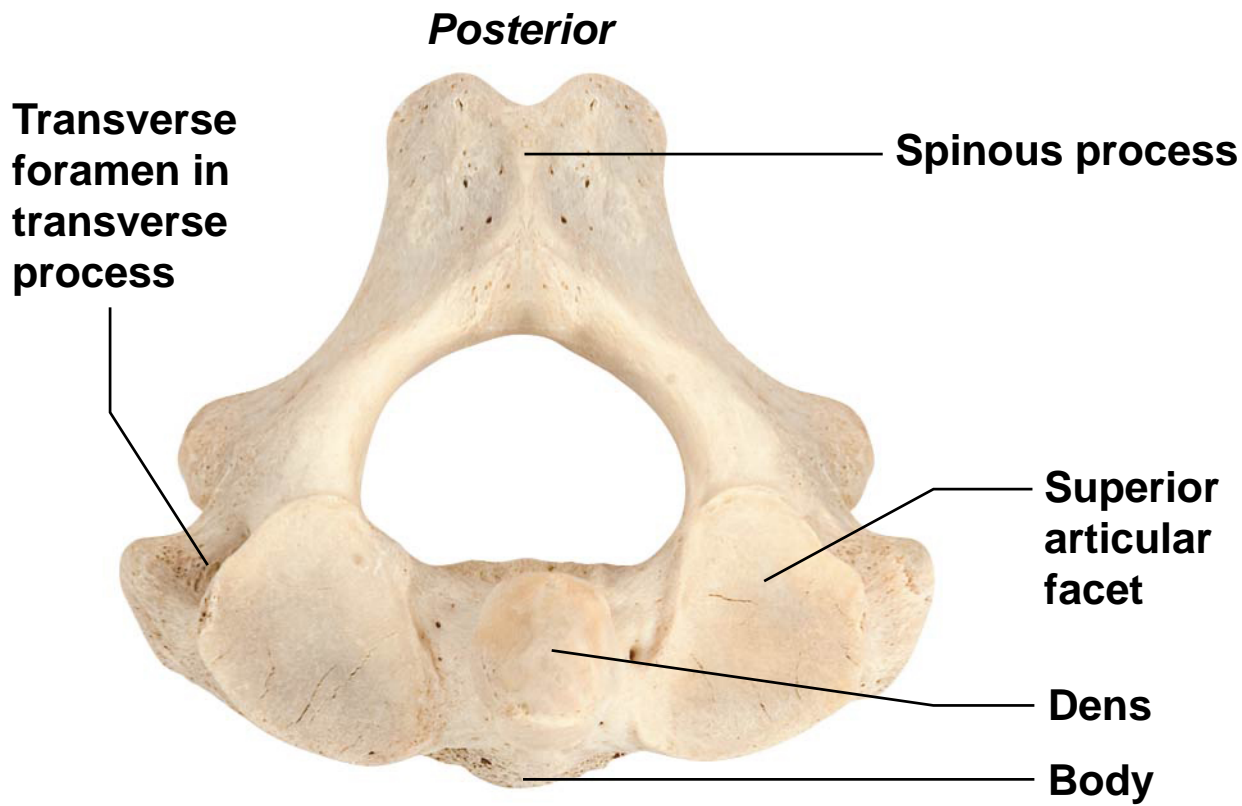


**(b)** Inferior view of atlas (C<sub>1</sub>)

Figure 7.20c The first and second cervical vertebrae.

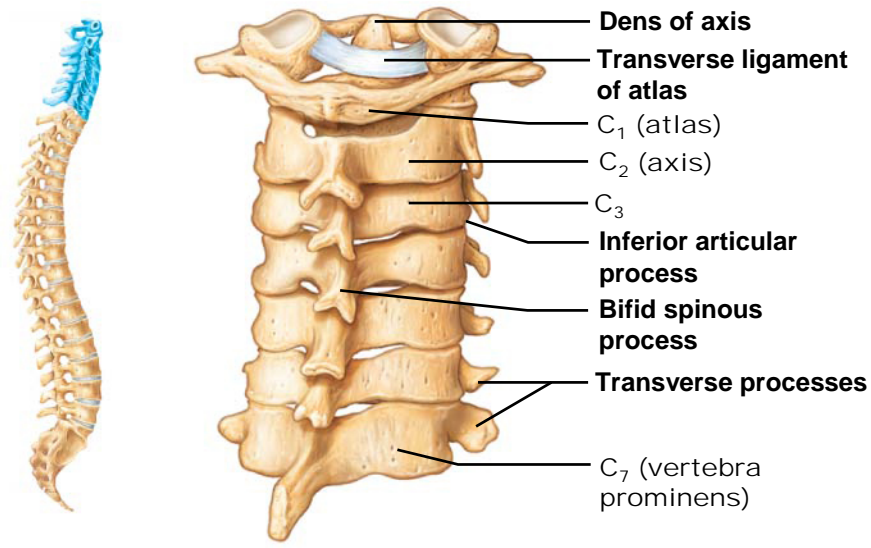


**(c)** Superior view of axis (C<sub>2</sub>)

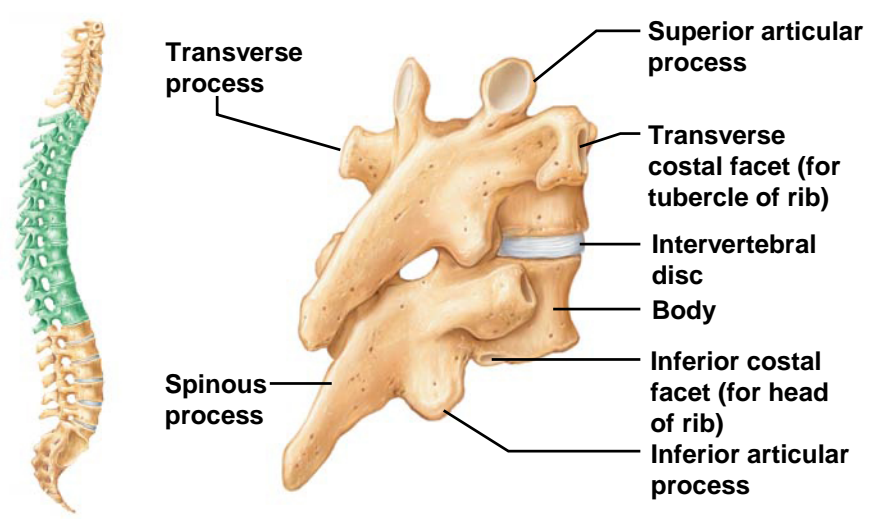


**(d)** Photo of axis (C<sub>2</sub>), superior view

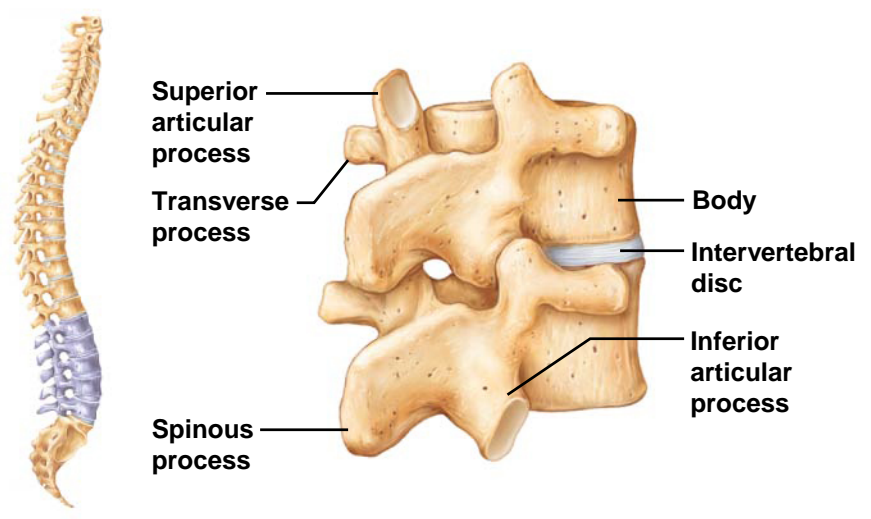
Figure 7.21 Posterolateral views of articulated vertebrae.



(a) Cervical vertebrae

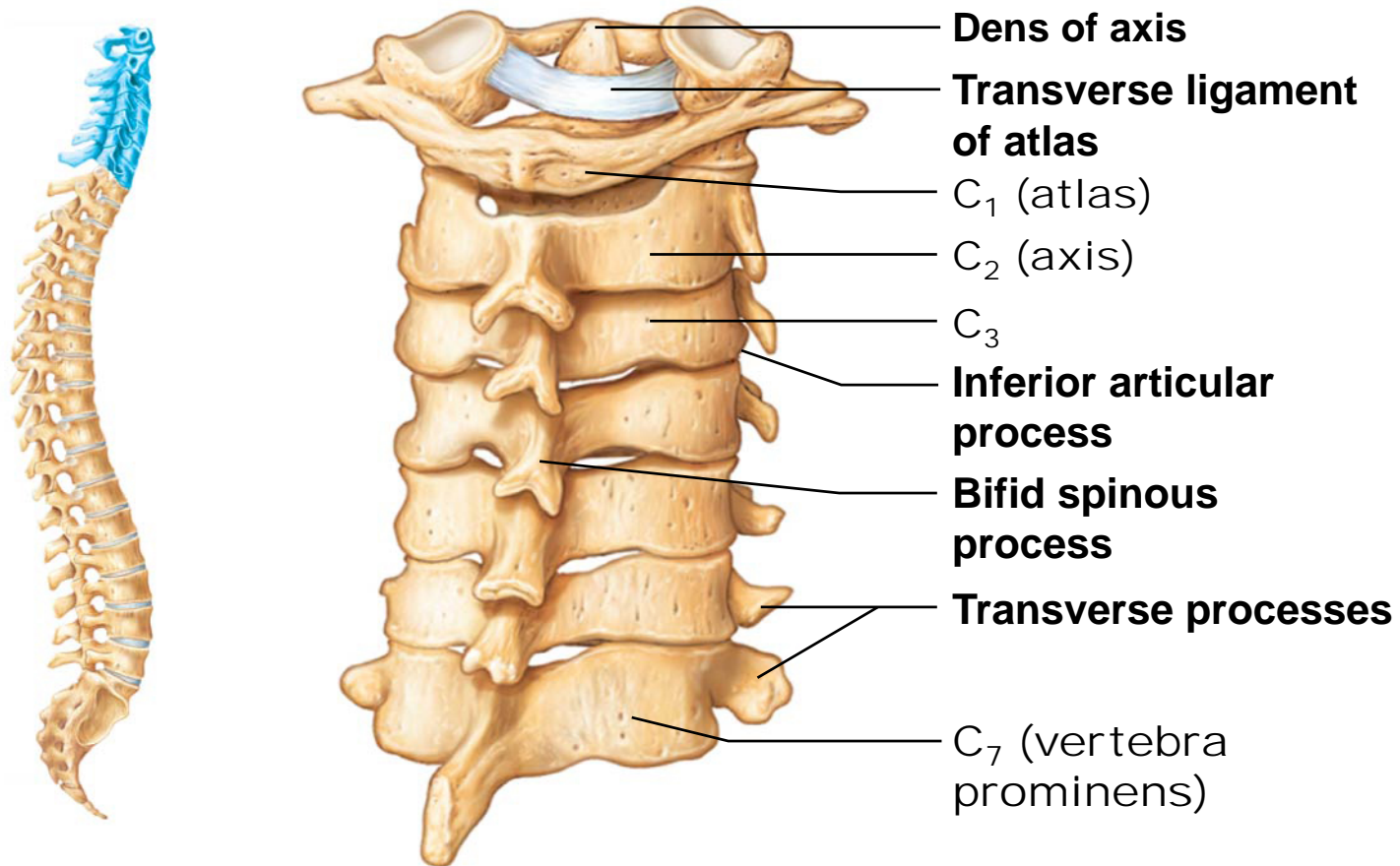


(b) Thoracic vertebrae



(c) Lumbar vertebrae

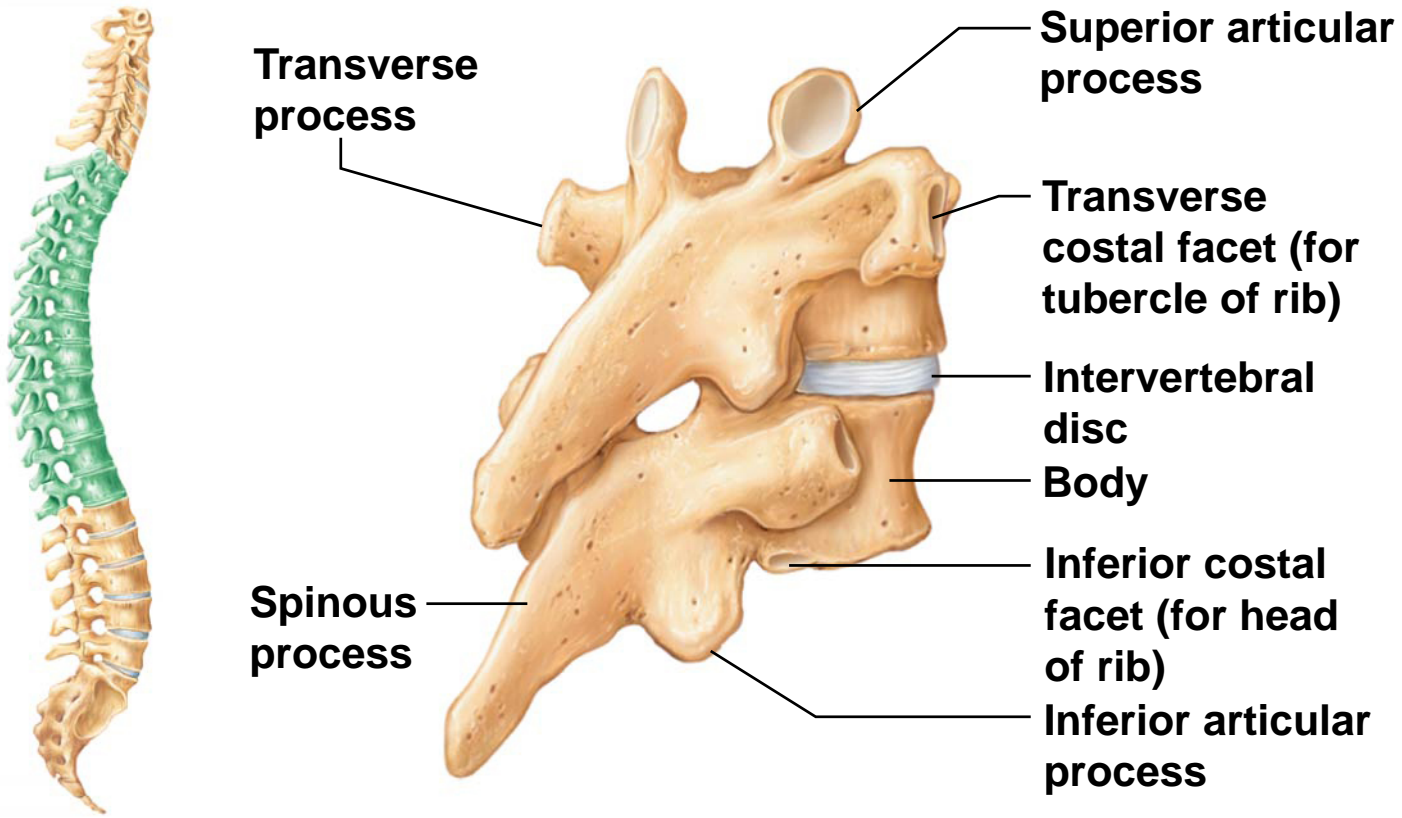
Figure 7.21a Posterolateral views of articulated vertebrae.



**(a)** Cervical vertebrae

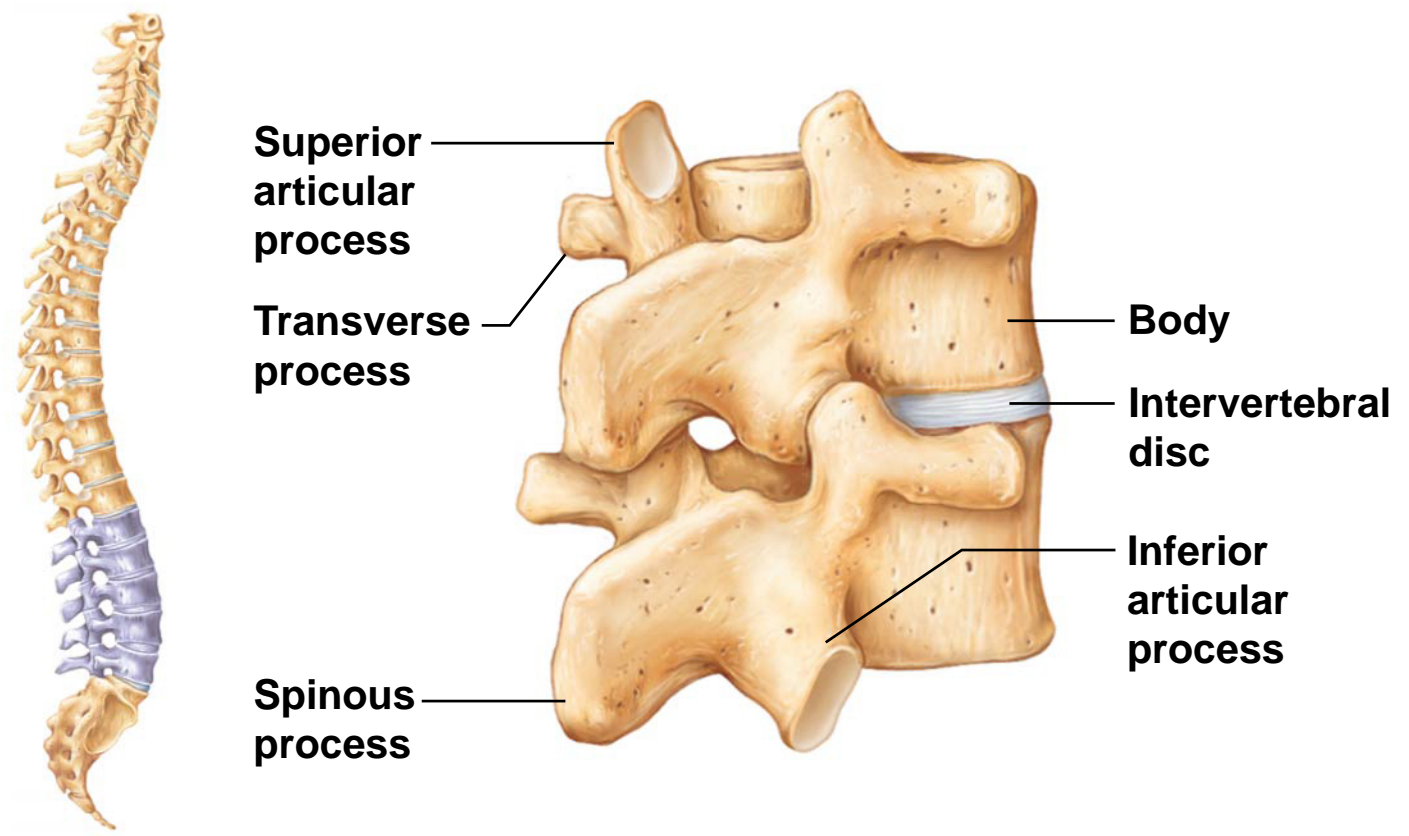


Figure 7.21b Posterolateral views of articulated vertebrae.



**(b)** Thoracic vertebrae

Figure 7.21c Posterolateral views of articulated vertebrae.



**(c)** Lumbar vertebrae

Table 7.2-1 Regional Characteristics of Cervical, Thoracic, and Lumbar Vertebrae

<b>Table 7.2</b>		<b>Regional Characteristics of Cervical, Thoracic, and Lumbar Vertebrae</b>		
<b>CHARACTERISTIC</b>	<b>CERVICAL (3–7)</b>	<b>THORACIC</b>	<b>LUMBAR</b>	
Body	Small, oval, wide side to side	Larger than cervical; heart shaped; bears two costal facets	Massive; kidney shaped	
Spinous process	Short; bifid (except C <sub>7</sub> ); projects directly posterior	Long; sharp; projects inferiorly	Short; blunt; rectangular; projects directly posteriorly	
Vertebral foramen	Triangular, large	Circular	Triangular	
Transverse processes	Contain foramina	Bear facets for ribs (except T <sub>11</sub> and T <sub>12</sub> )	Thin and tapered	
Superior and inferior articular processes	Superior facets directed superoposteriorly	Superior facets directed posteriorly	Superior facets directed posteromedially (or medially)	
	Inferior facets directed inferoanteriorly	Inferior facets directed anteriorly	Inferior facets directed anterolaterally (or laterally)	
Movements allowed	Flexion and extension; lateral flexion; rotation; the spine region with the greatest range of movement	Rotation; lateral flexion possible but restricted by ribs; flexion and extension limited	Flexion and extension; some lateral flexion; rotation prevented	

**Table 7.2** Regional Characteristics of Cervical, Thoracic, and Lumbar Vertebrae (continued)

CHARACTERISTIC	CERVICAL (3-7)	THORACIC	LUMBAR
----------------	----------------	----------	--------

**Superior View**

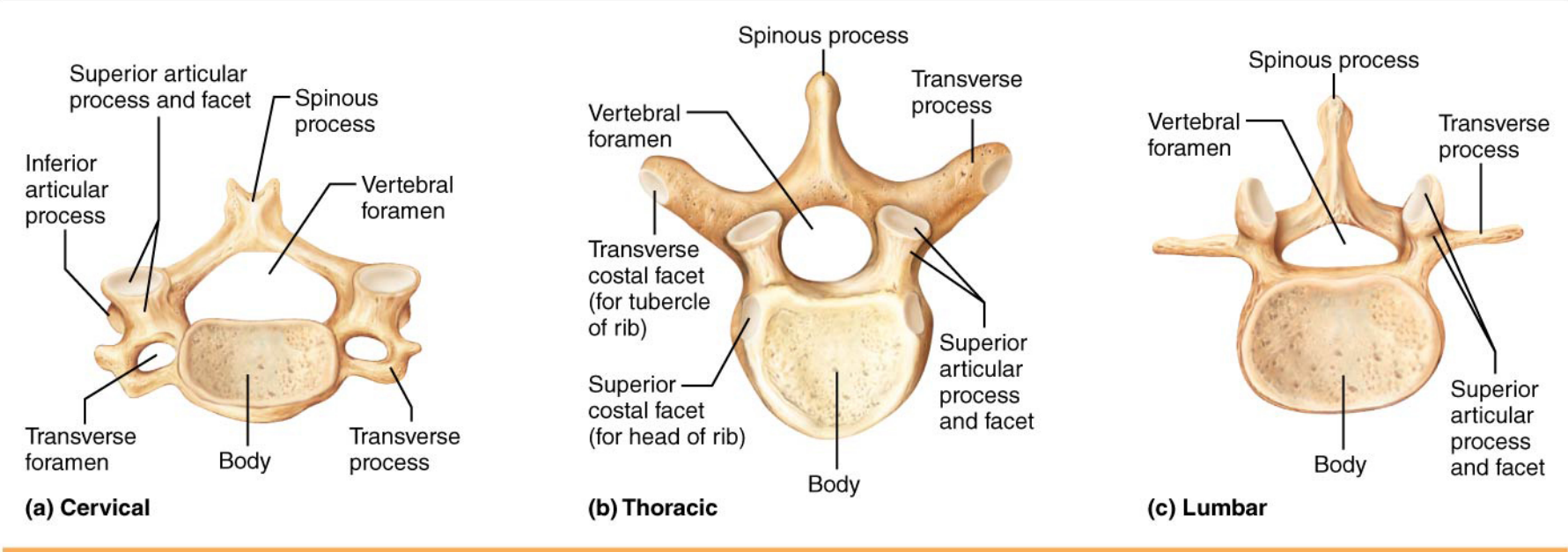


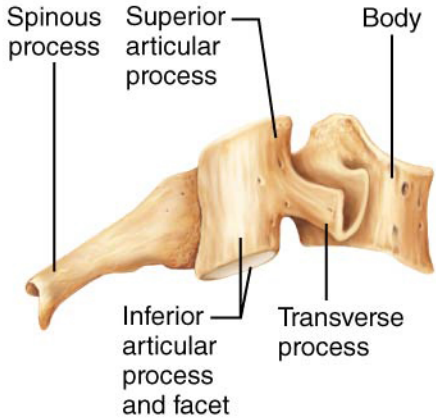
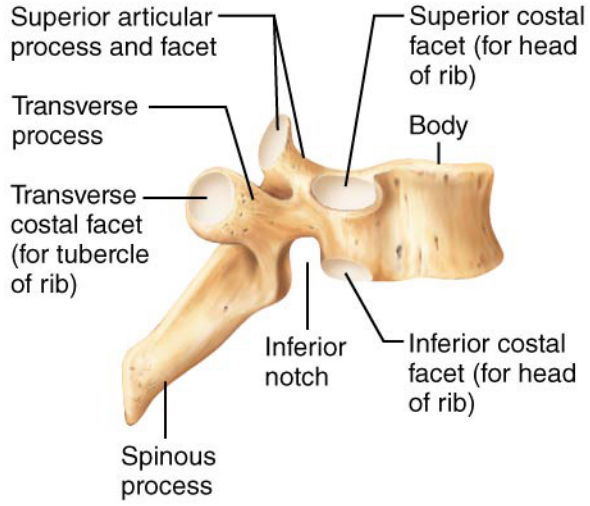
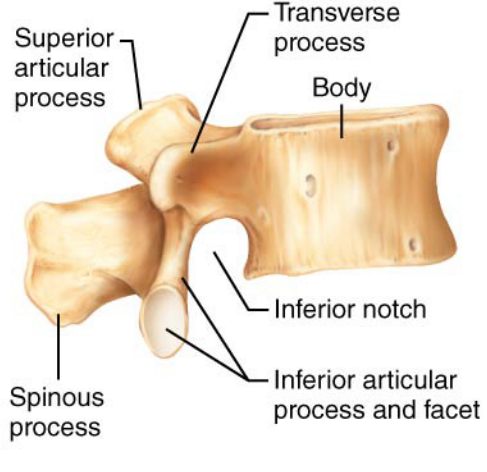
Table 7.2 Regional Characteristics of Cervical, Thoracic, and Lumbar Vertebrae (continued)			
CHARACTERISTIC	CERVICAL (3-7)	THORACIC	LUMBAR
<b>Right Lateral View</b>			
	 <p>(a) Cervical</p>	 <p>(b) Thoracic</p>	 <p>(c) Lumbar</p>

Figure 7.22 The sacrum and coccyx.

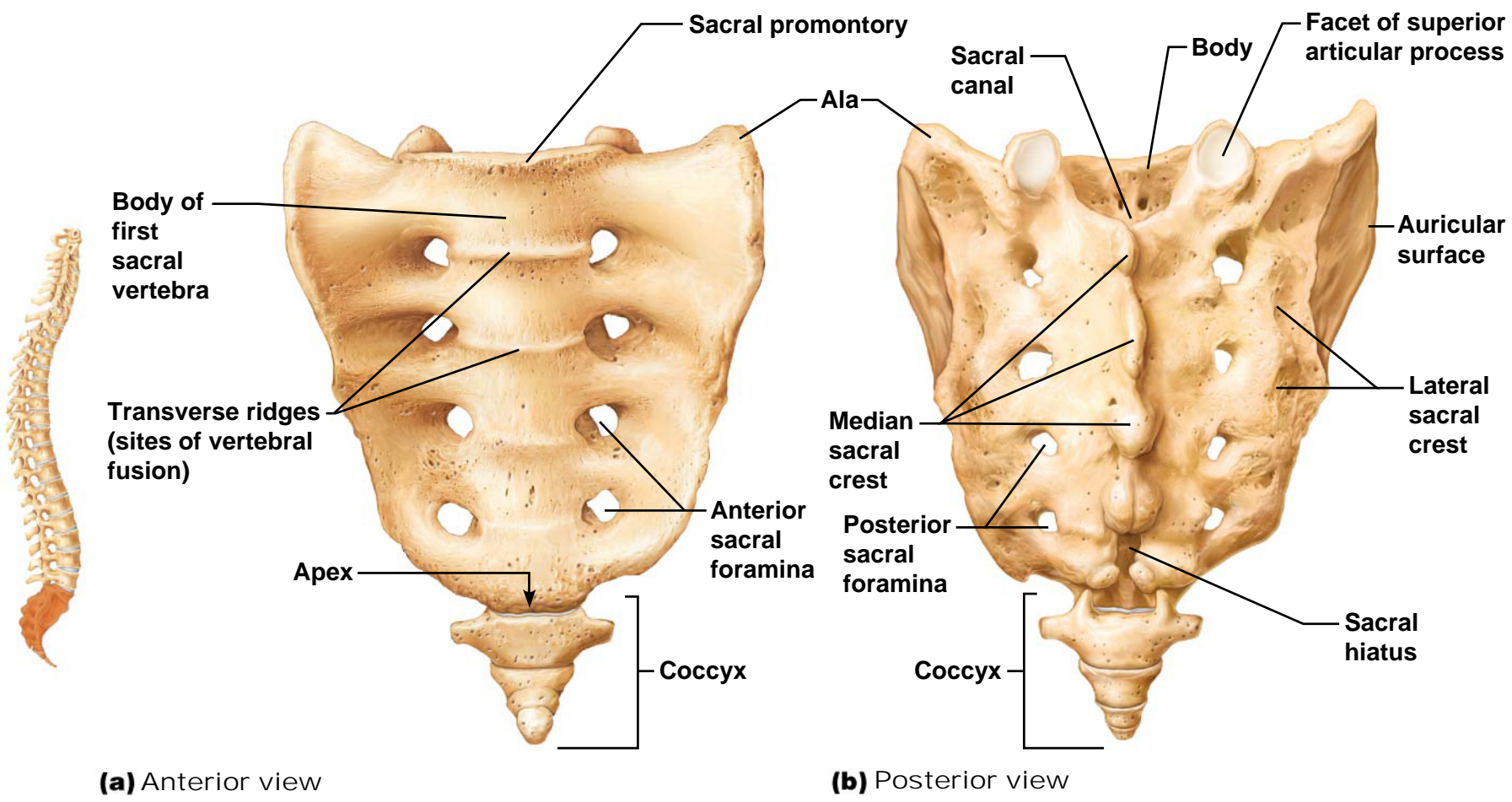
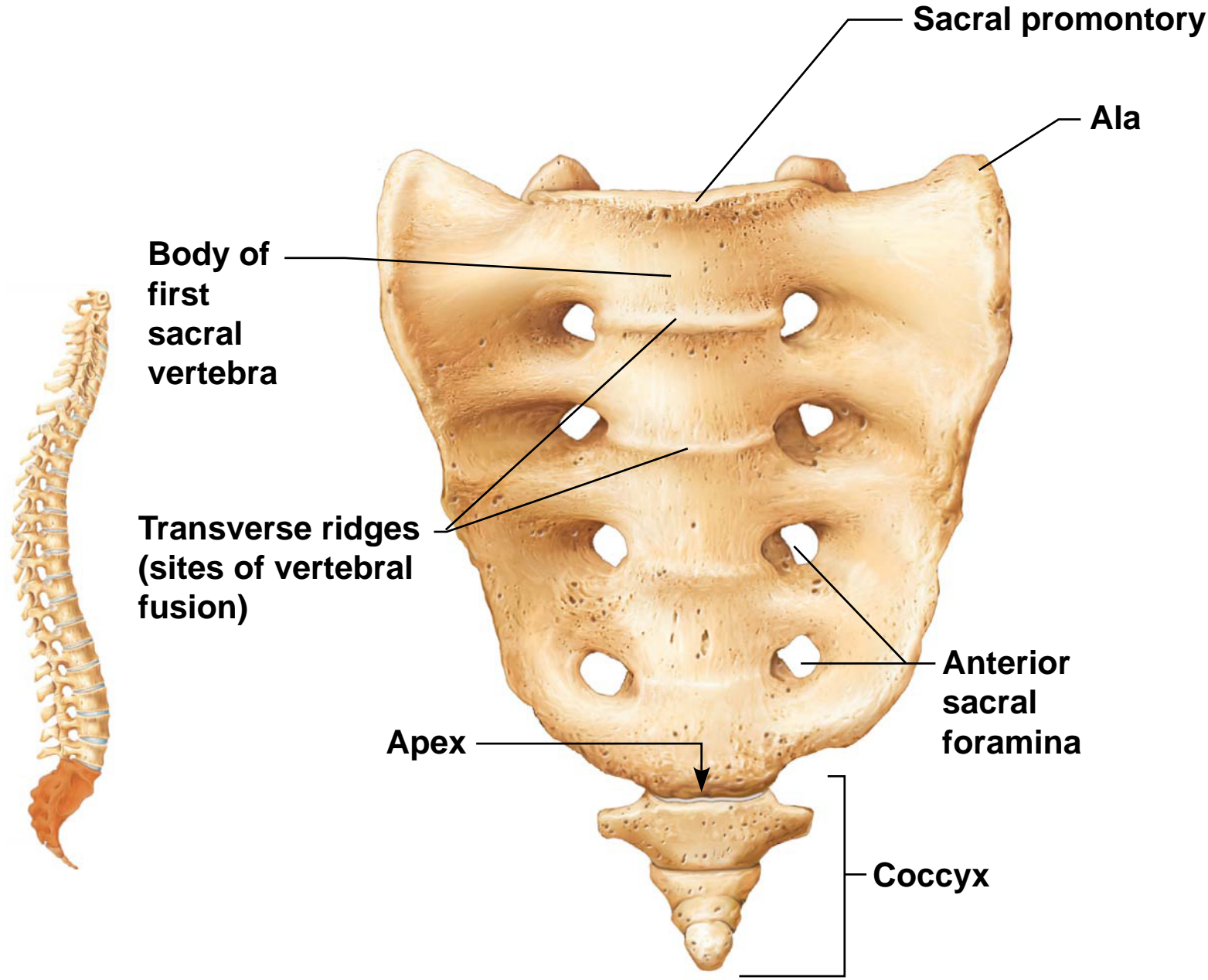
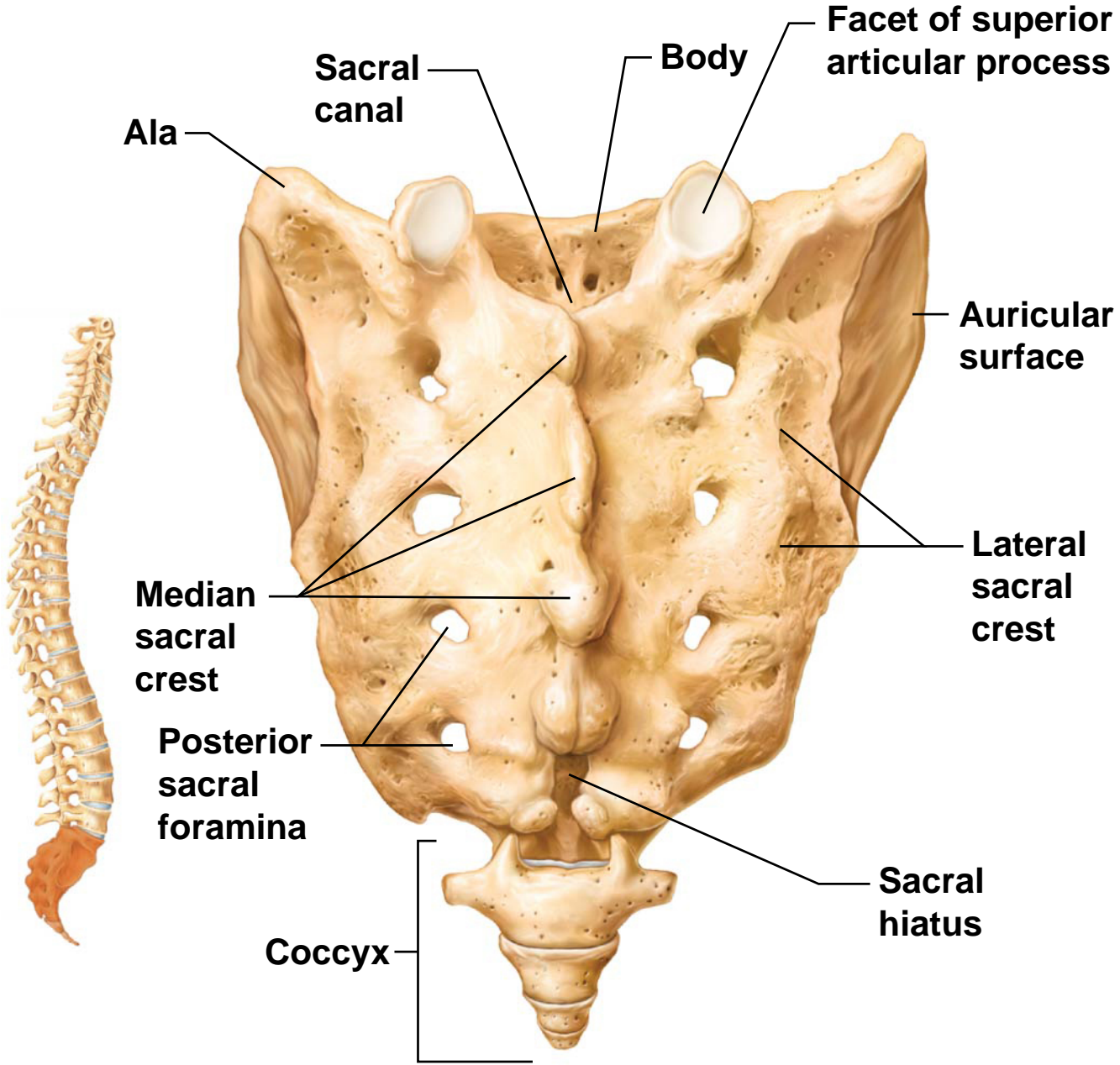


Figure 7.22a The sacrum and coccyx.



(a) Anterior view

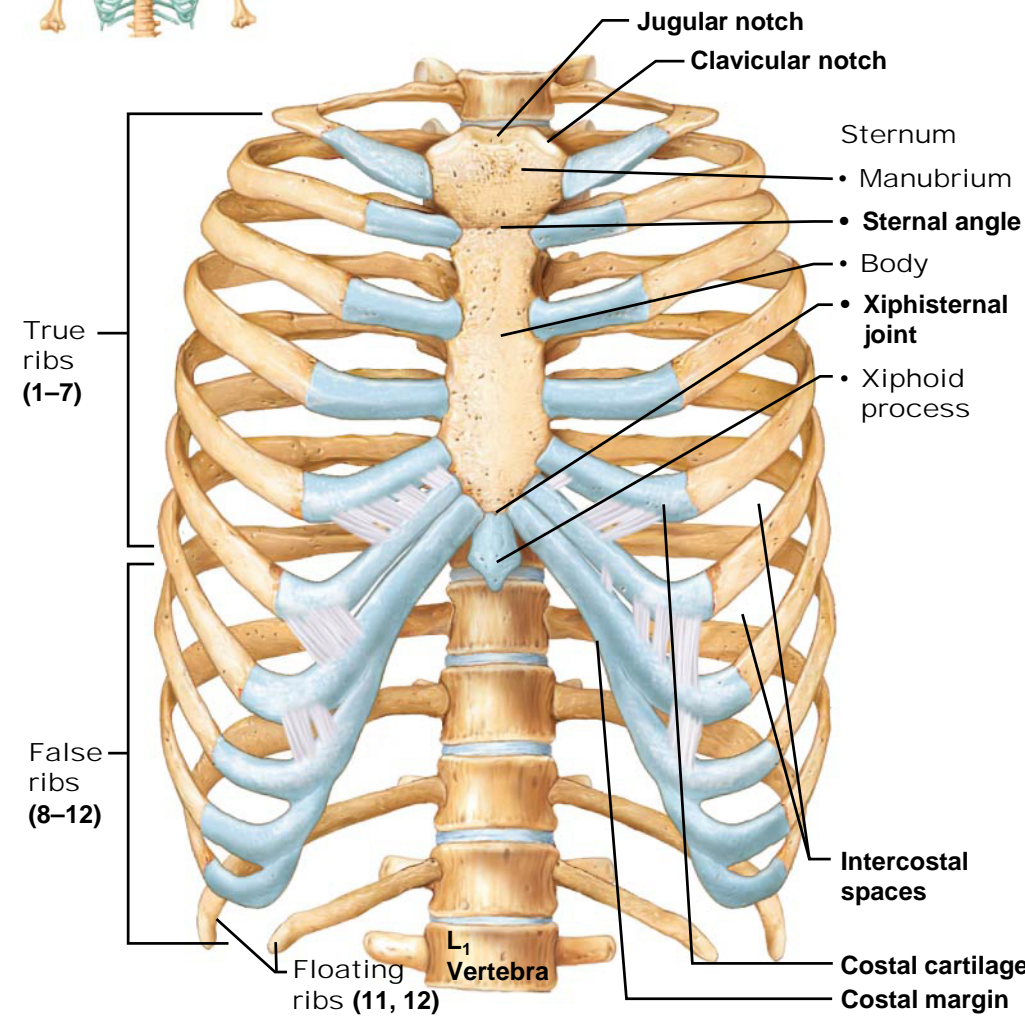
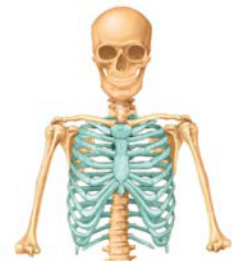Figure 7.22b The sacrum and coccyx.



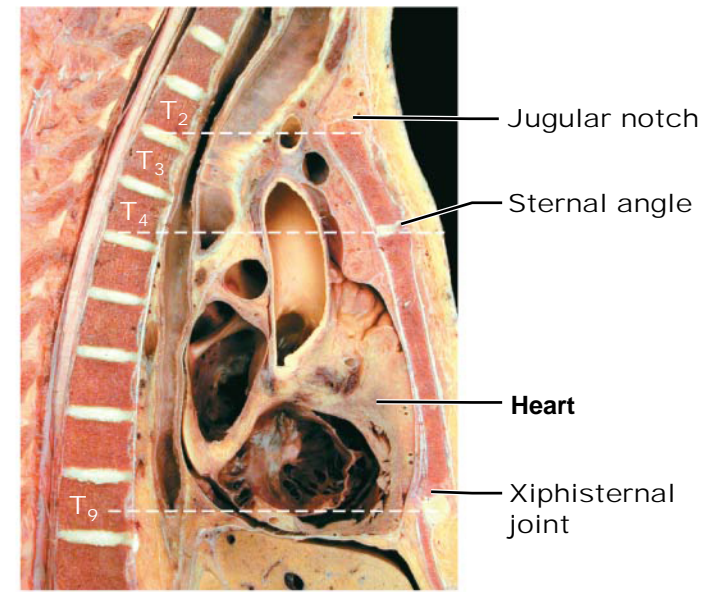
(b) Posterior view



Figure 7.23 The thoracic cage.

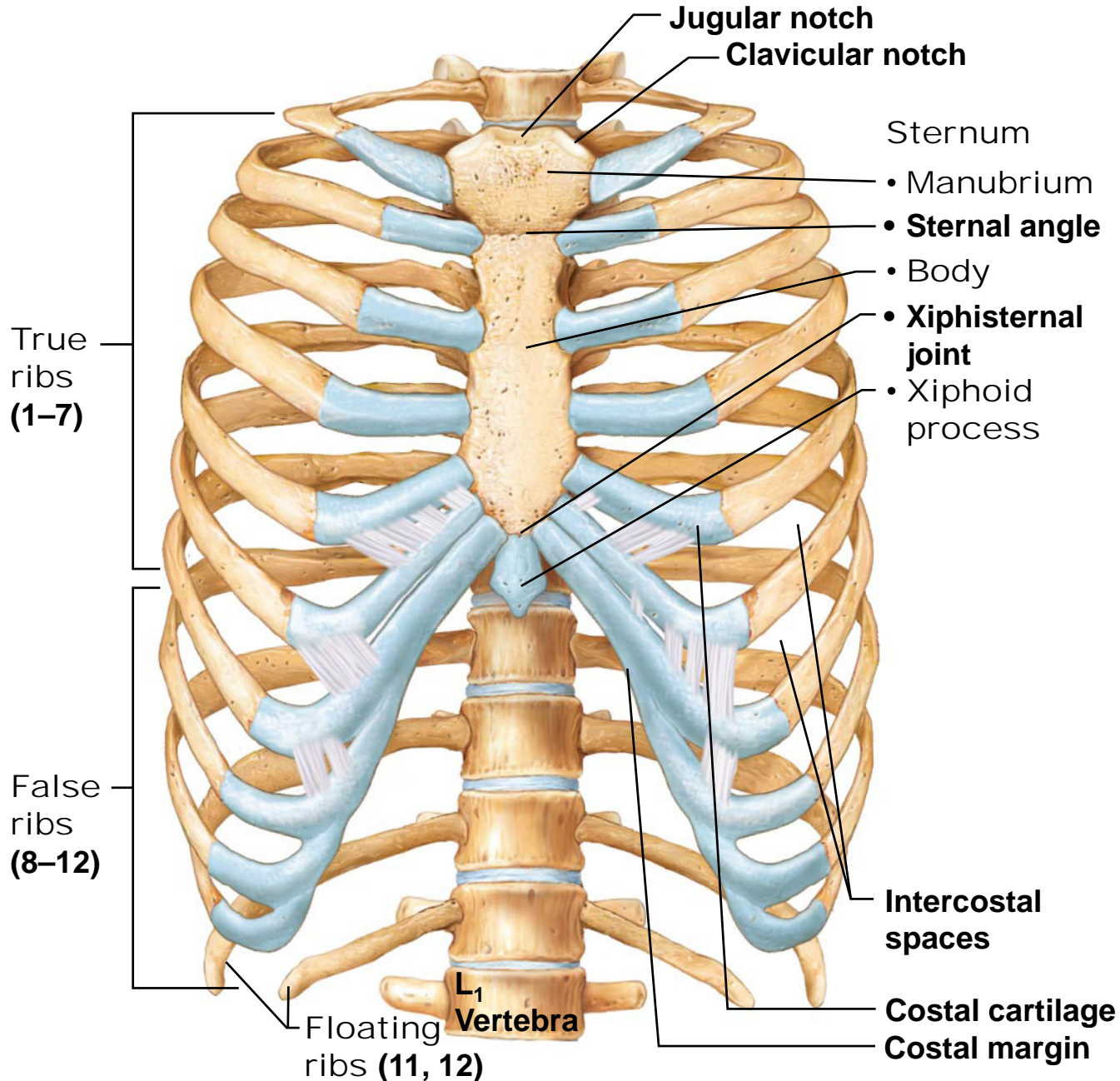
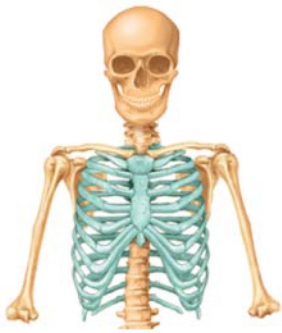


(a) Skeleton of the thoracic cage, anterior view



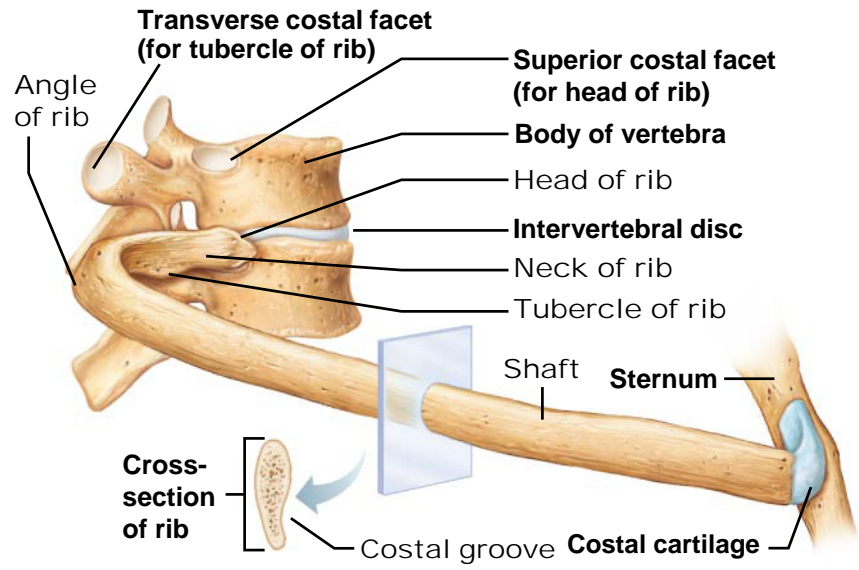
(b) Midsagittal section through the thorax, showing the relationship of surface anatomical landmarks of the thorax to the vertebral column

Figure 7.23a The thoracic cage.

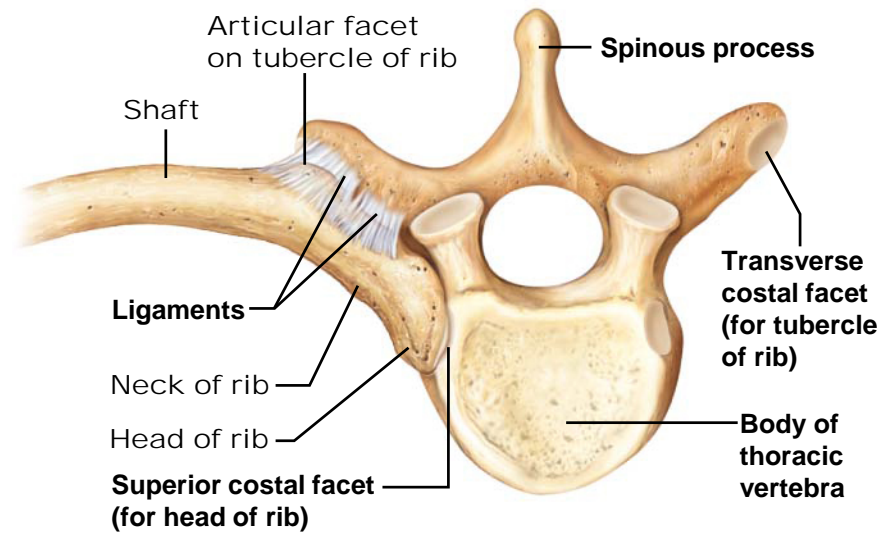


**(a)** Skeleton of the thoracic cage, anterior view

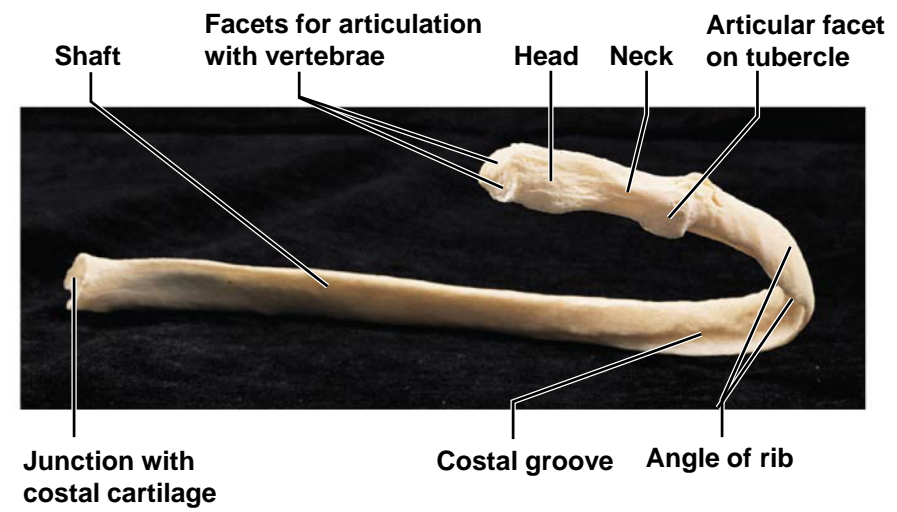
Figure 7.24 Ribs.



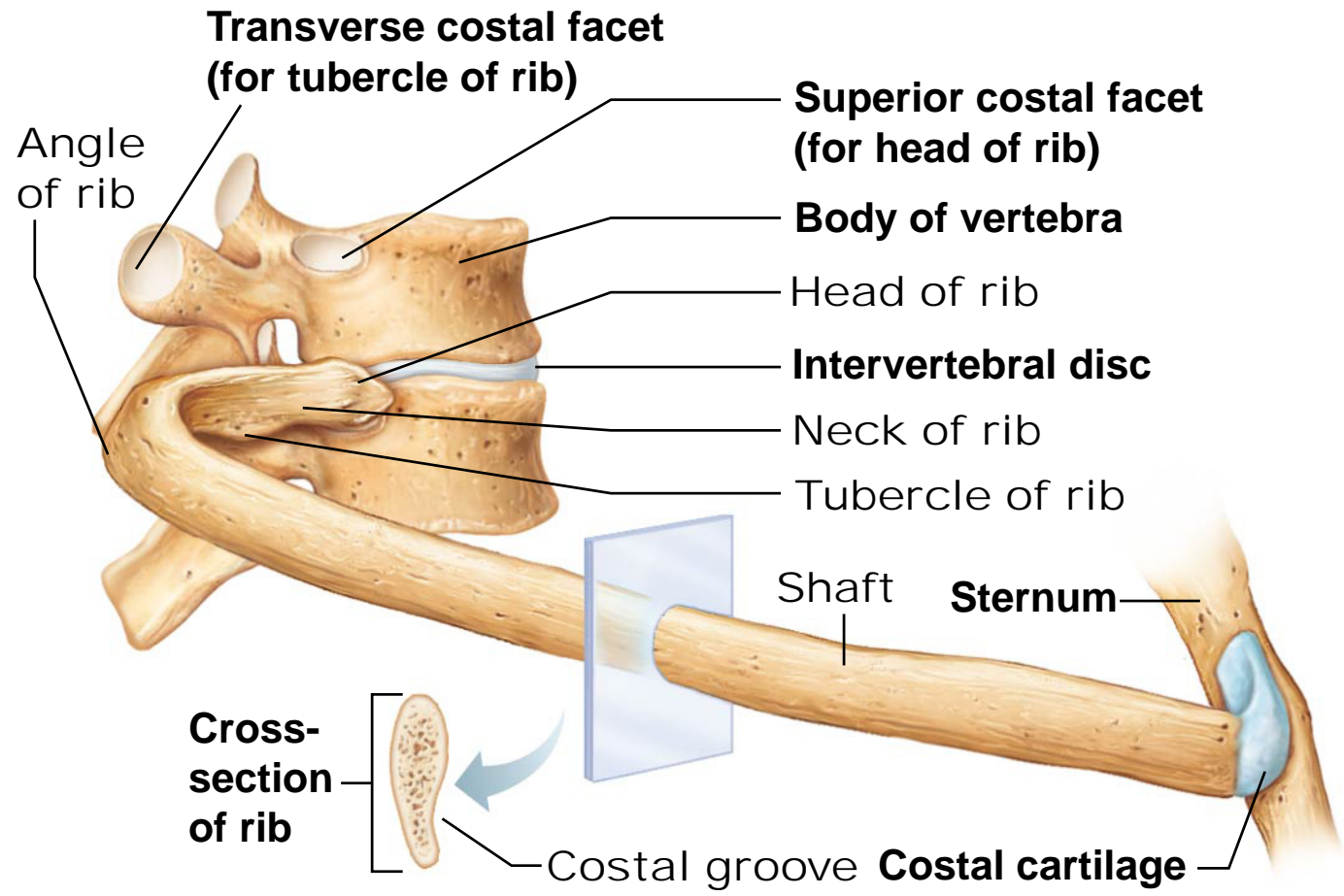
(a) Vertebral and sternal articulations of a typical true rib



(b) Superior view of the articulation between a rib and a thoracic vertebra

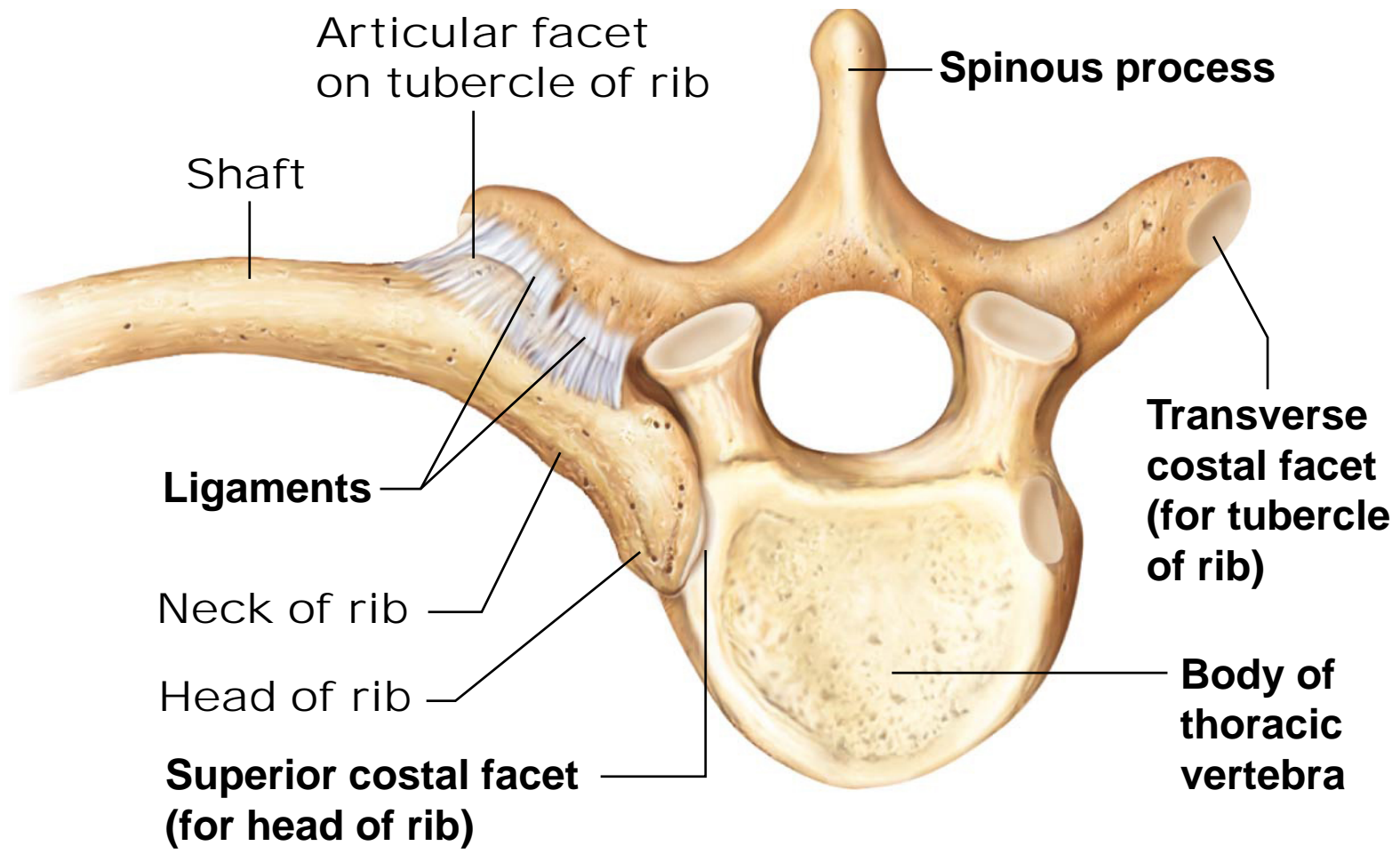


(c) A typical rib (rib 6, right), posterior view



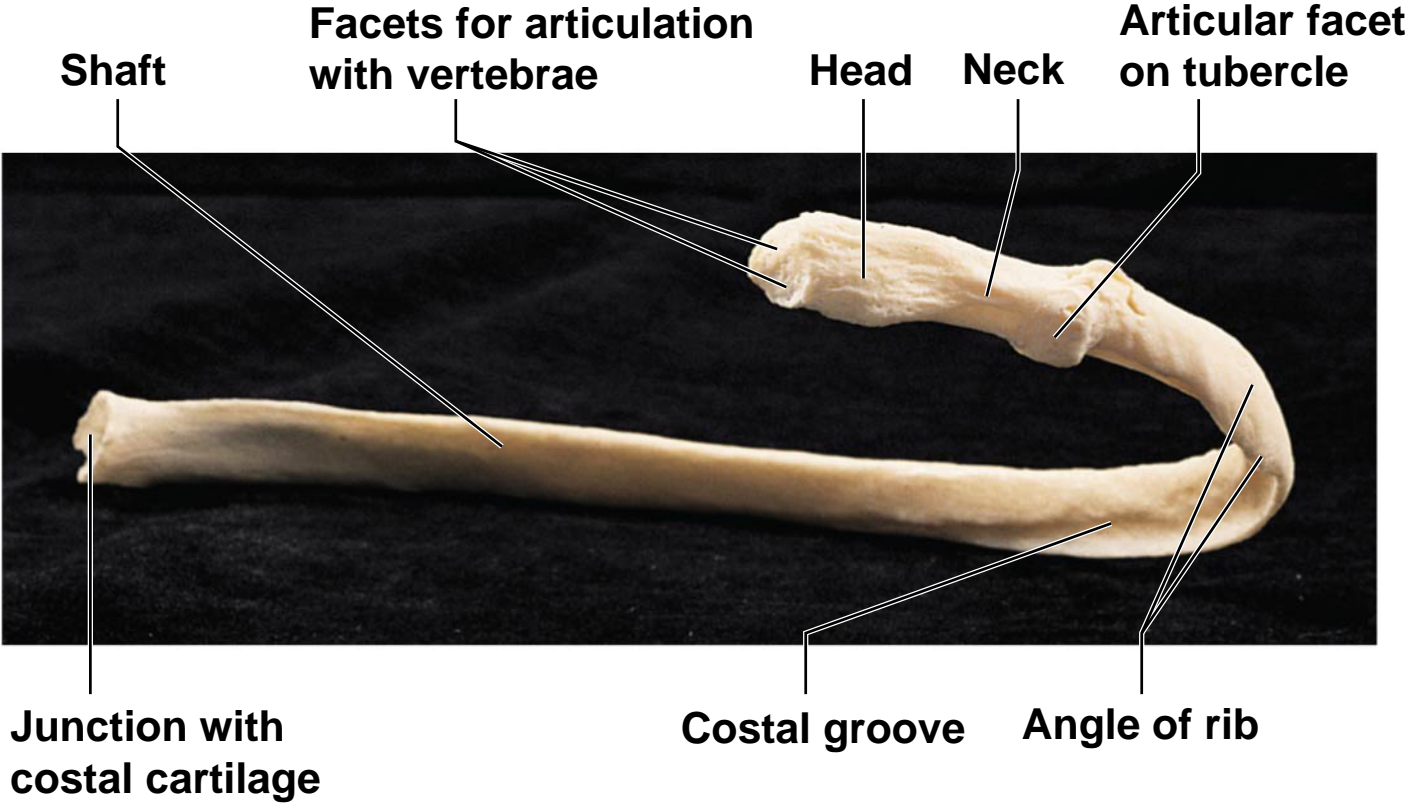
**(a)** Vertebral and sternal articulations of a typical true rib

Figure 7.24b Ribs.



**(b)** Superior view of the articulation between a rib and a thoracic vertebra

Figure 7.24c Ribs.



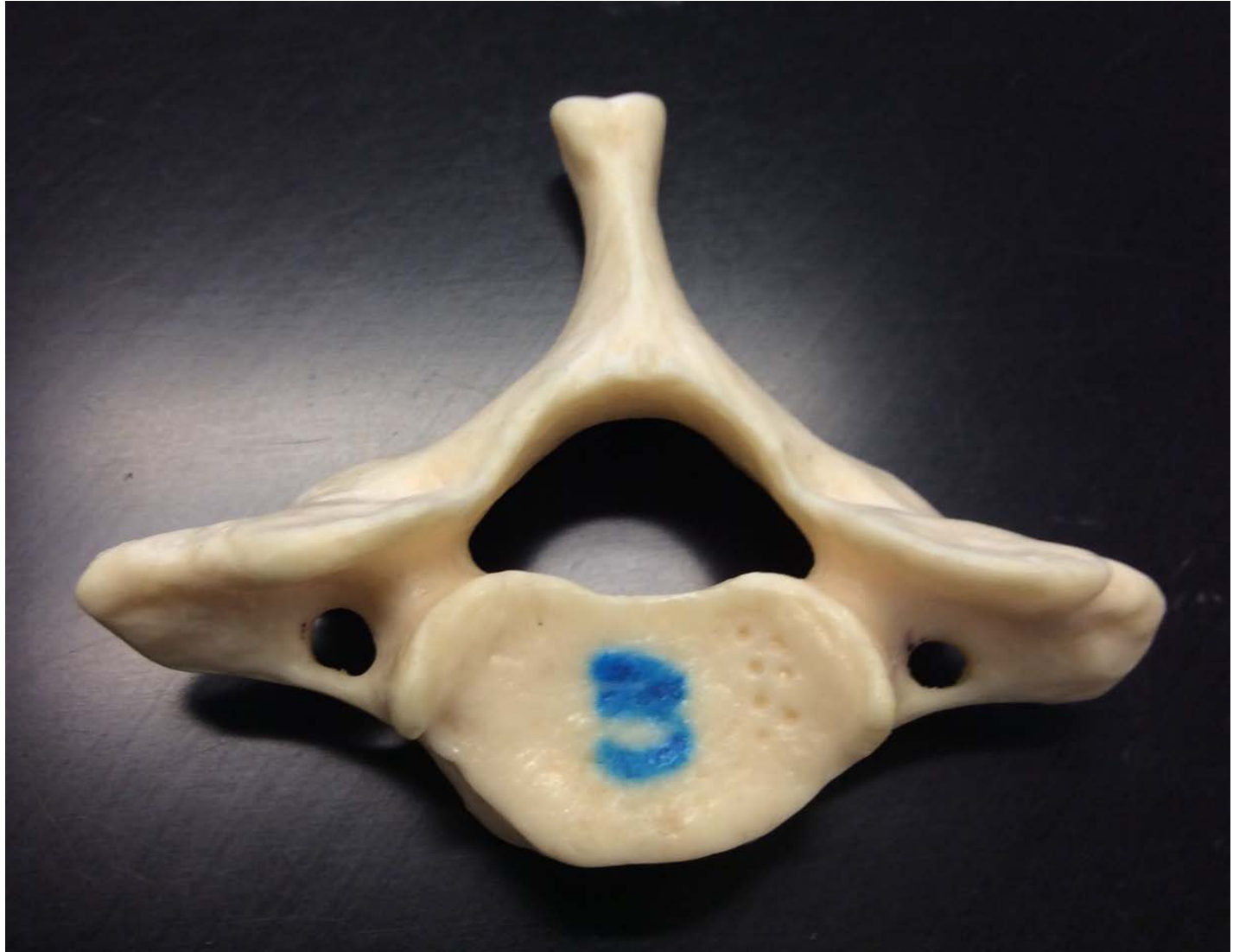
**(c)** A typical rib (rib 6, right), posterior view

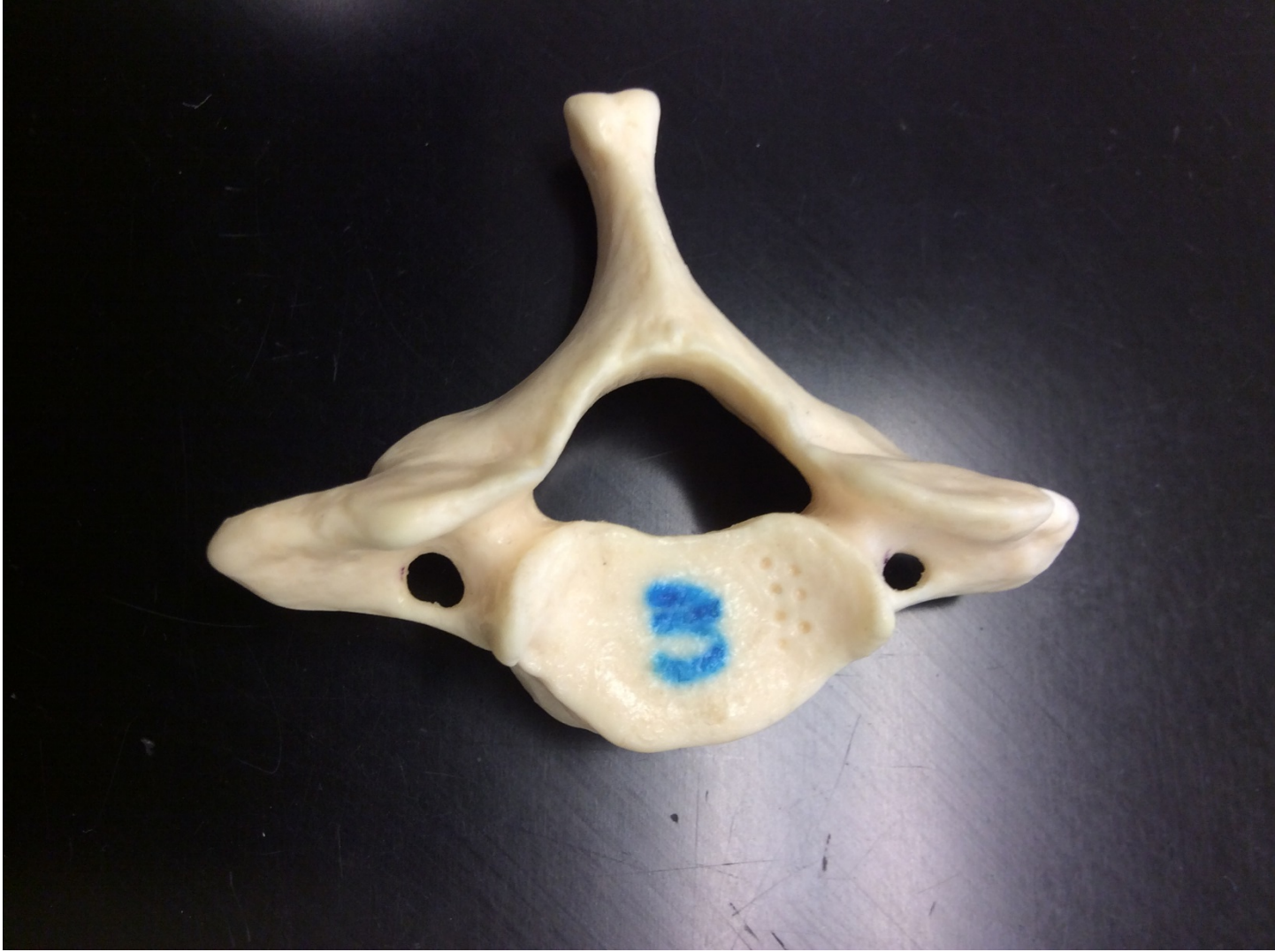
Use the following pictures to help you practice finding the terms from the lab term handout on unlabeled images.

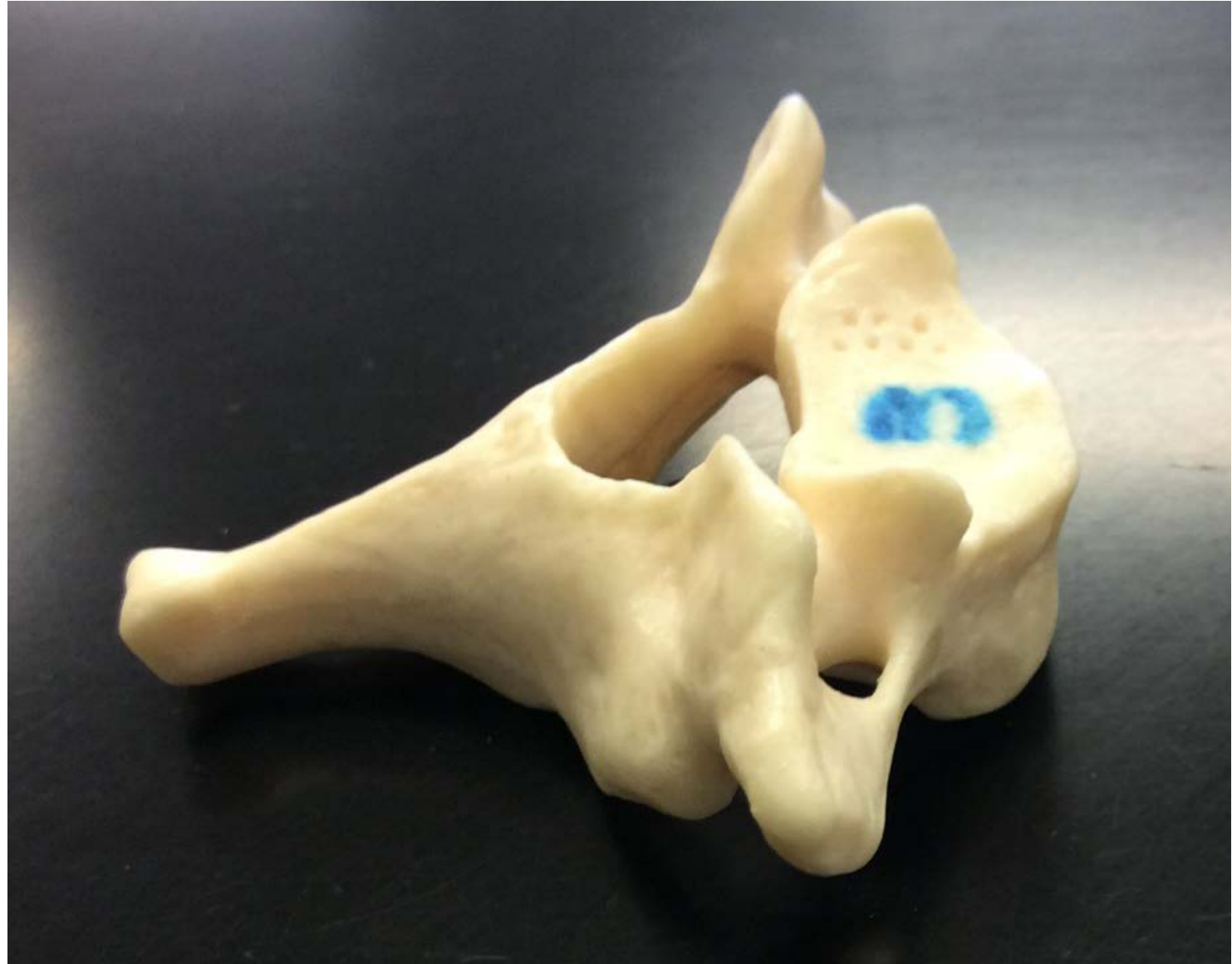- Remember, you won't learn them if you don't take plenty of time to practice!
- Also, be sure to mix up the order once you get comfortable with the unlabeled slides.
- Over the weekend, once you are feeling confident with the pictures here, do the bone model quizzes in PAL (from the Pearson website) to get practice with new pictures that you haven't seen.

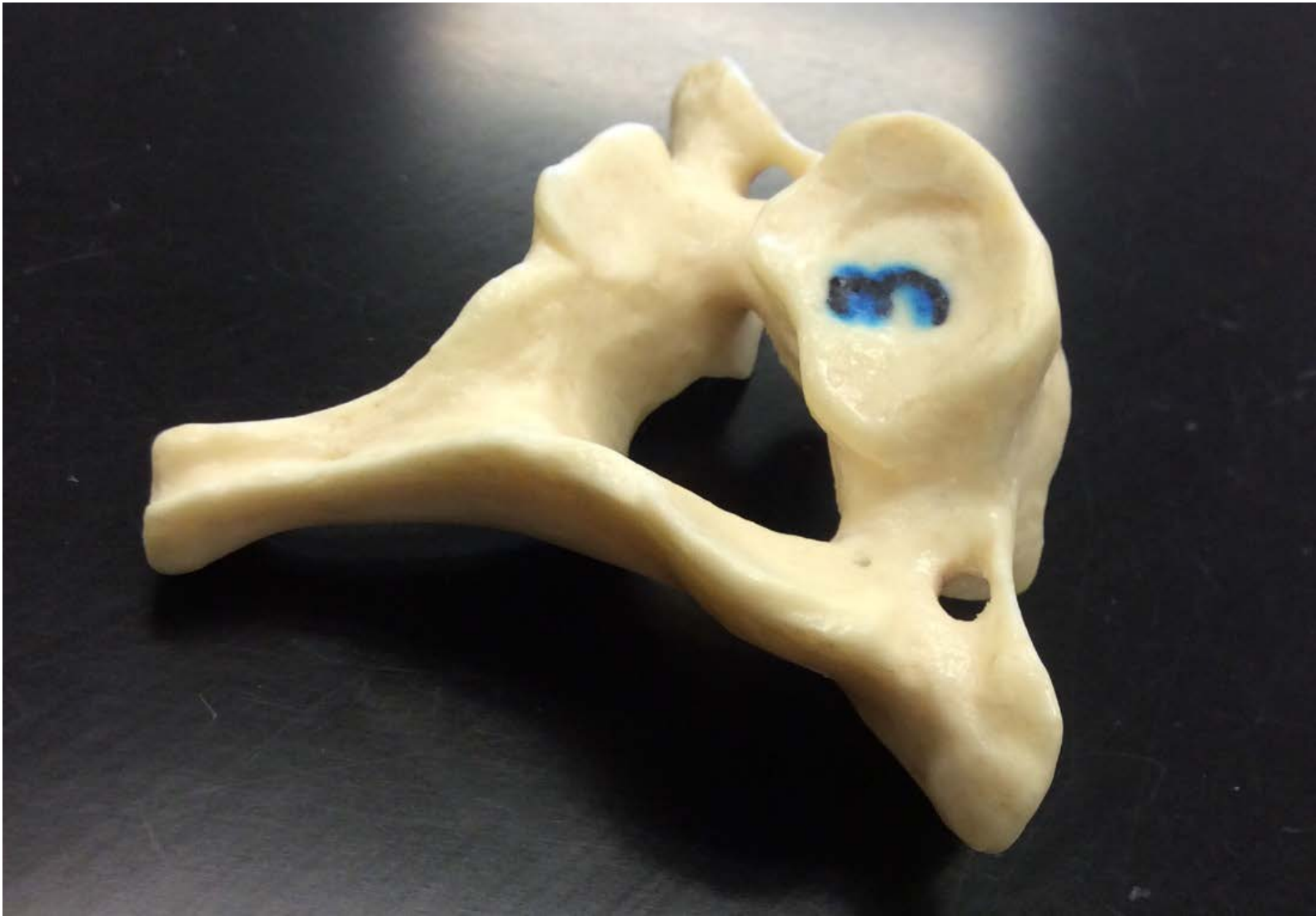# Vertebral Column: Cervical

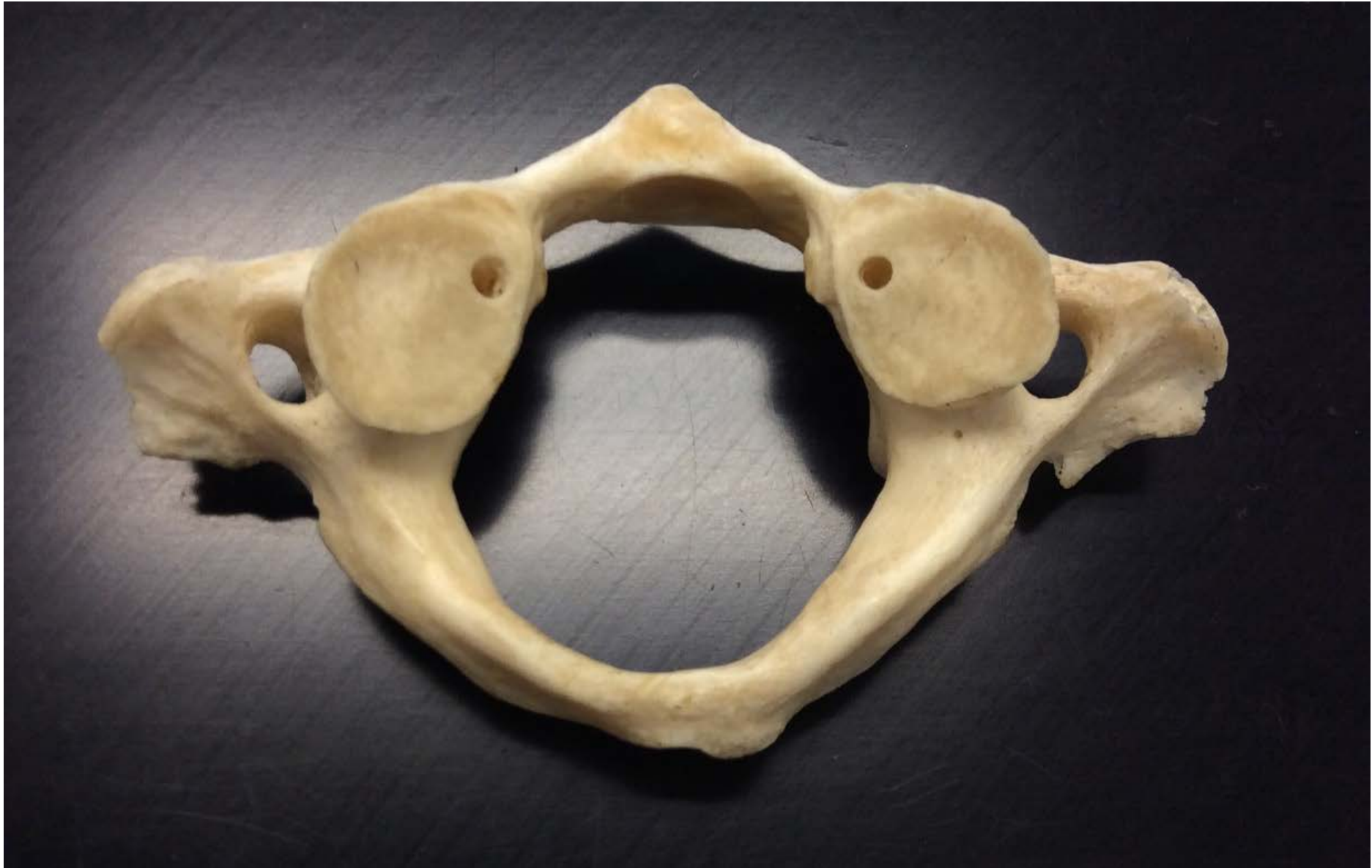


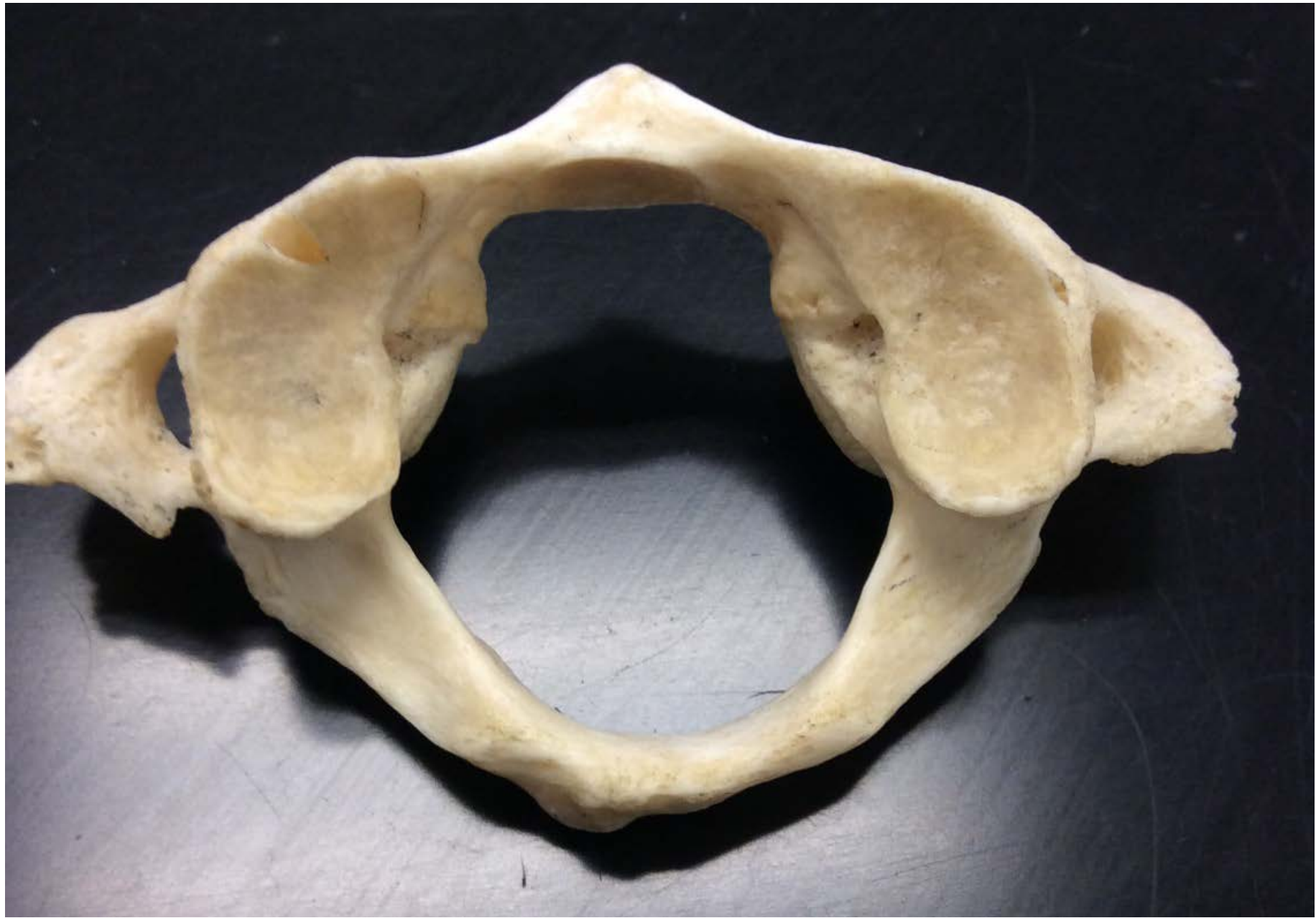


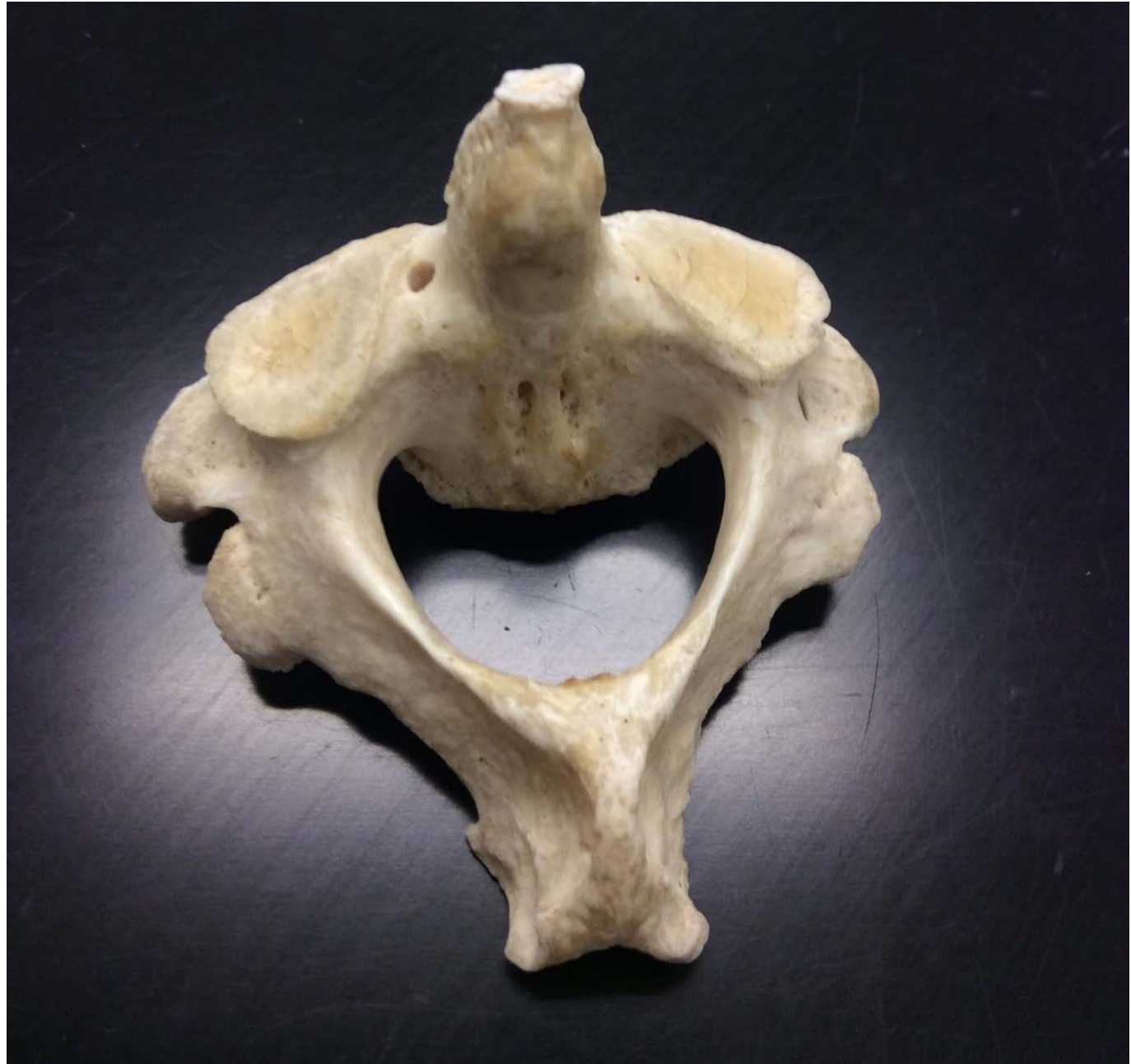


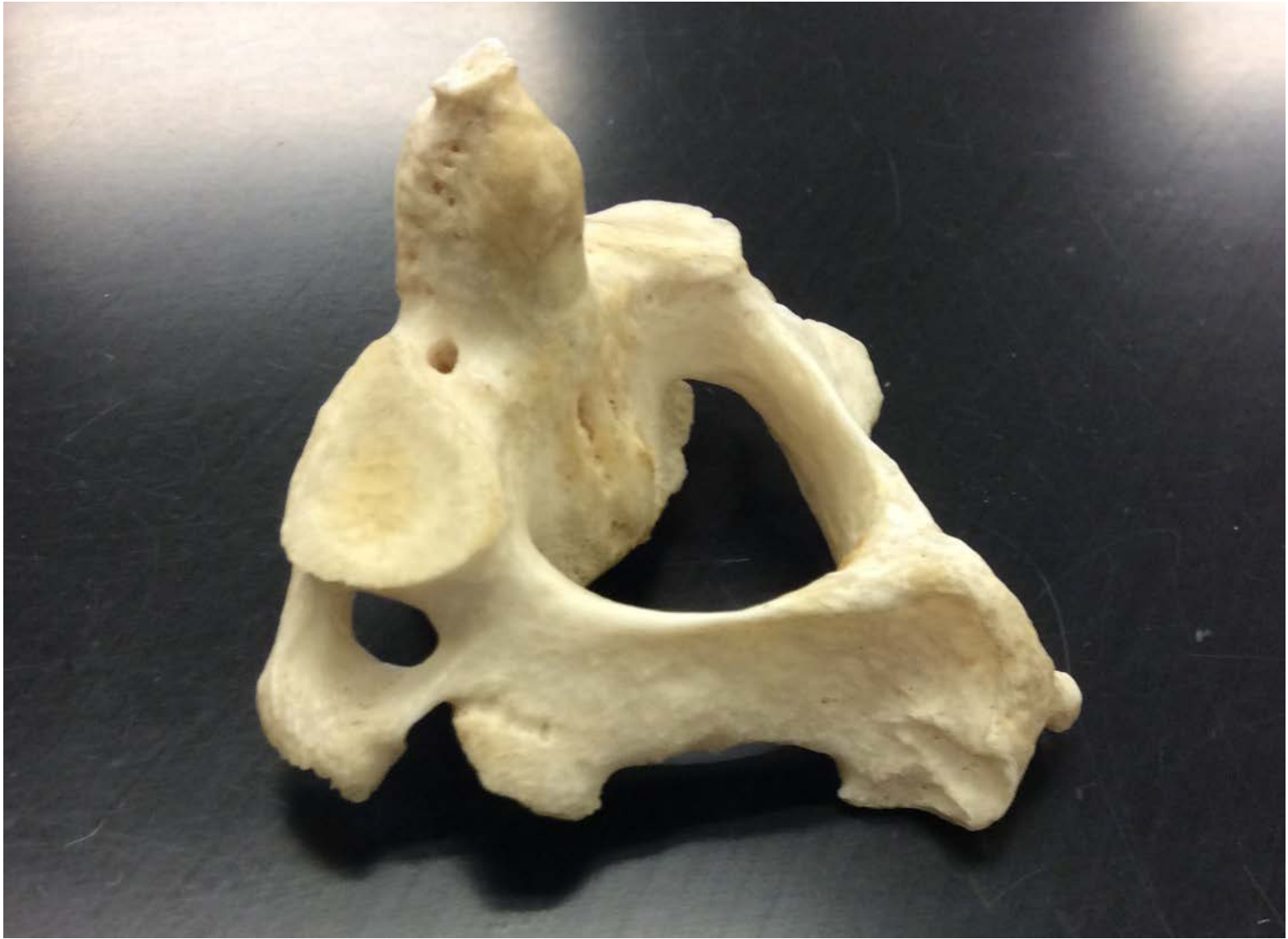






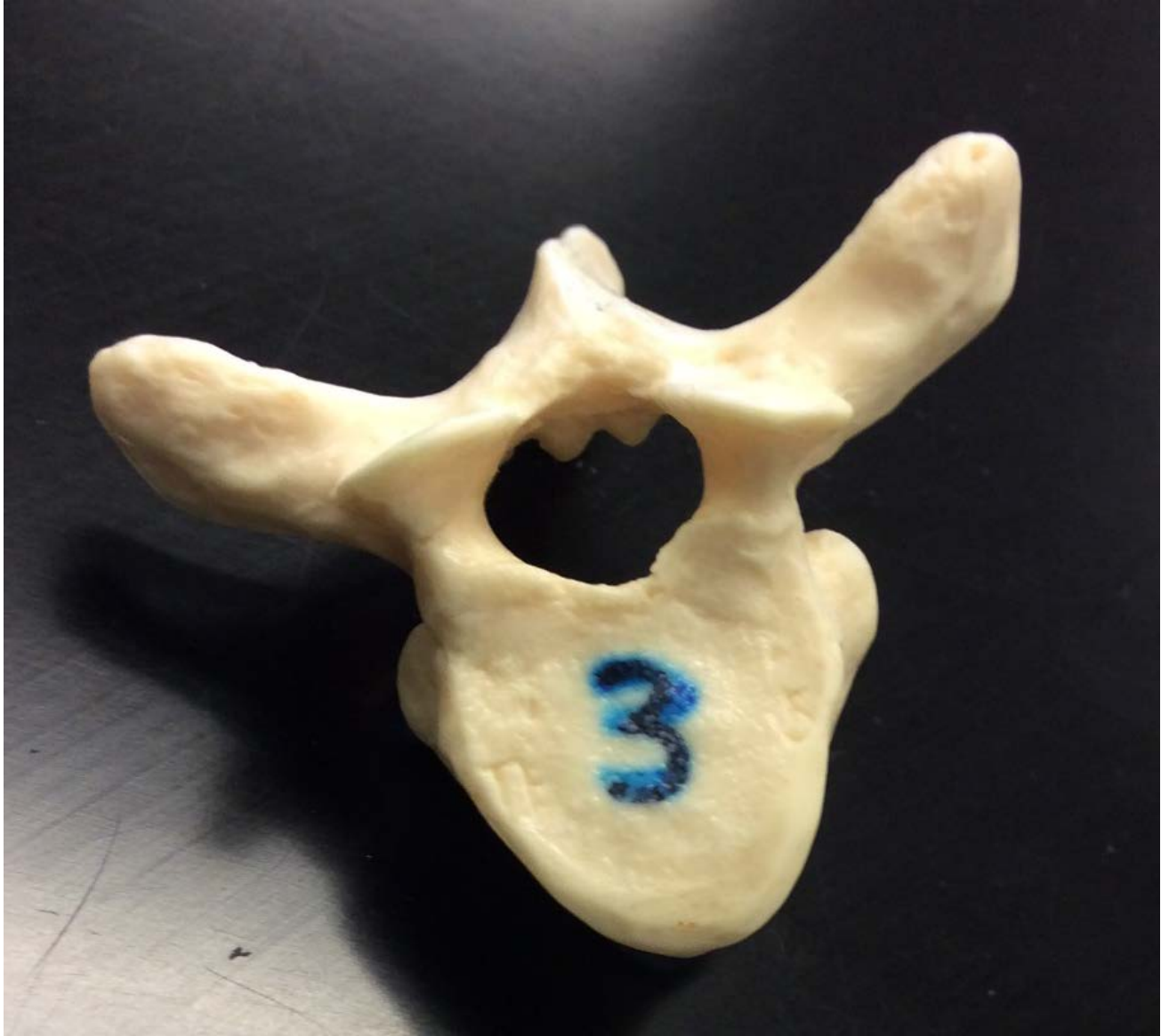


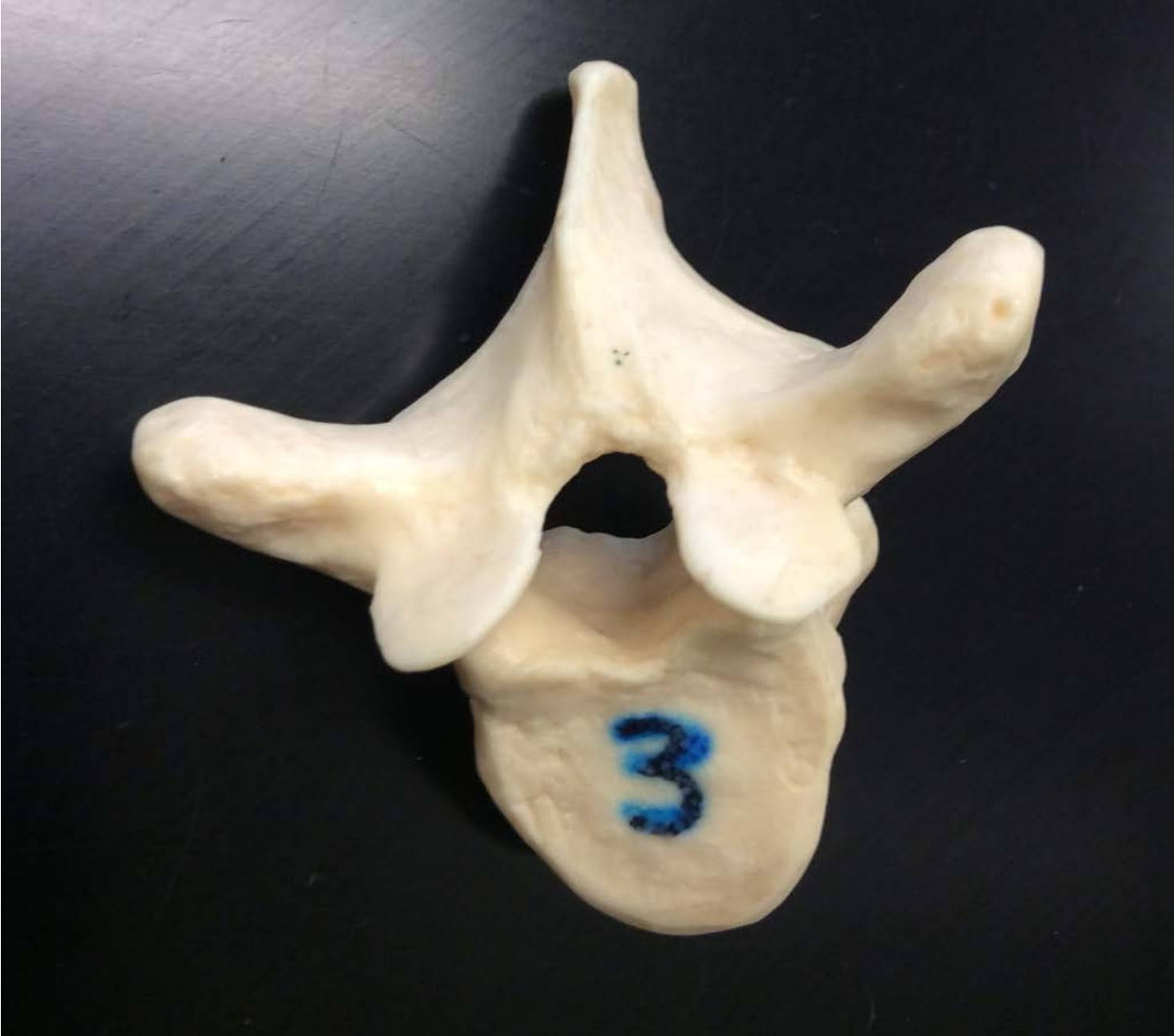
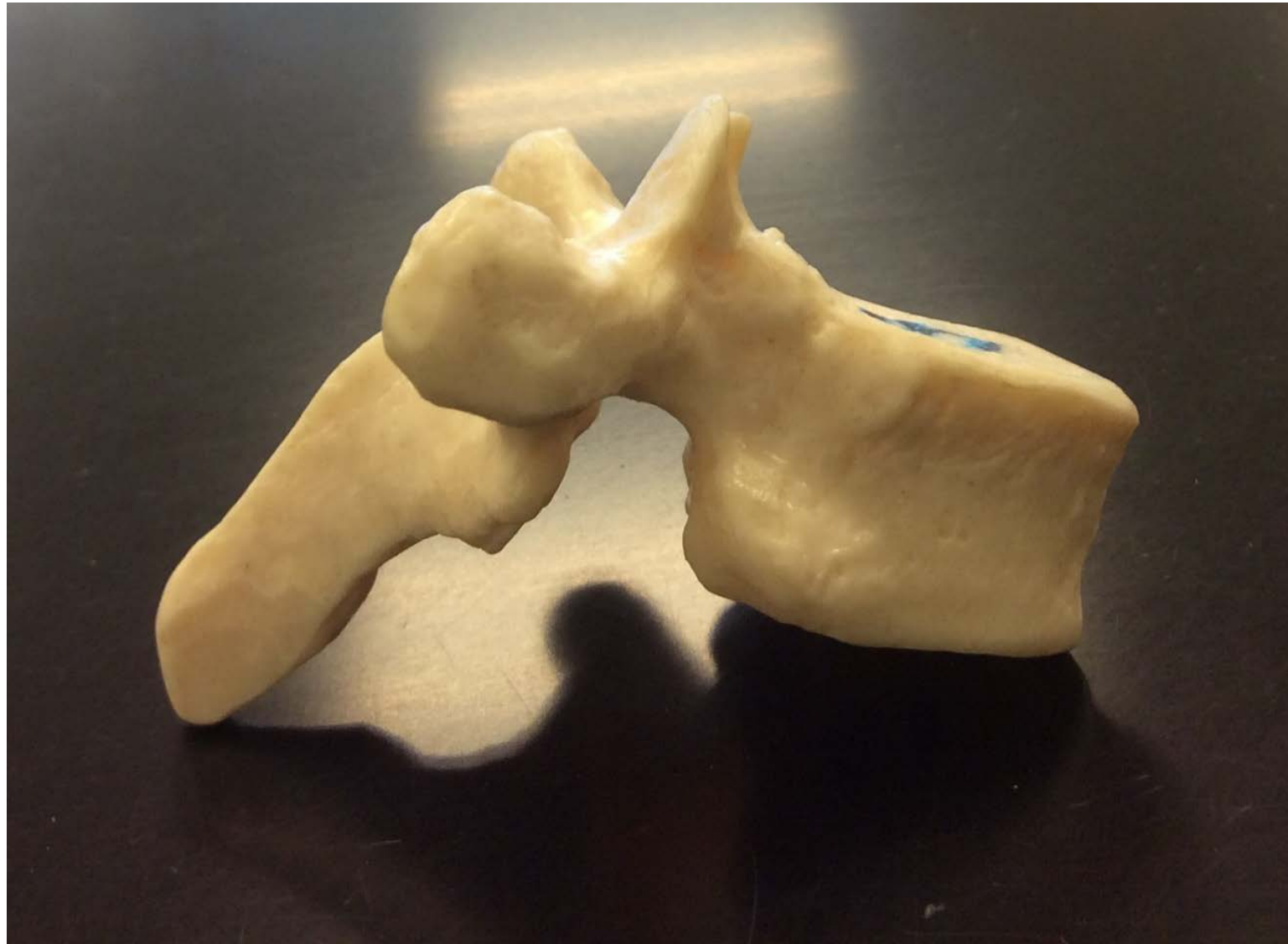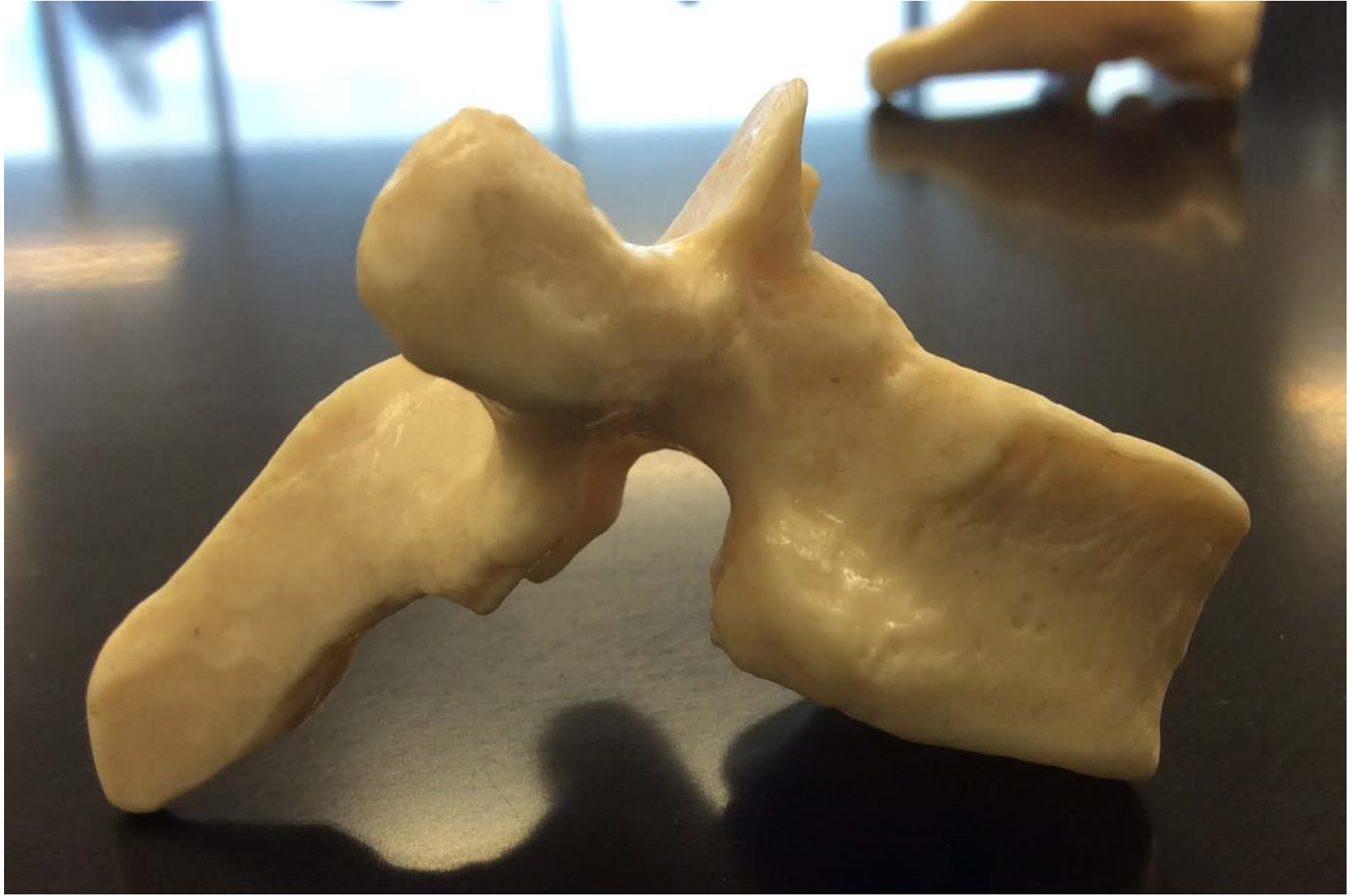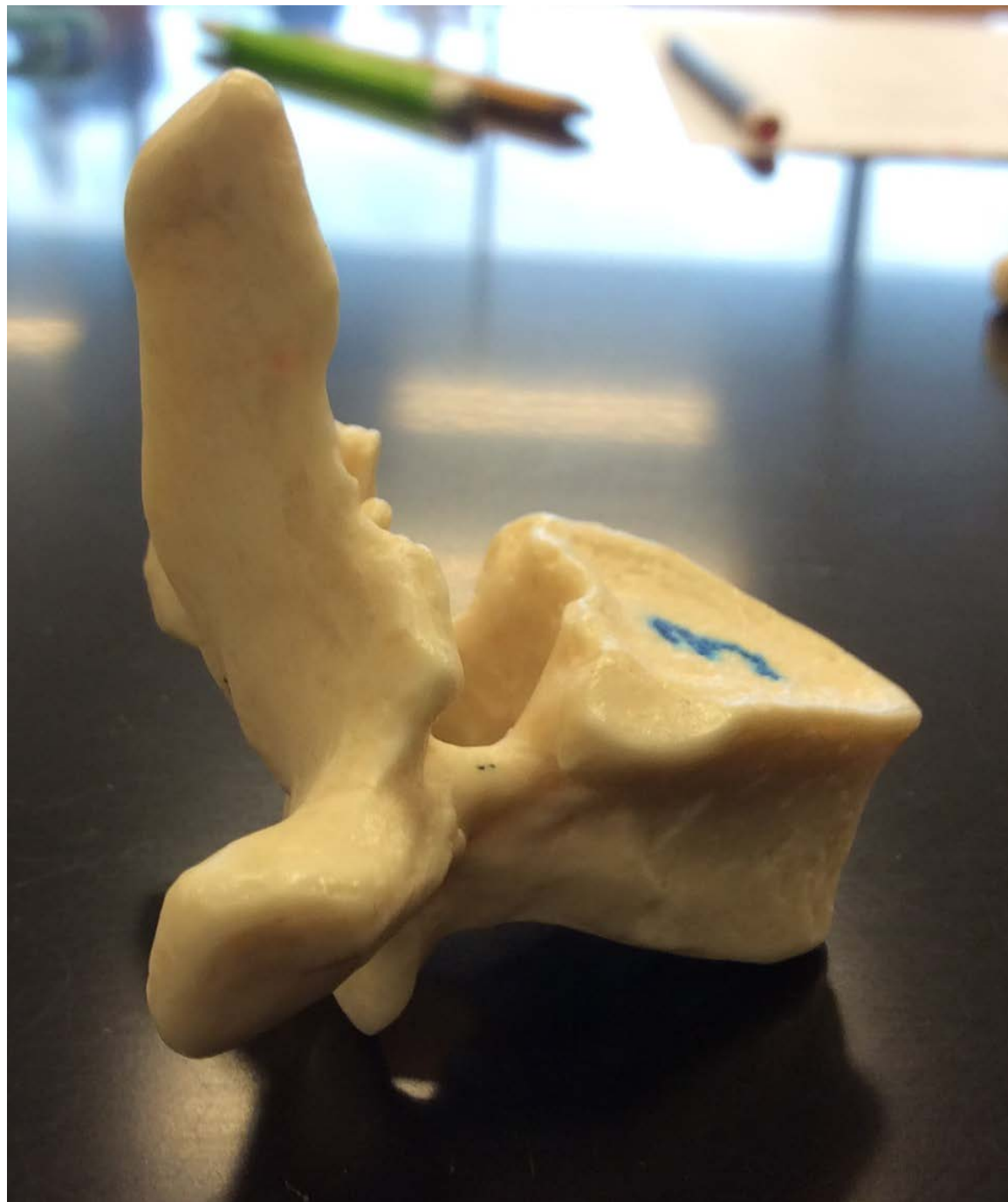# Vertebral Column: Thoracic

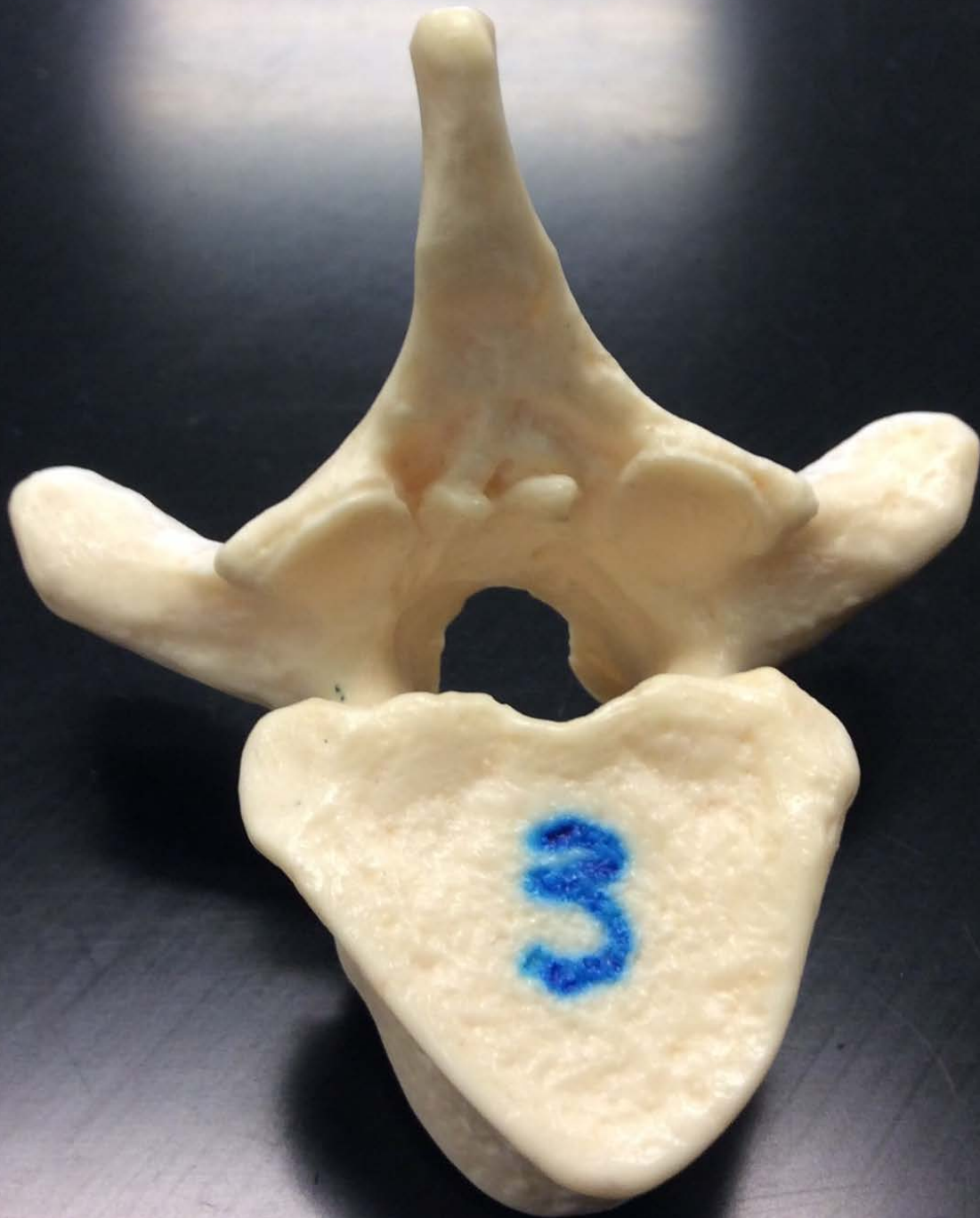






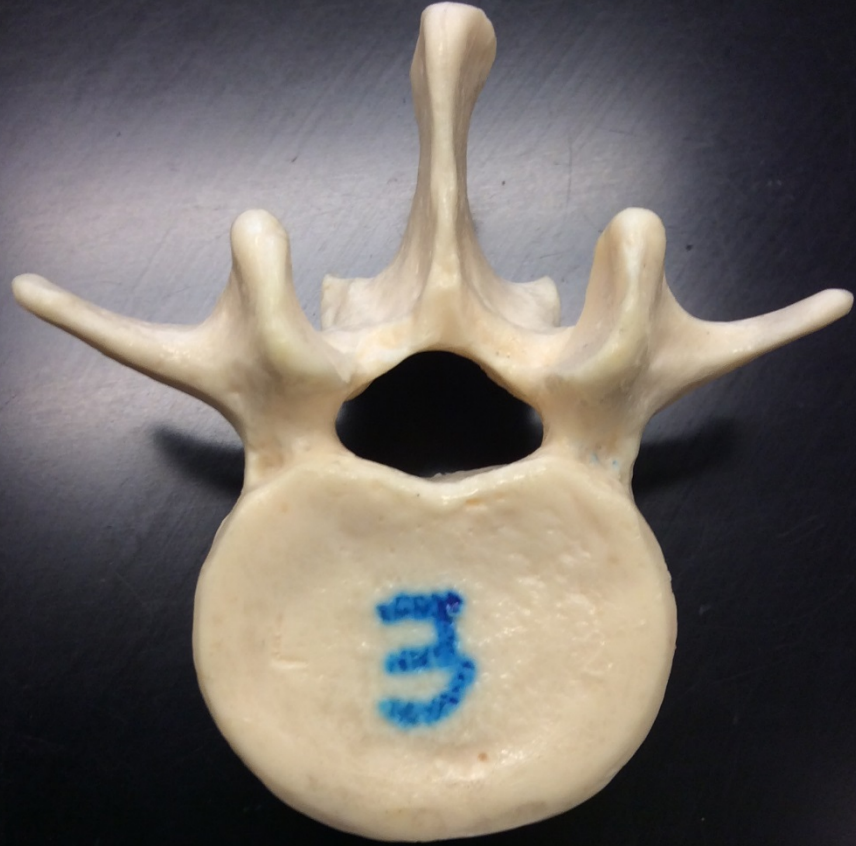


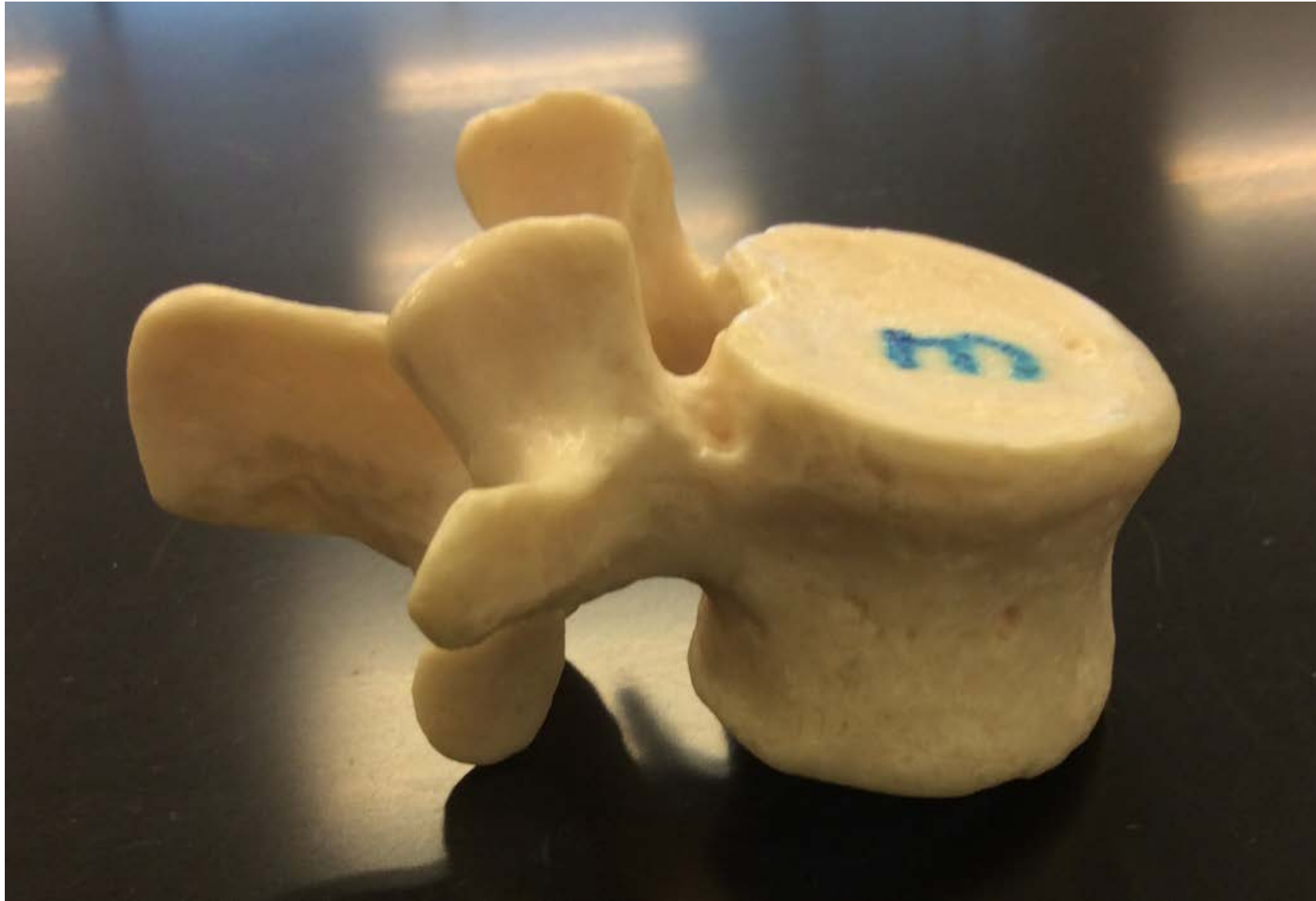

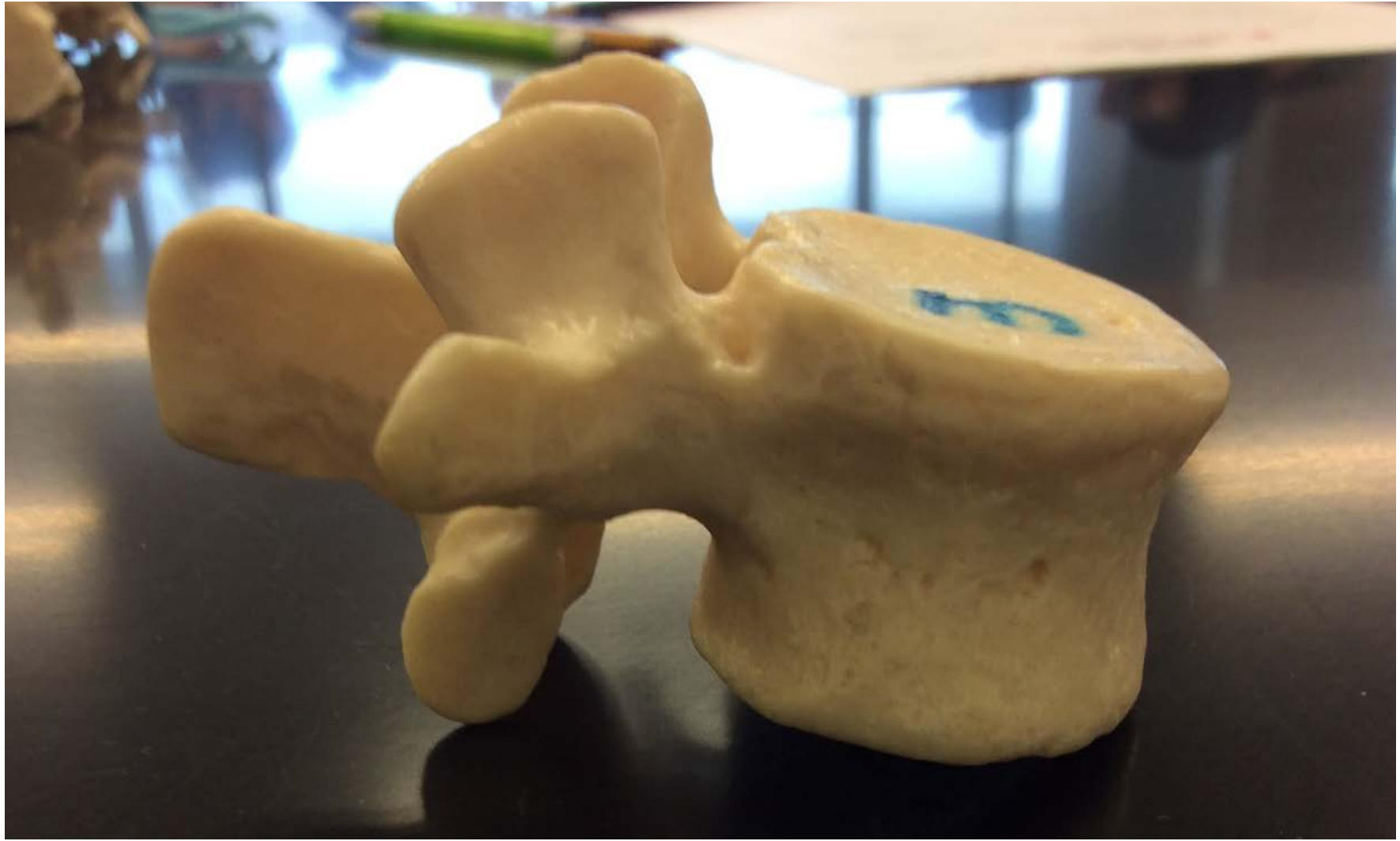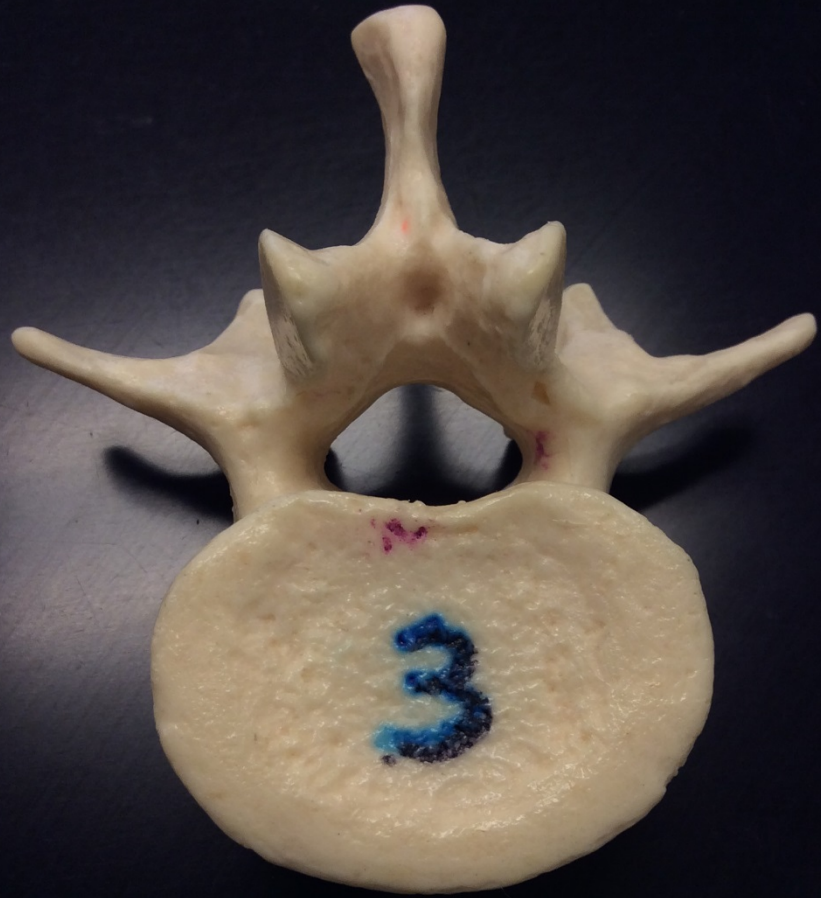# Vertebral Column: Lumbar + Sacrum and Coccyx

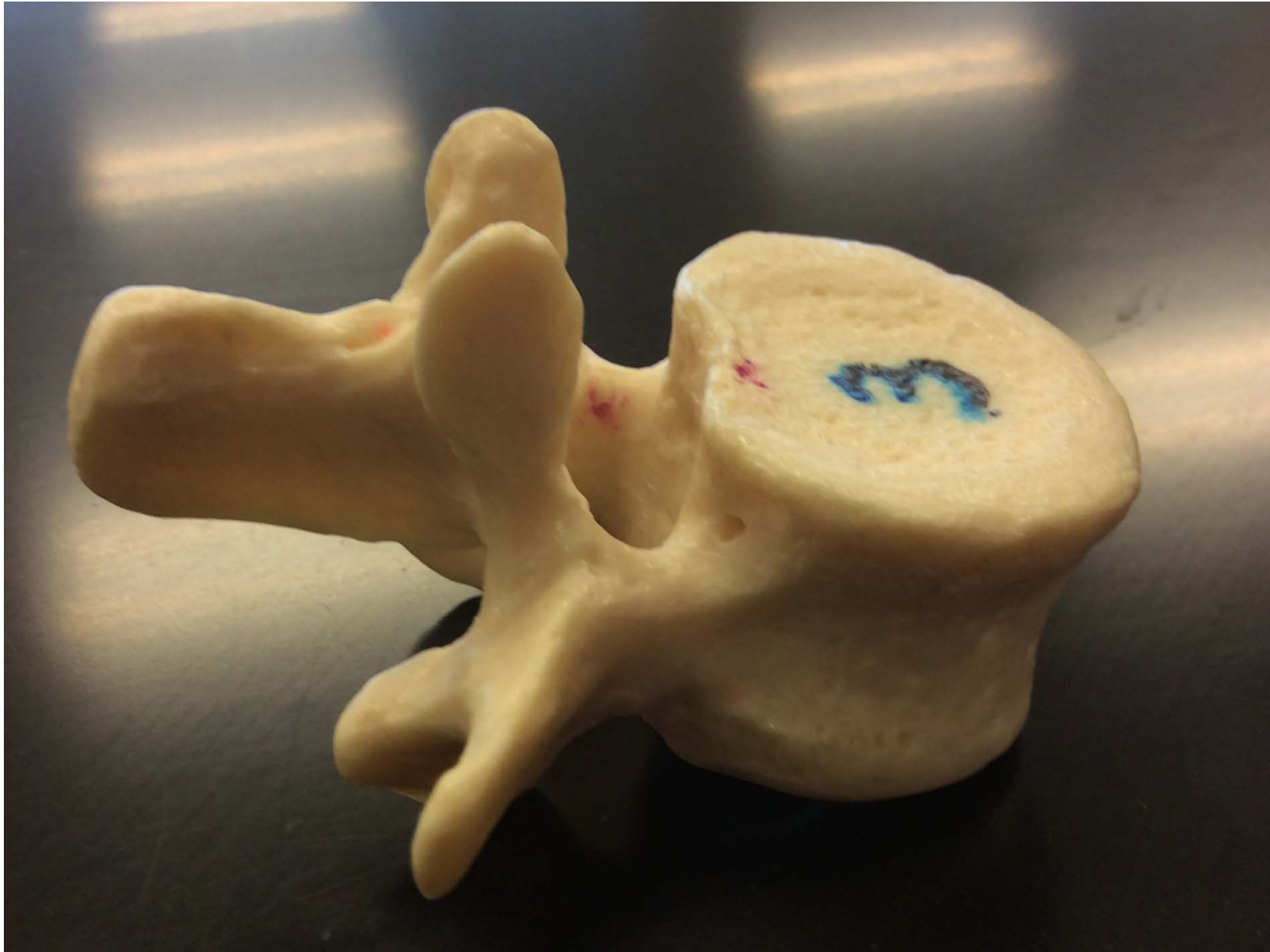


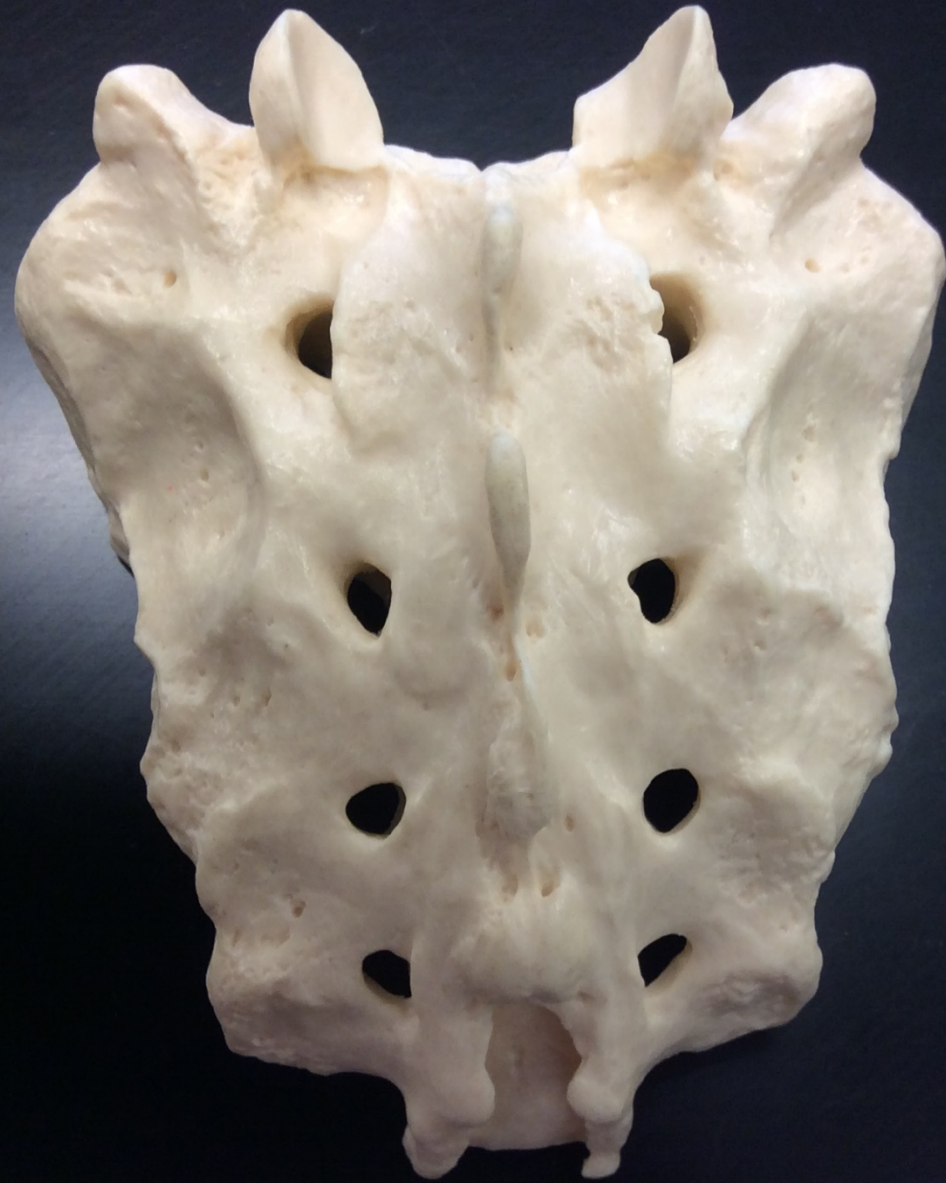


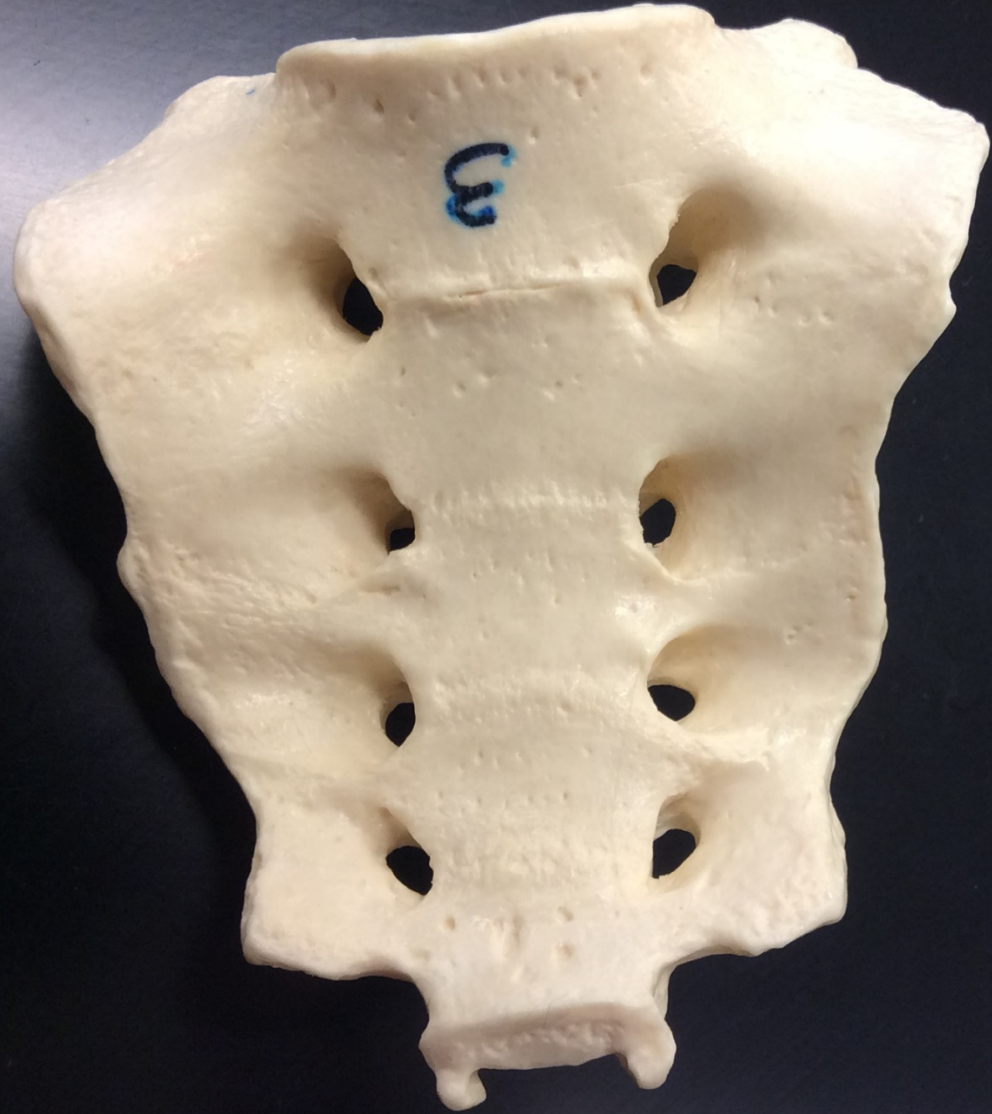


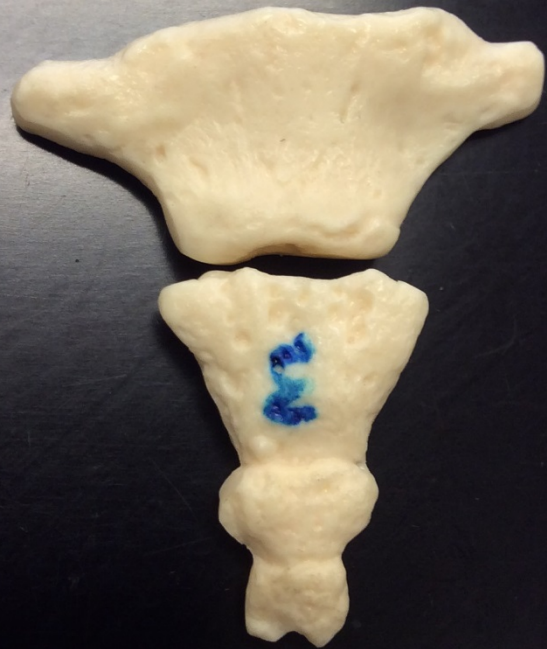










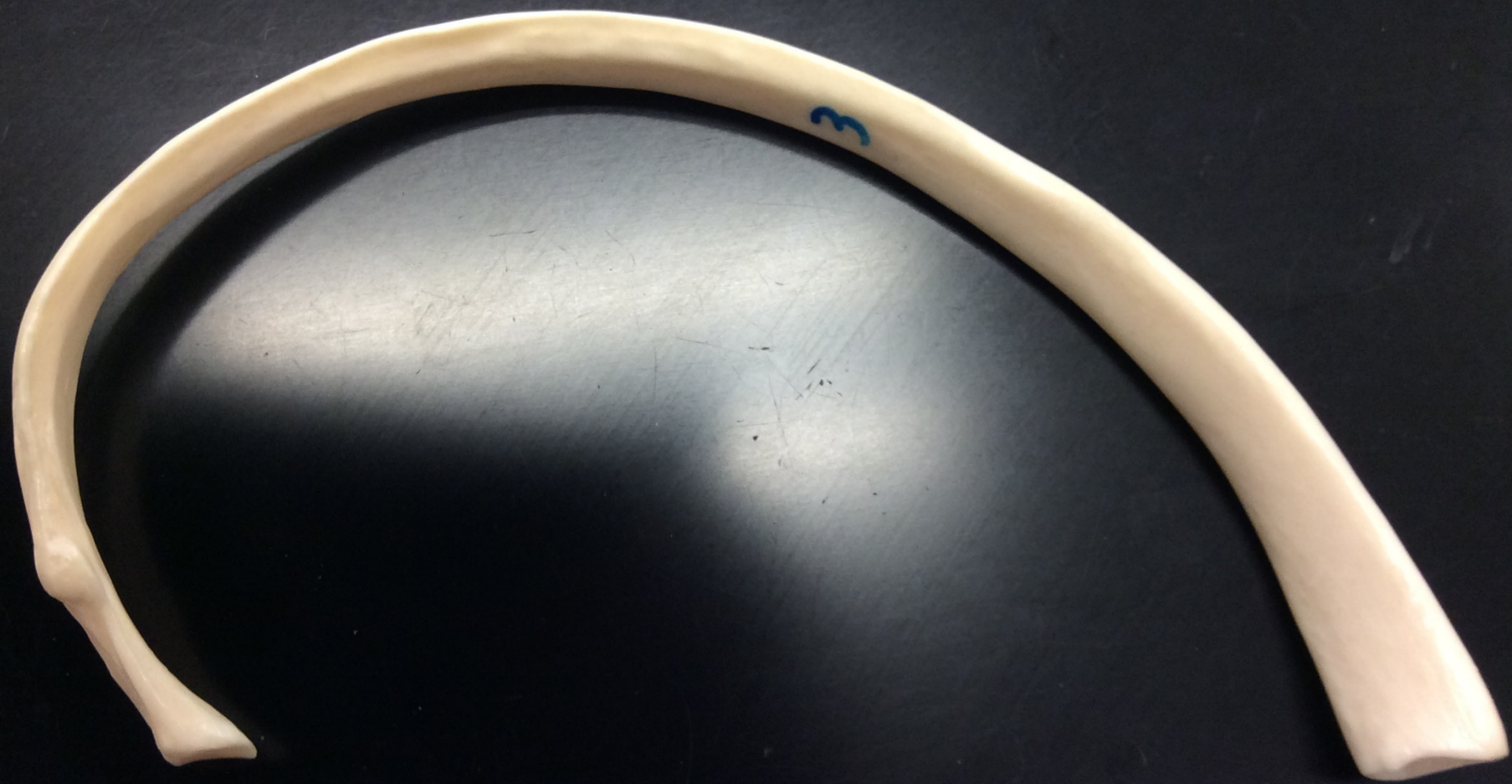Thorax

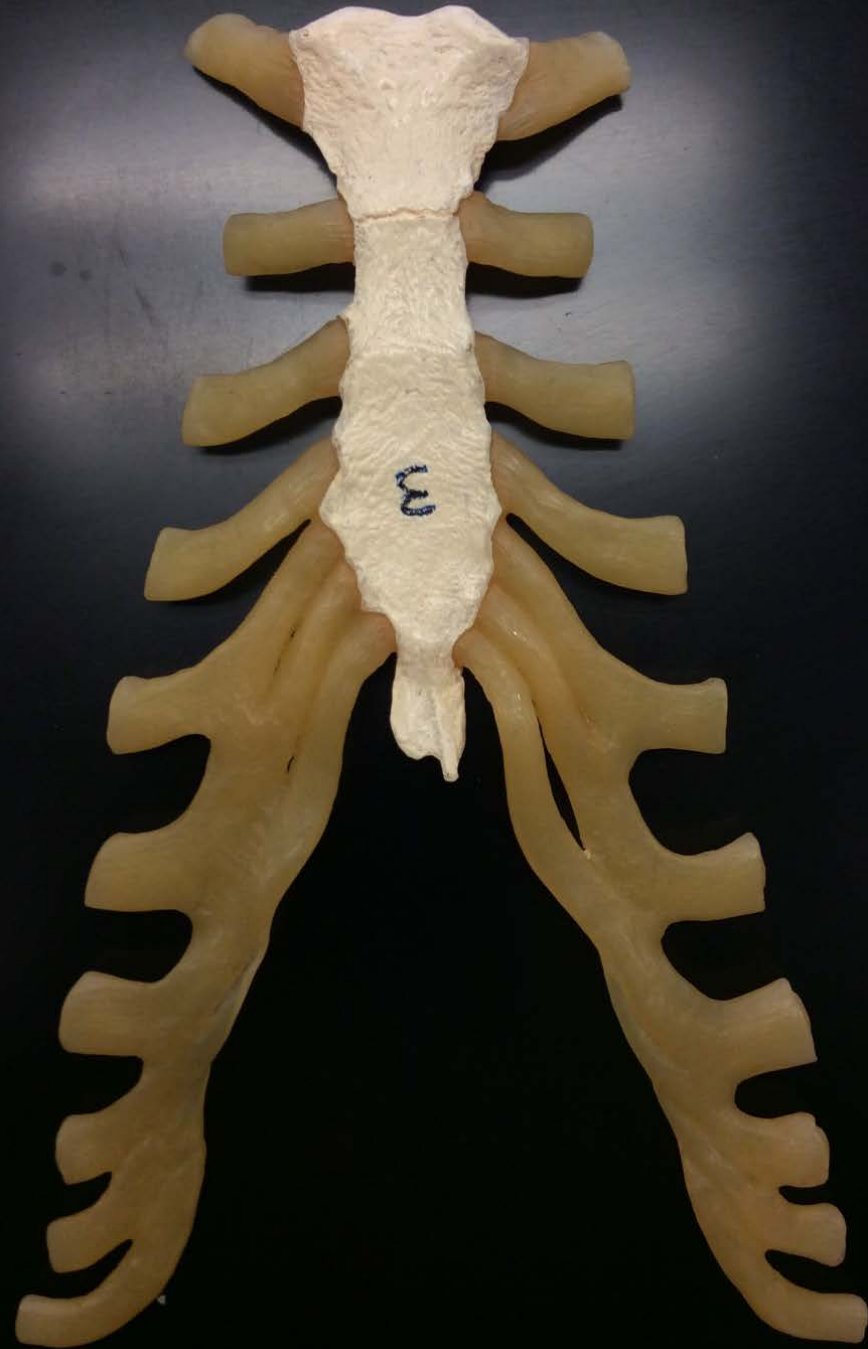












# Use the following pictures to help you identify terms from the lab term handout.

Another good resource is the Visible Body app: <http://skeleton.visiblebody.com>

Don't forget that to use the link to download to a personal device, the device must first be connected to the MCPA Wi-Fi at the Rockville campus.



Figure 7.25 The pectoral girdle with articulating bones.

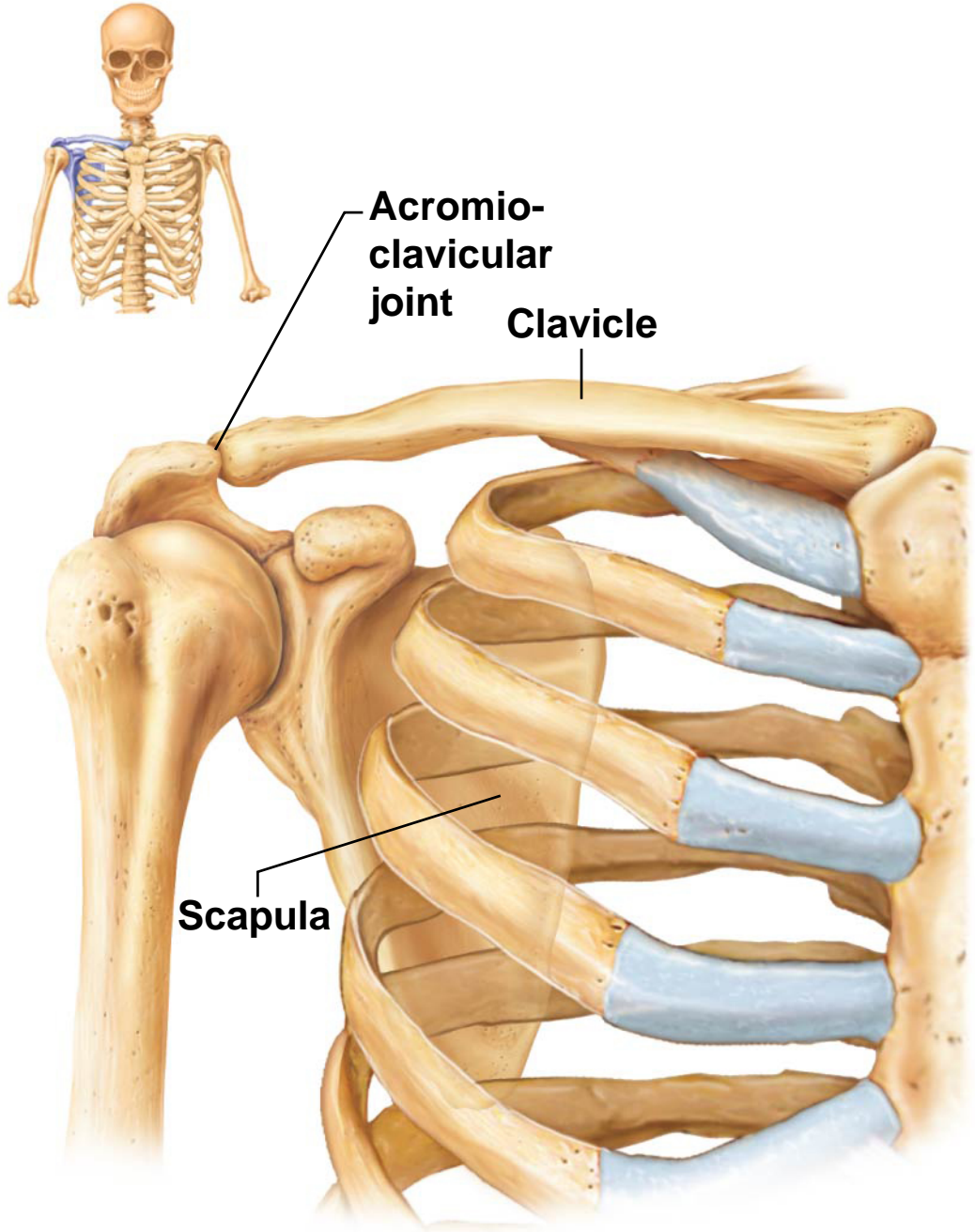


Figure 7.26 The clavicle.

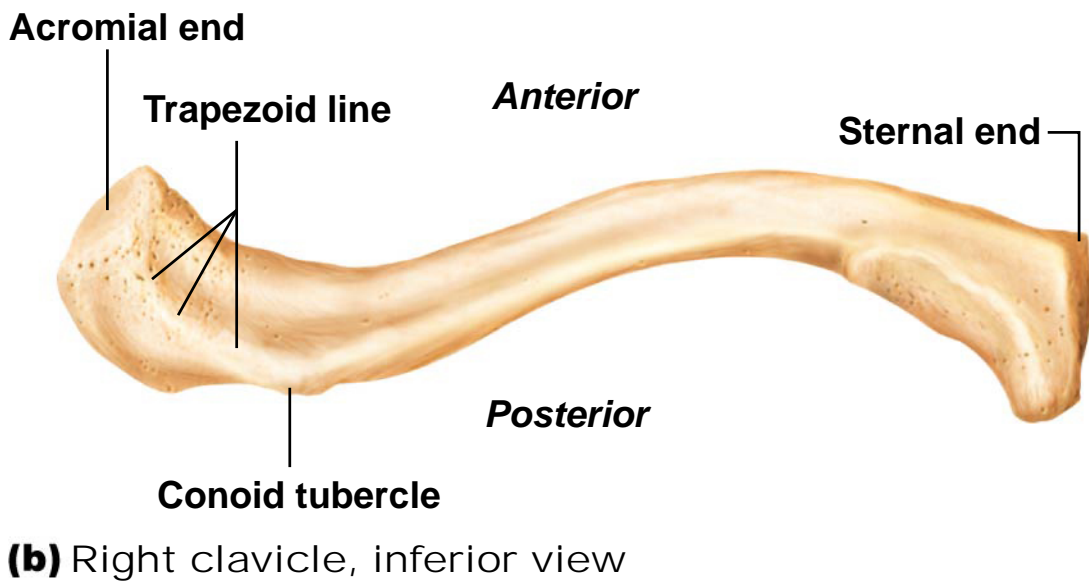
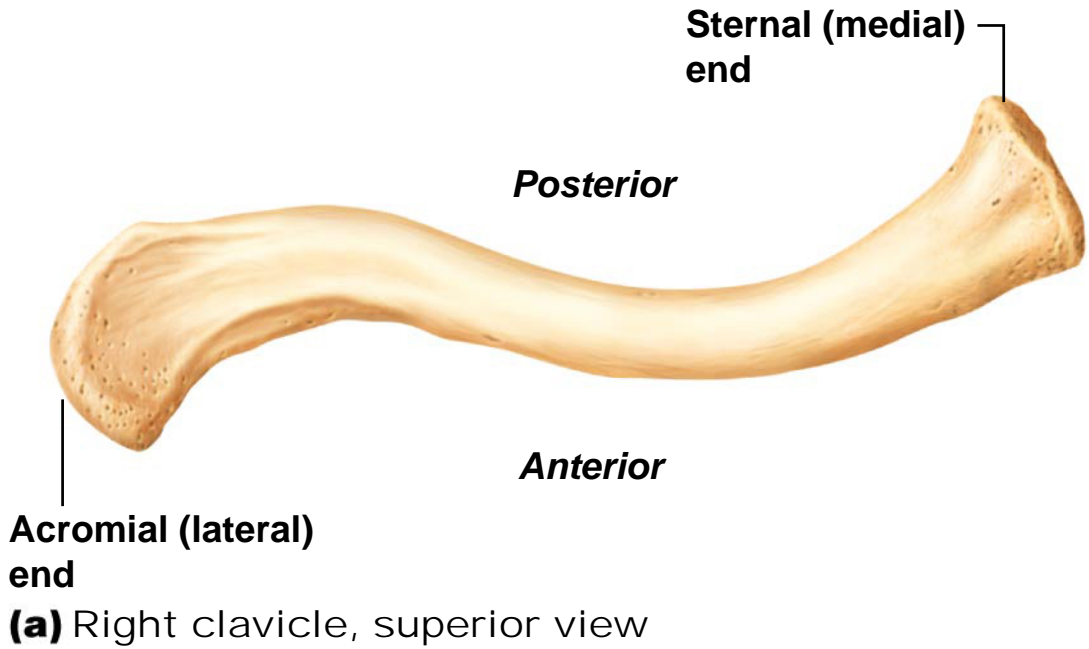
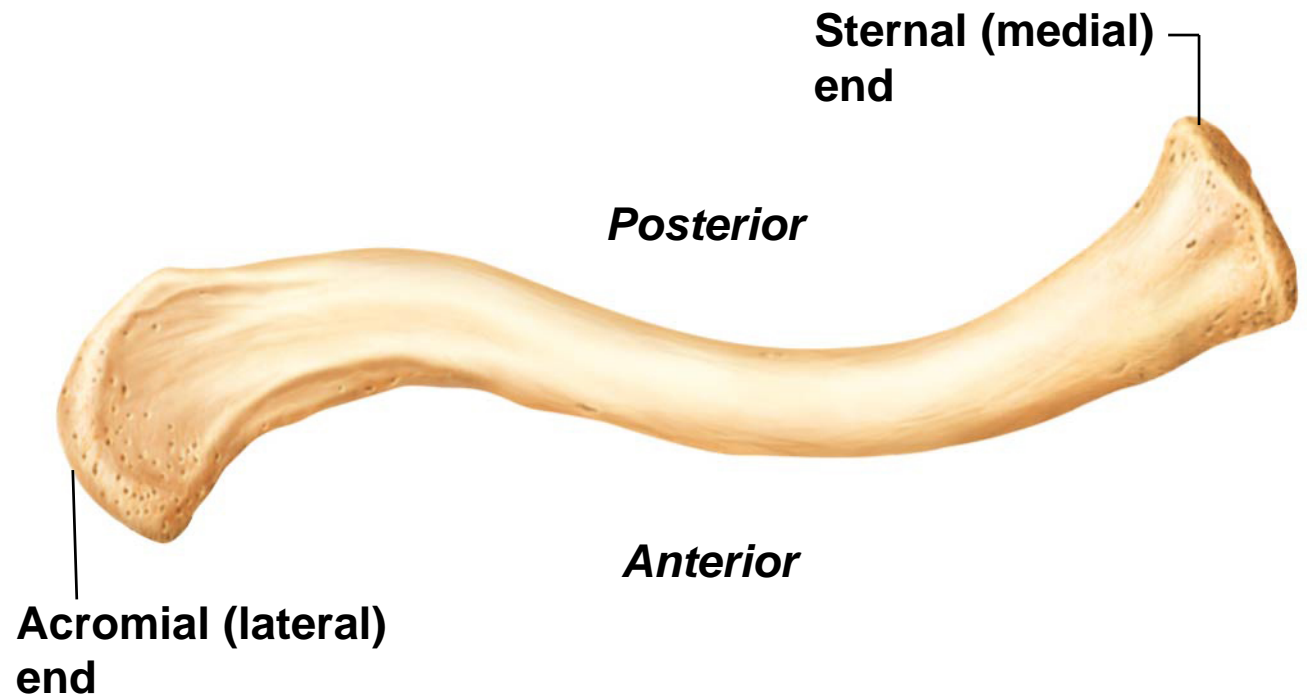
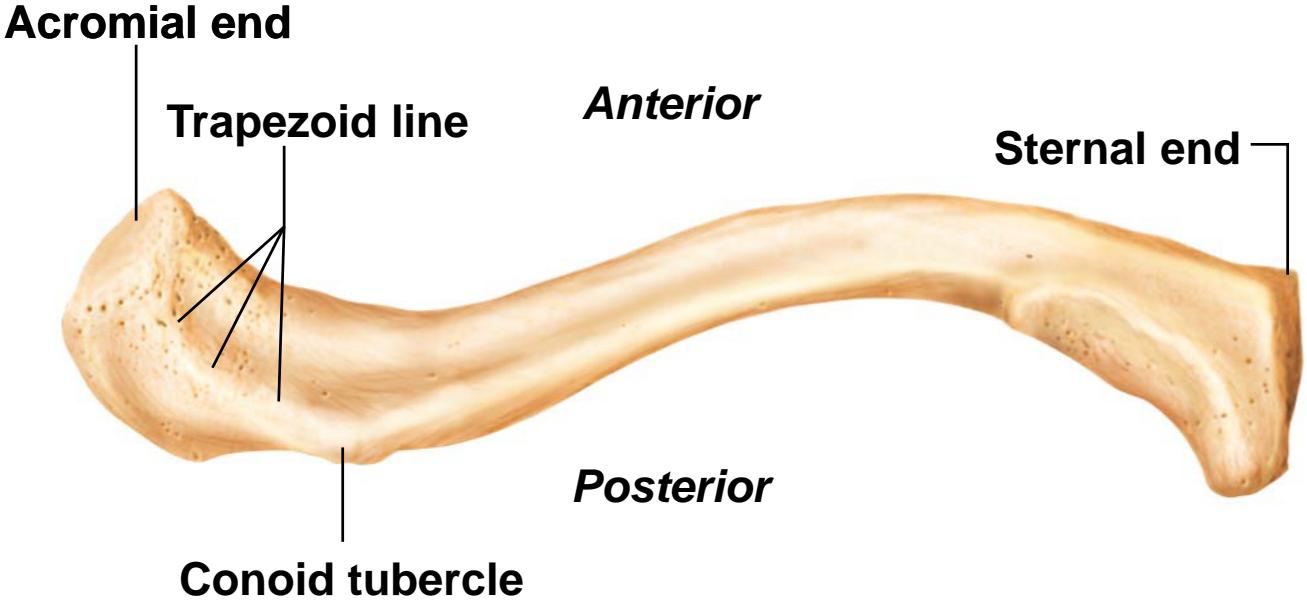


Figure 7.26a The clavicle.



**(a)** Right clavicle, superior view

Figure 7.26b The clavicle.



**(b)** Right clavicle, inferior view

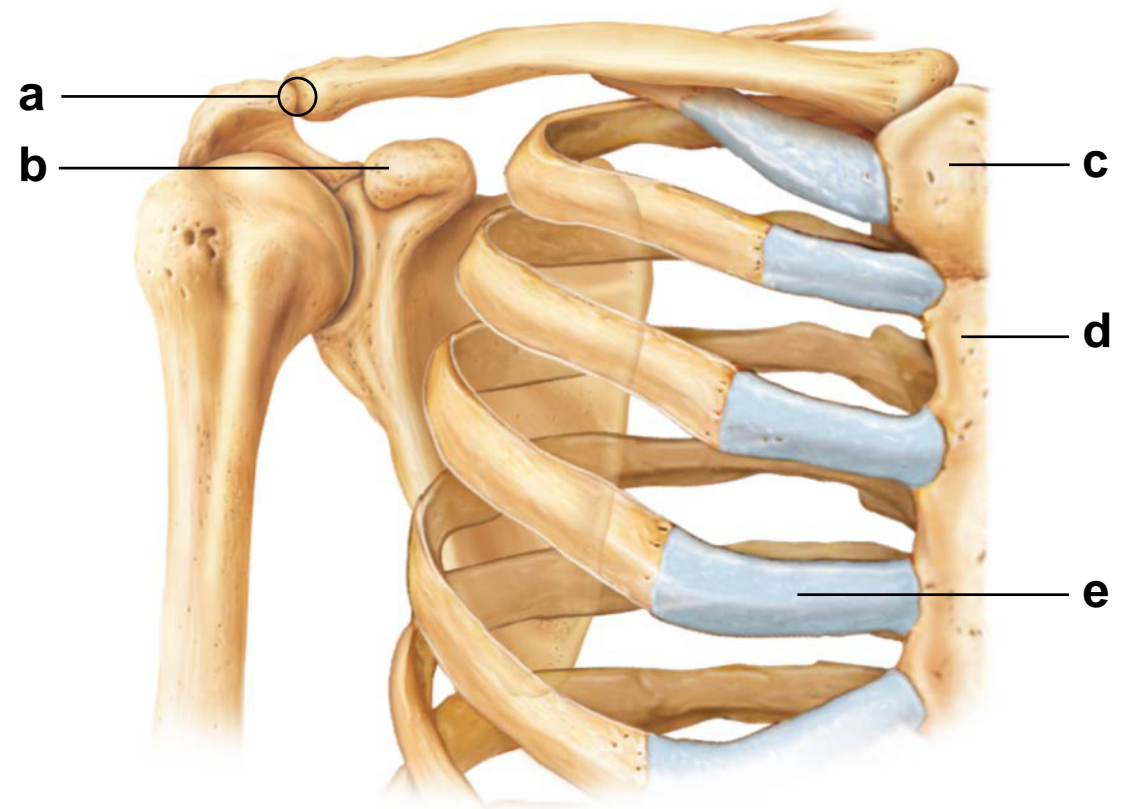
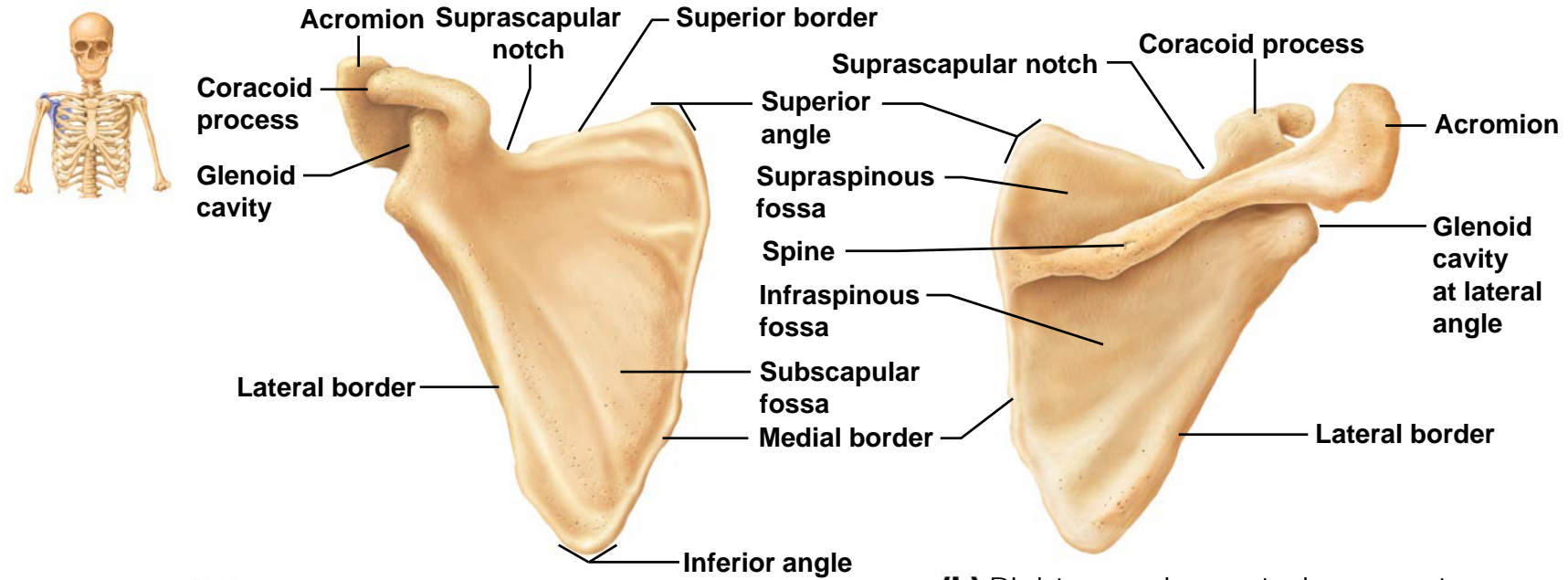
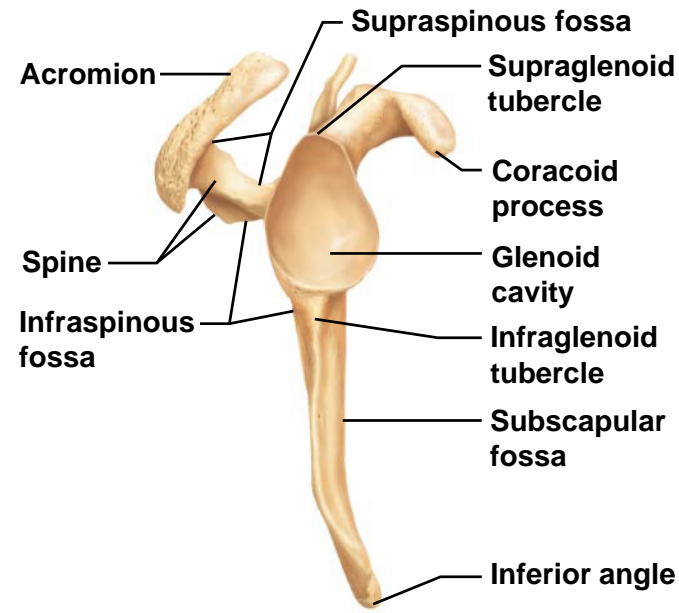
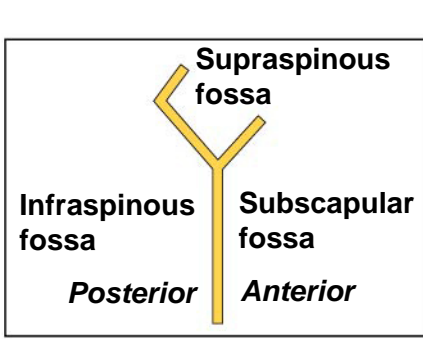


Figure 7.27 The scapula.



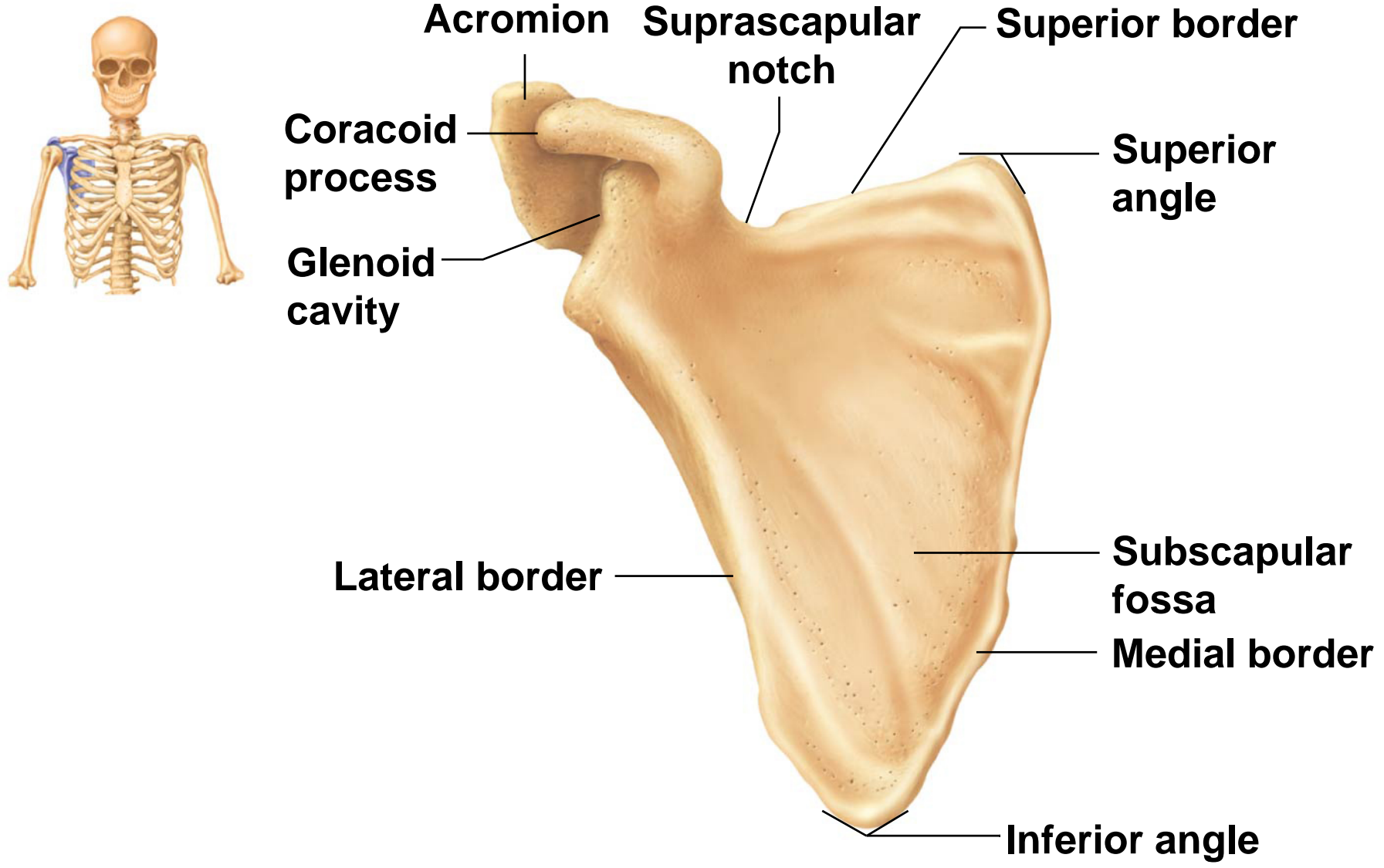
(a) Right scapula, anterior aspect

(b) Right scapula, posterior aspect

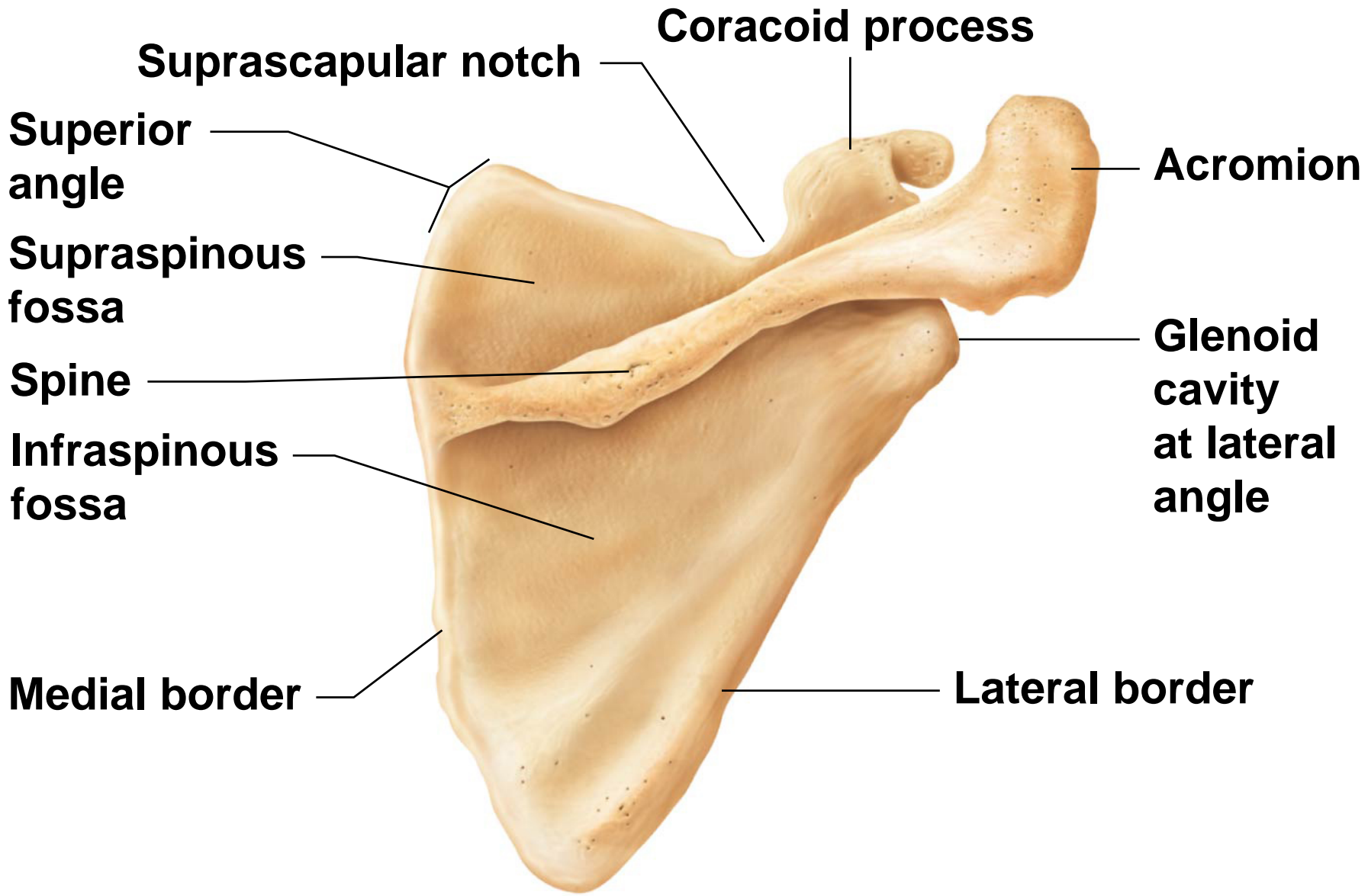


(c) Right scapula, lateral aspect

Figure 7.27a The scapula.

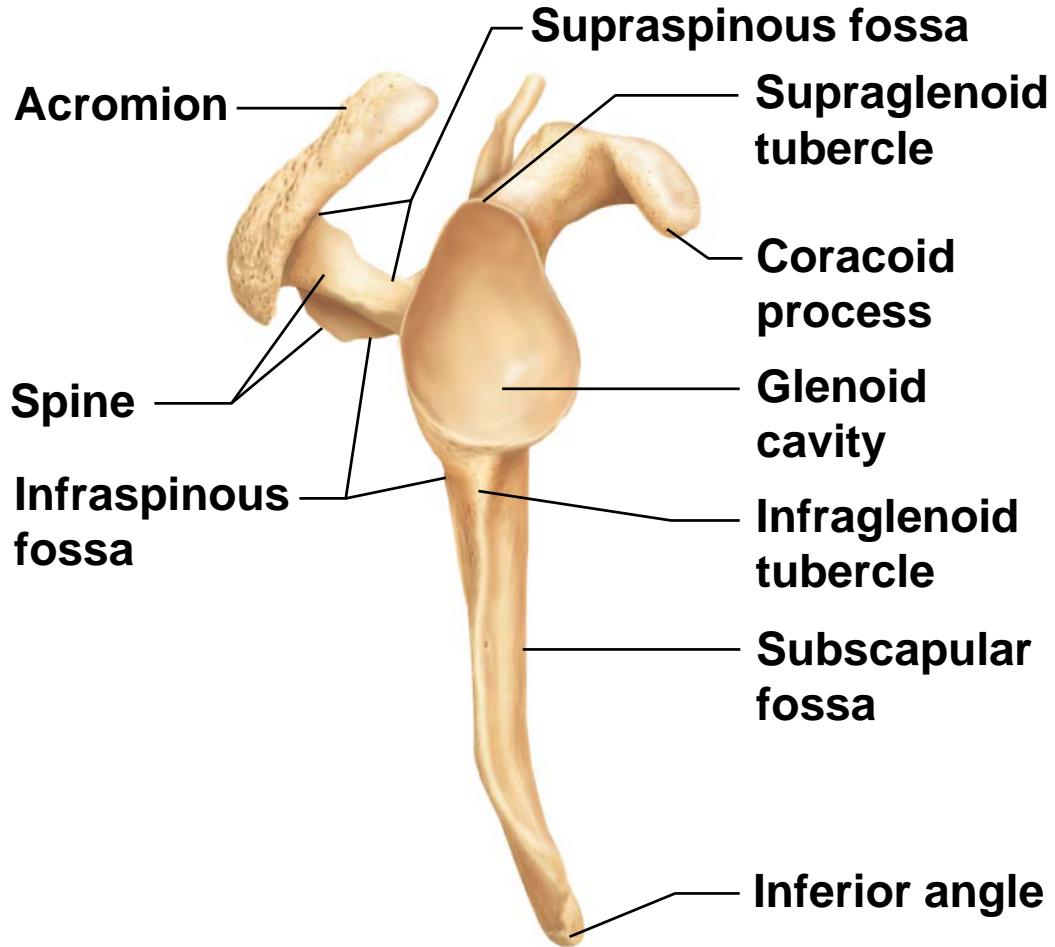
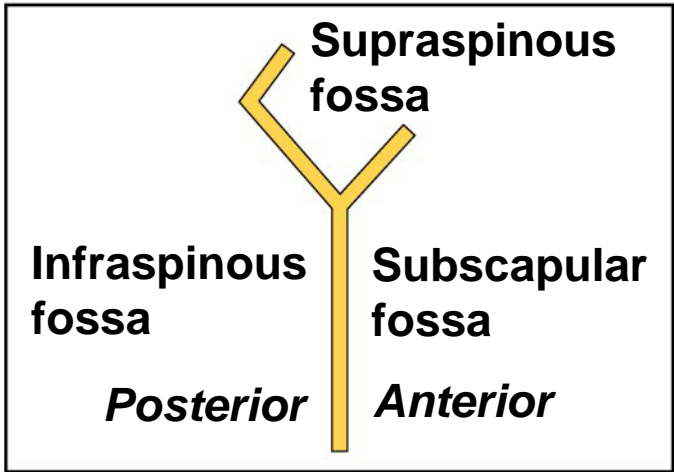


**(a)** Right scapula, anterior aspect



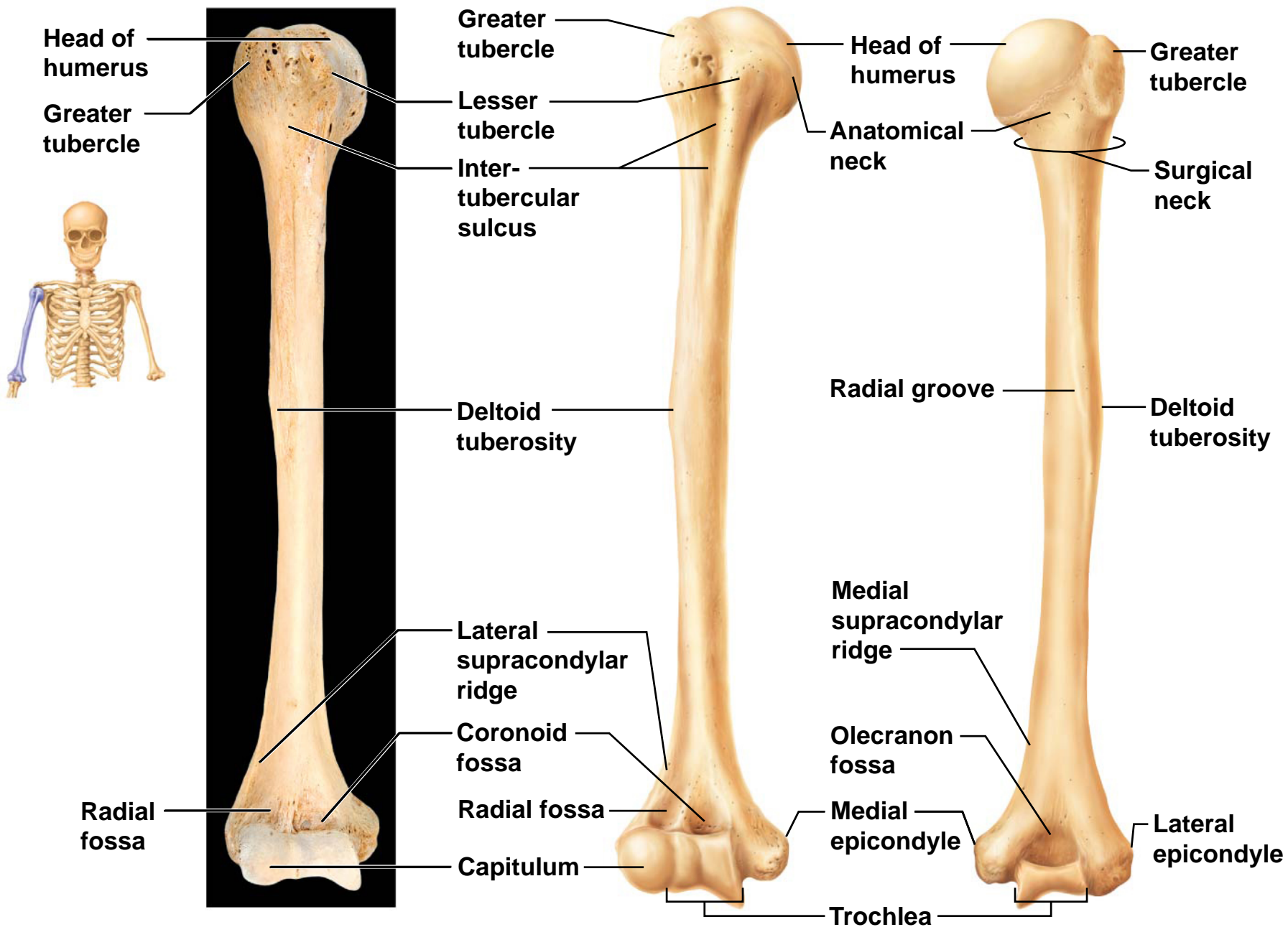
**(b)** Right scapula, posterior aspect





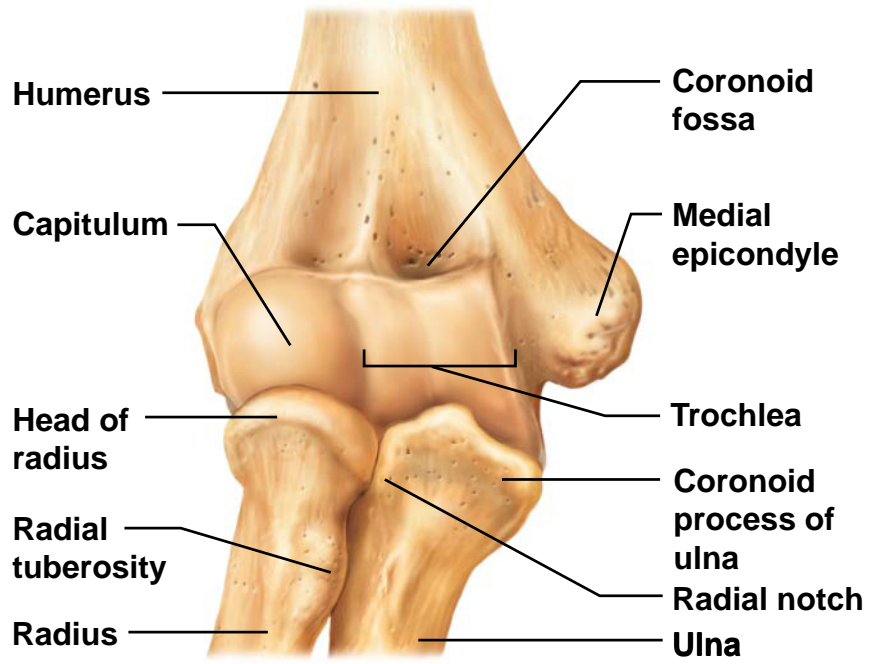
**(c)** Right scapula, lateral aspect

Figure 7.28 The humerus of the right arm and detailed views of articulation at the elbow.

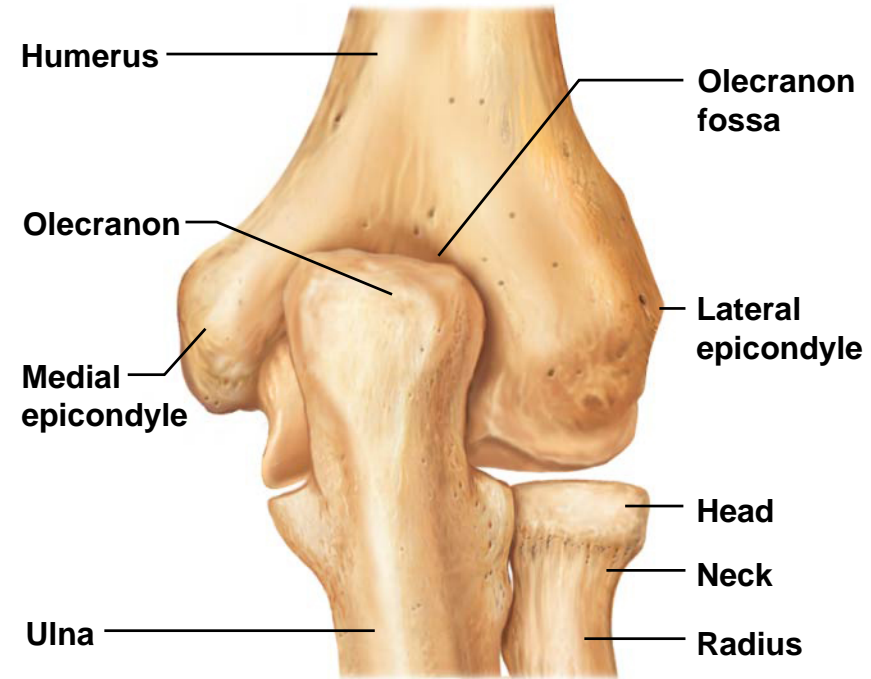


(a) Photo, anterior view    (b) Illustration, anterior view    (c) Illustration, posterior view

Figure 7.28 The humerus of the right arm and detailed views of articulation at the elbow (continued).

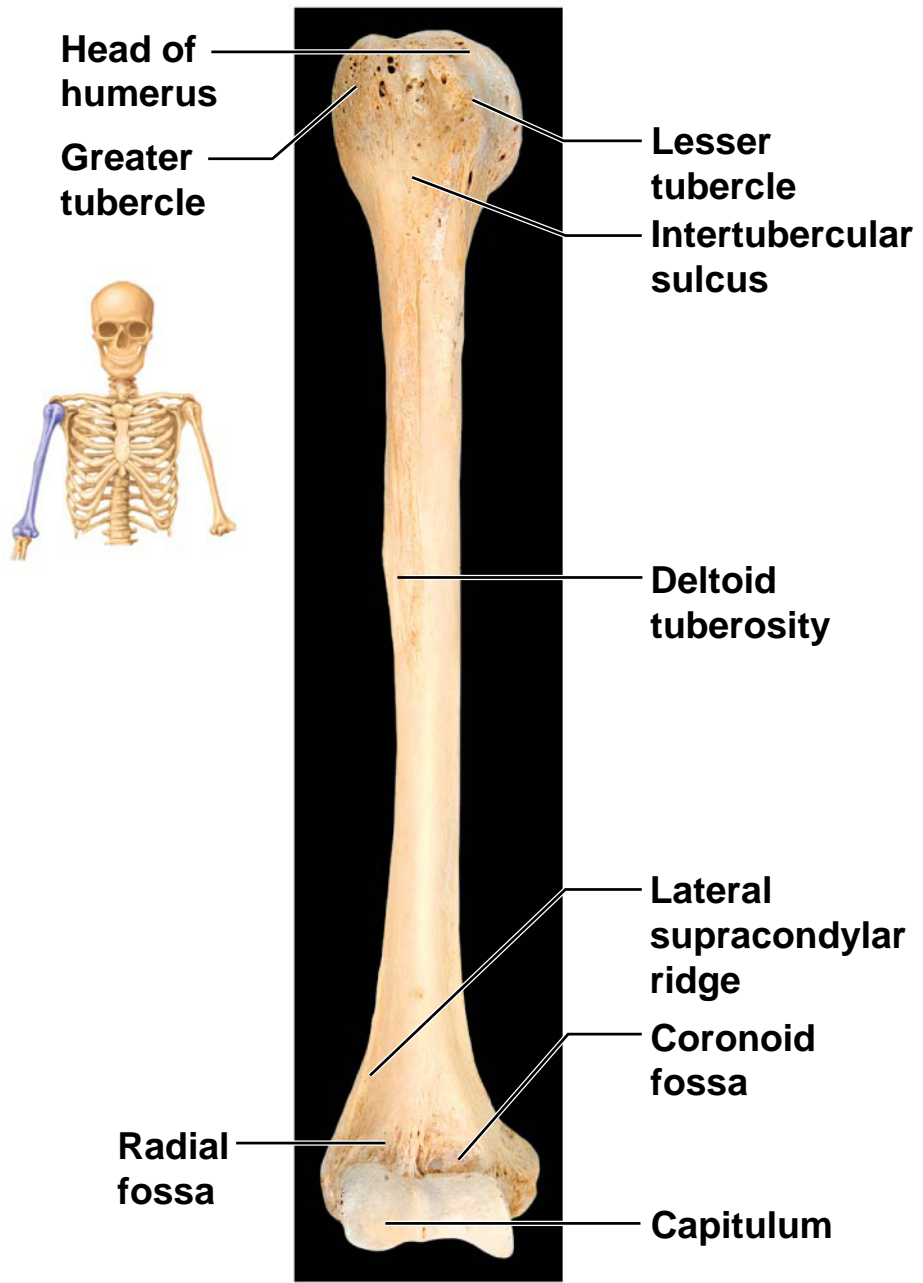


(d) Anterior view at the elbow region



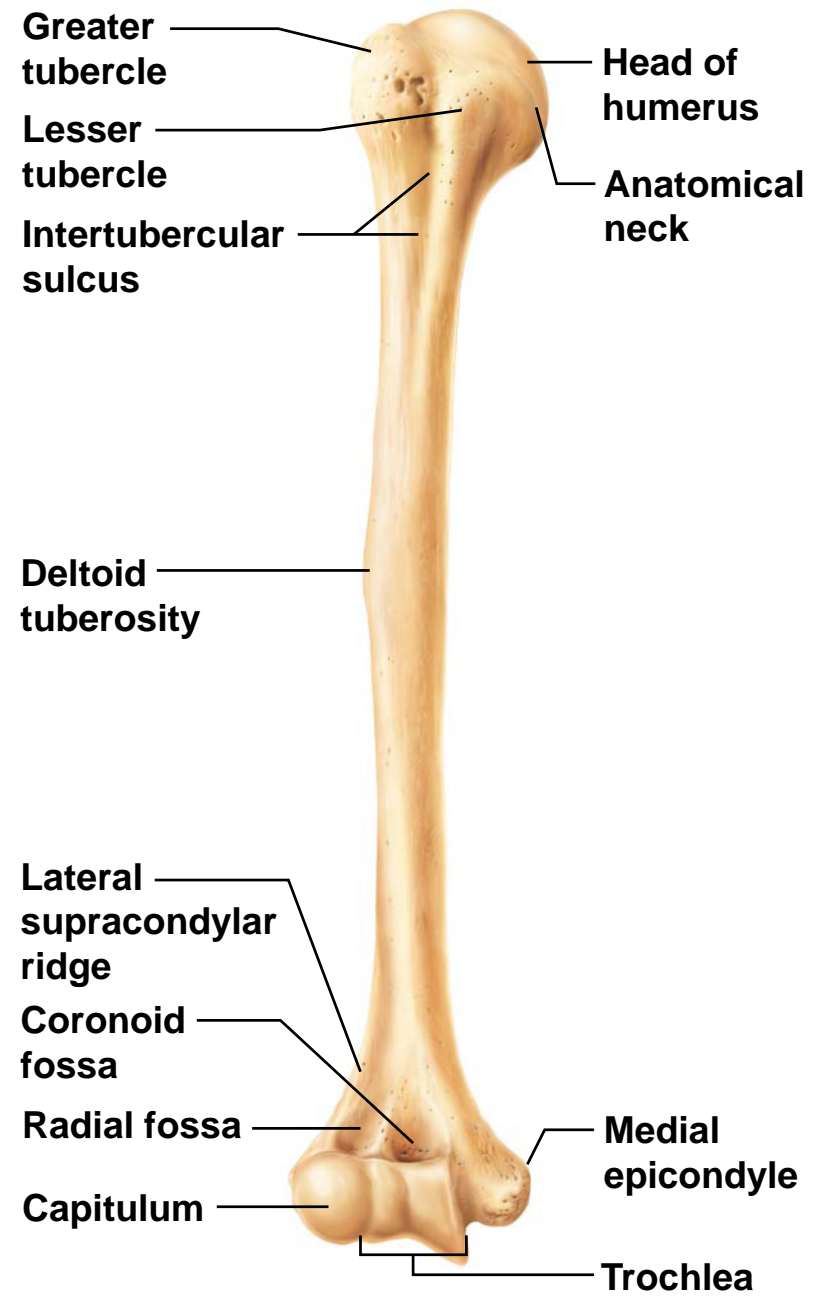
(e) Posterior view of extended elbow

Figure 7.28a The humerus of the right arm and detailed views of articulation at the elbow.



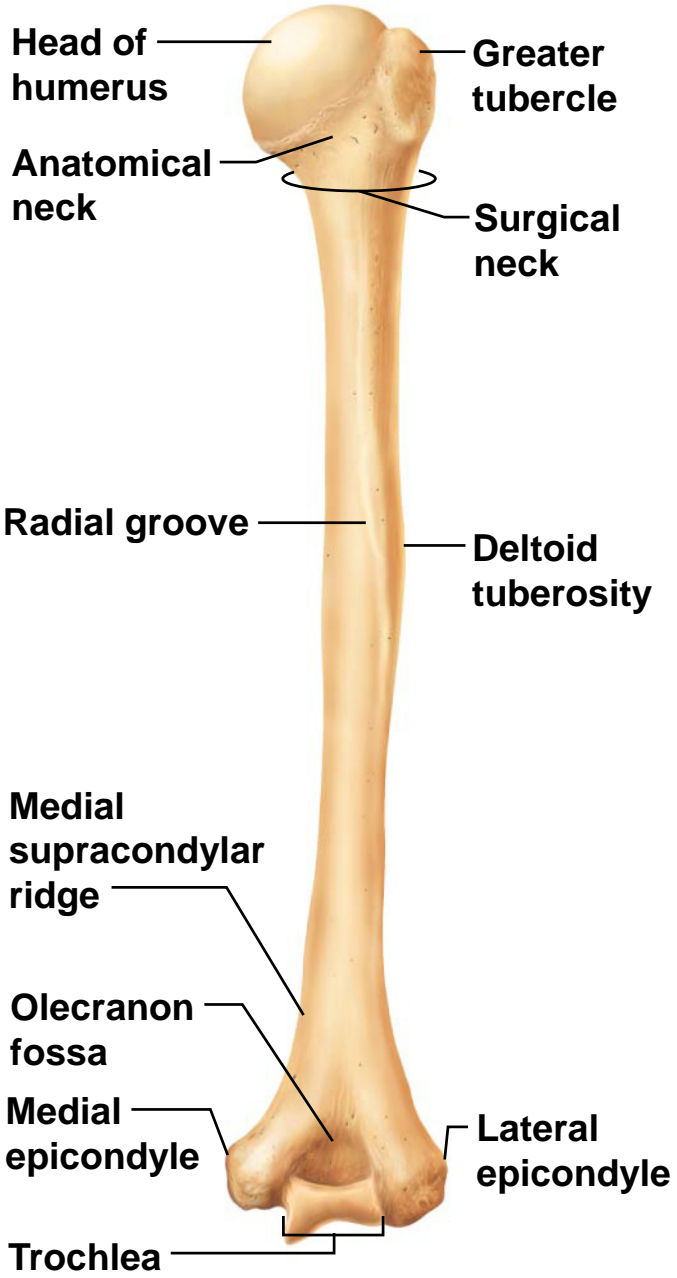
(a) Photo, anterior view

Figure 7.28b The humerus of the right arm and detailed views of articulation at the elbow.



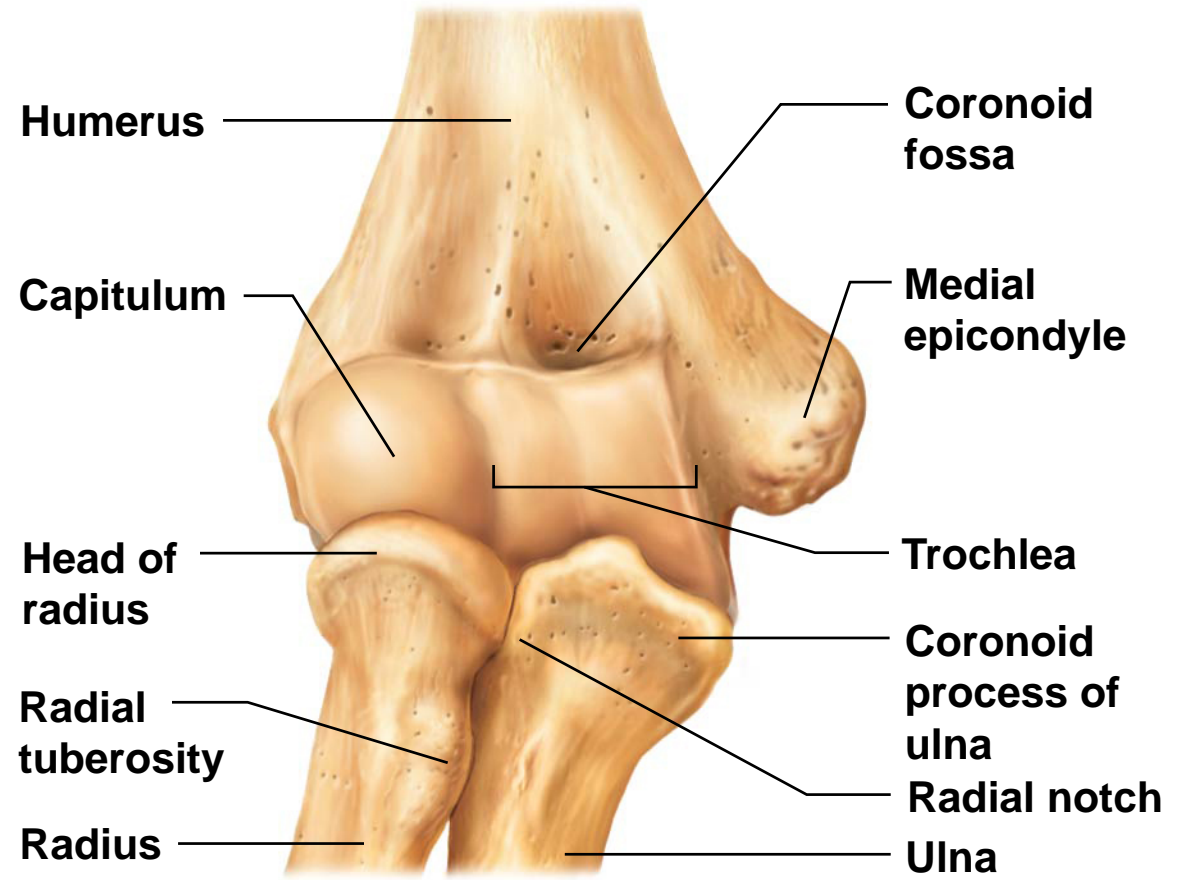
(b) Illustration, anterior view

Figure 7.28c The humerus of the right arm and detailed views of articulation at the elbow.



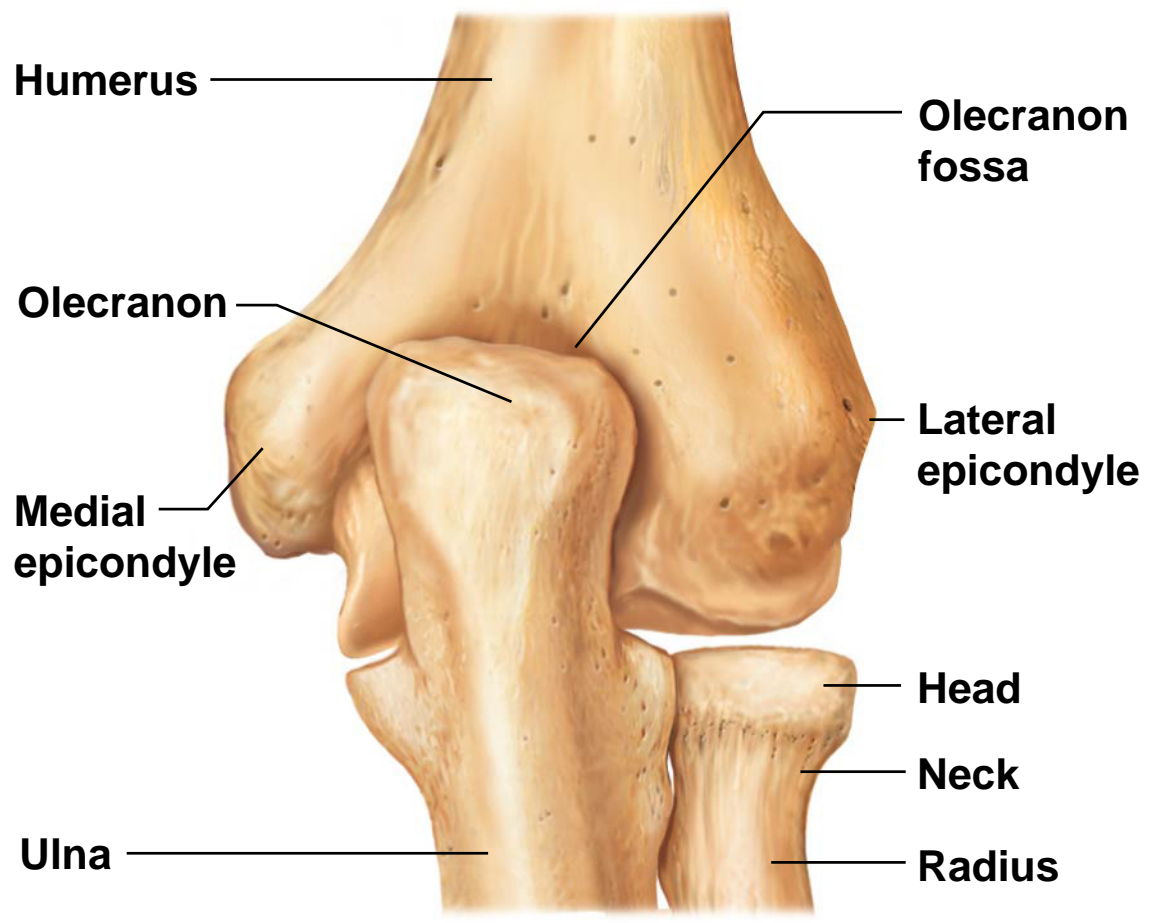
(c) Illustration, posterior view

Figure 7.28d The humerus of the right arm and detailed views of articulation at the elbow.



**(d)** Anterior view at the elbow region

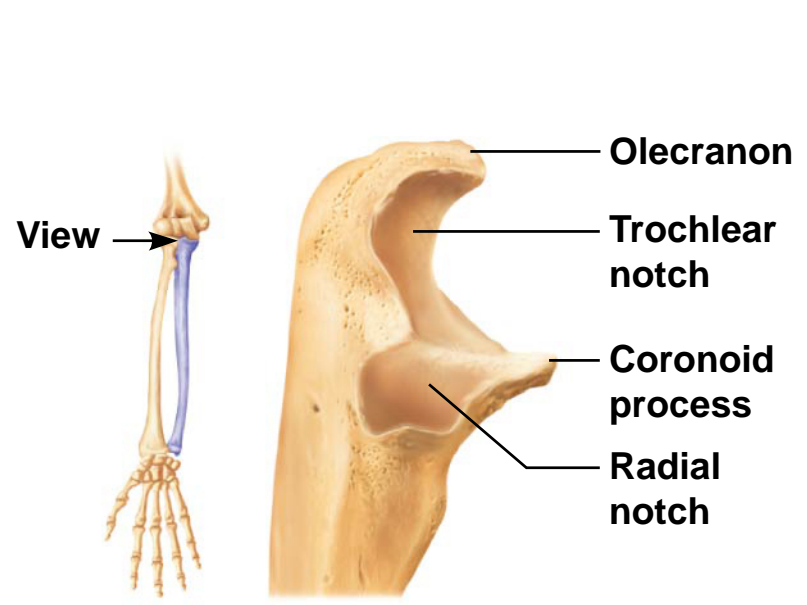
Figure 7.28e The humerus of the right arm and detailed views of articulation at the elbow.



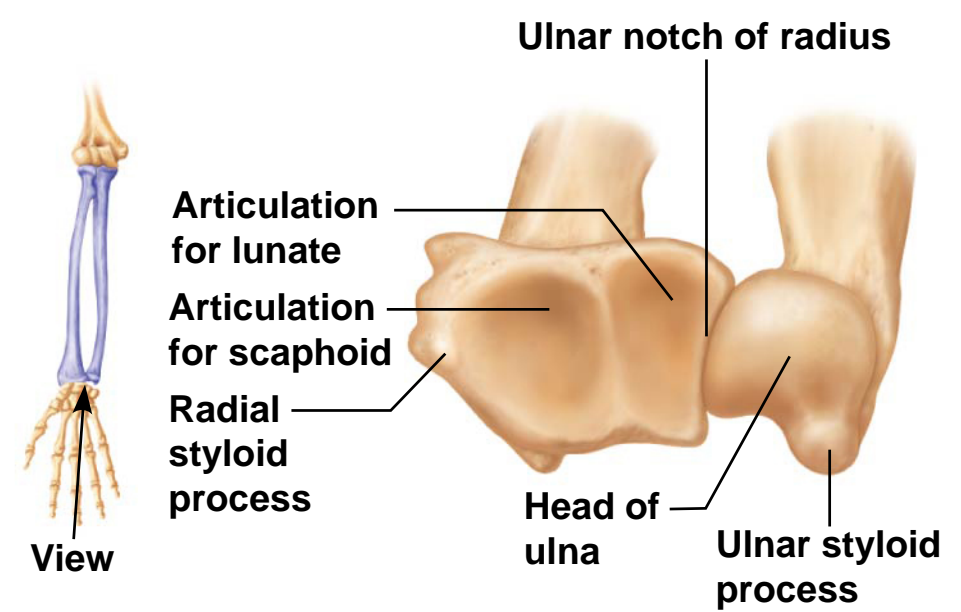
**(e)** Posterior view of extended elbow





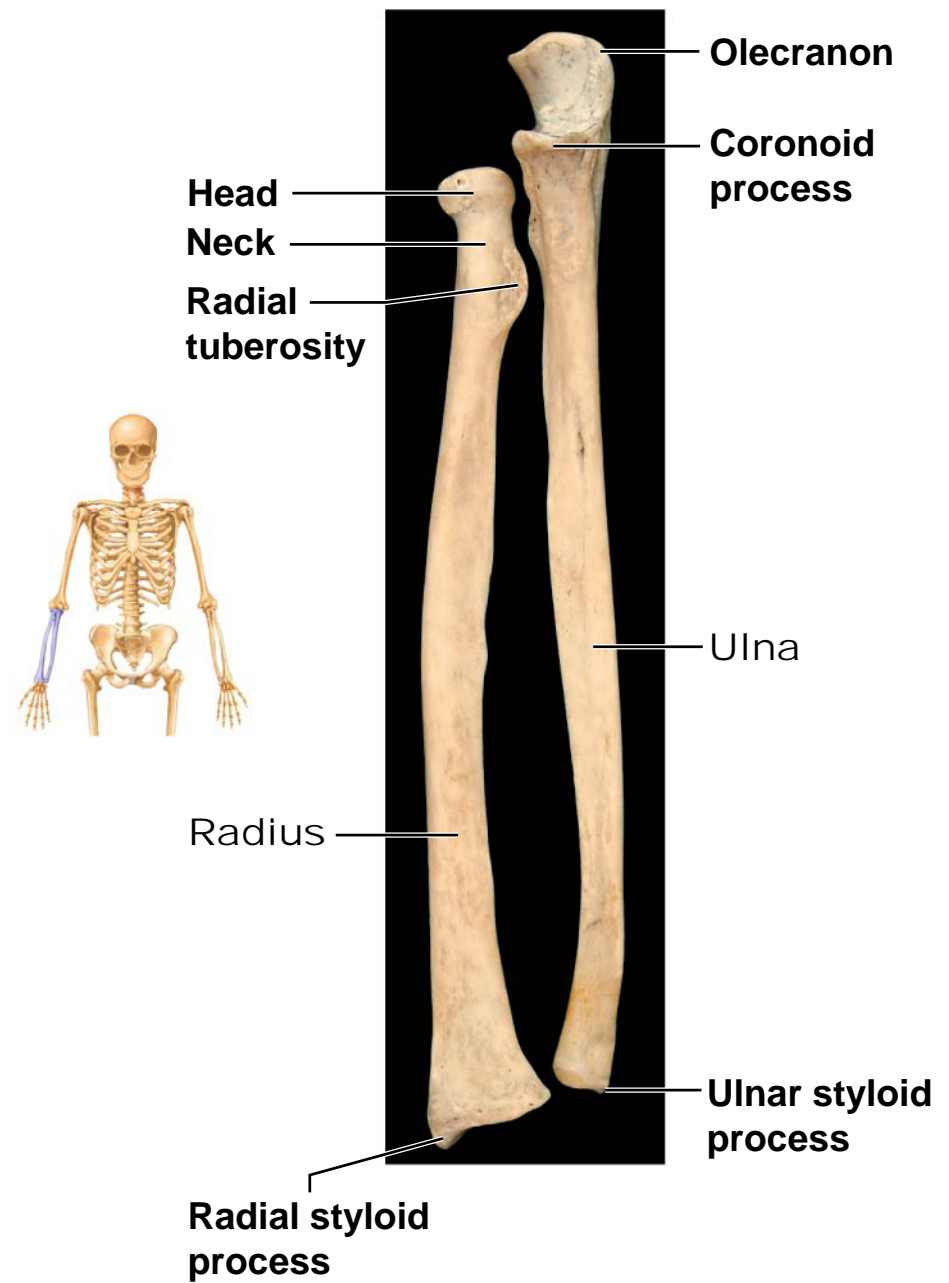


**(d)** Proximal portion of ulna, lateral view



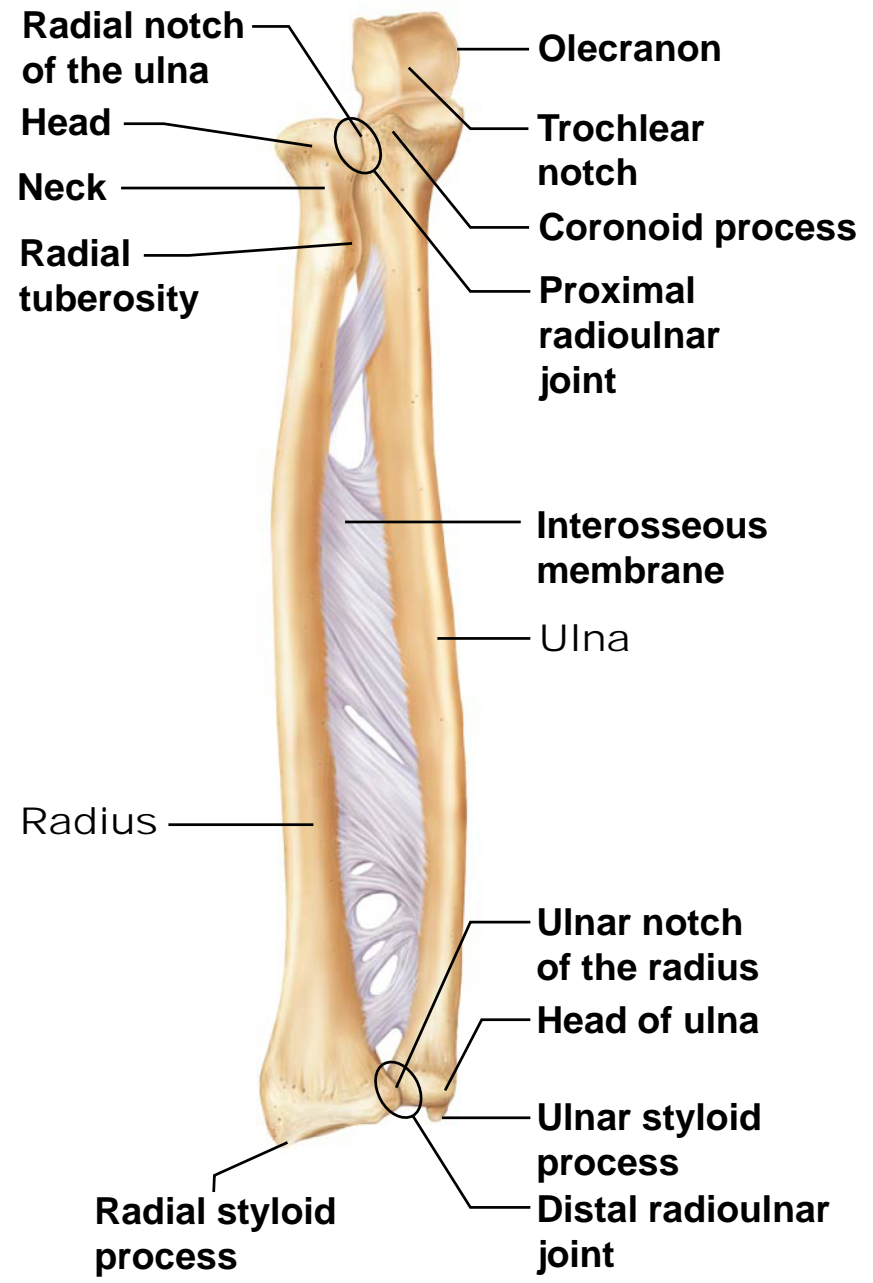
**(e)** Distal ends of the radius and ulna at the wrist

Figure 7.29a Radius and ulna of the right forearm.



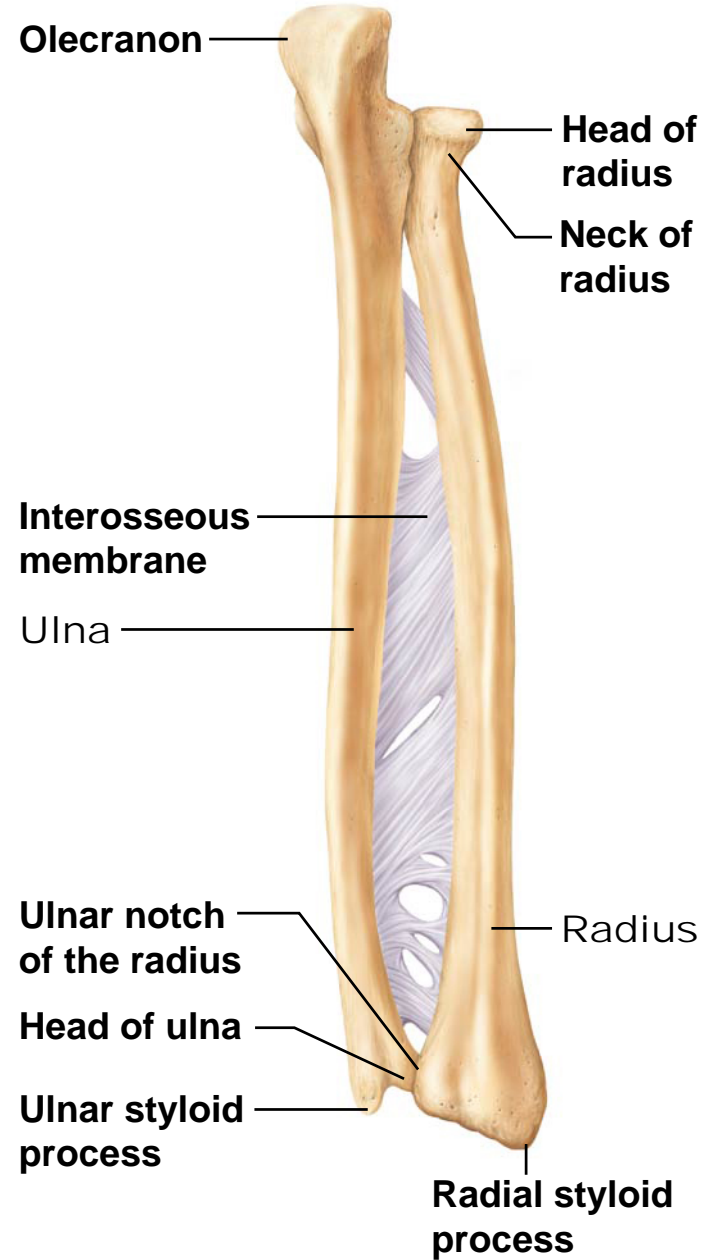
(a) Photo, anterior view

Figure 7.29b Radius and ulna of the right forearm.



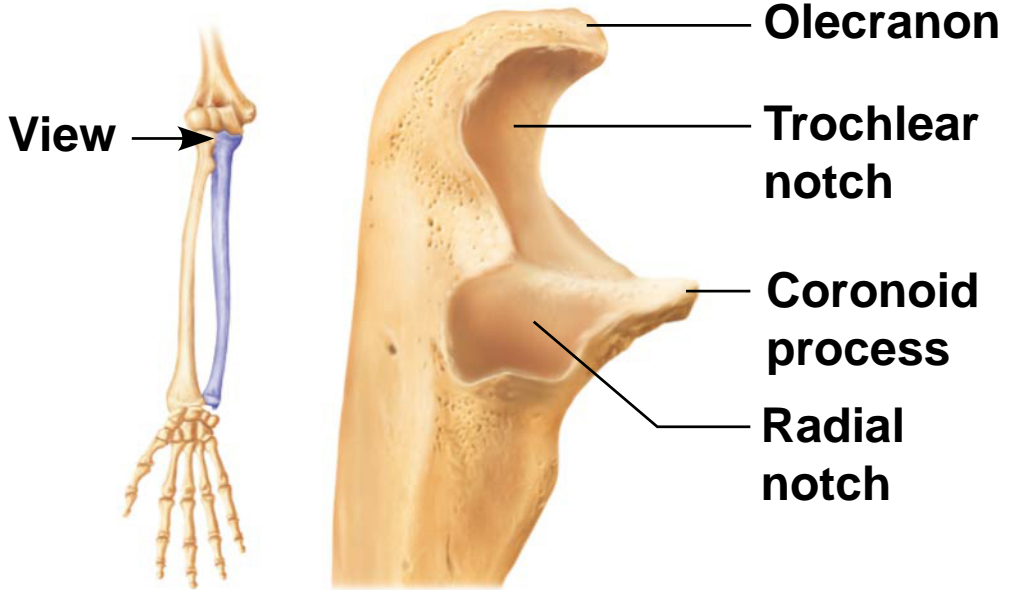
(b) Illustration, anterior view

Figure 7.29c Radius and ulna of the right forearm.



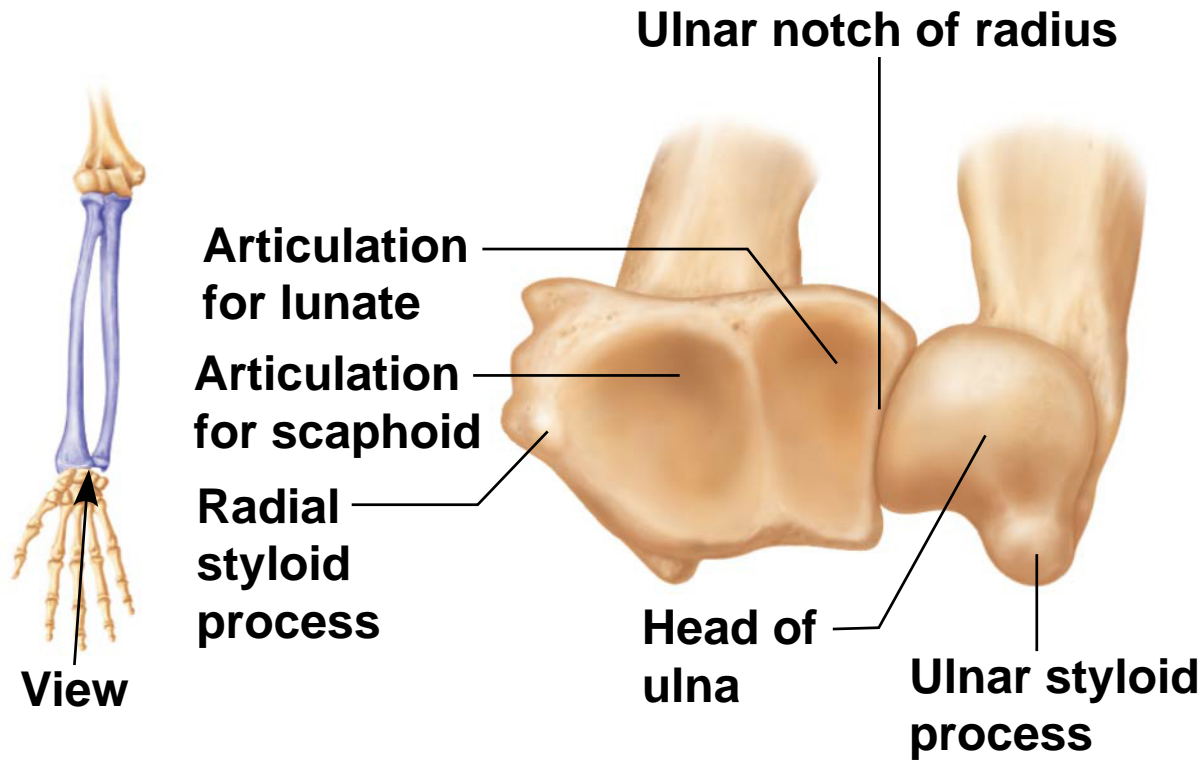
(c) Illustration, posterior view

Figure 7.29d Radius and ulna of the right forearm.



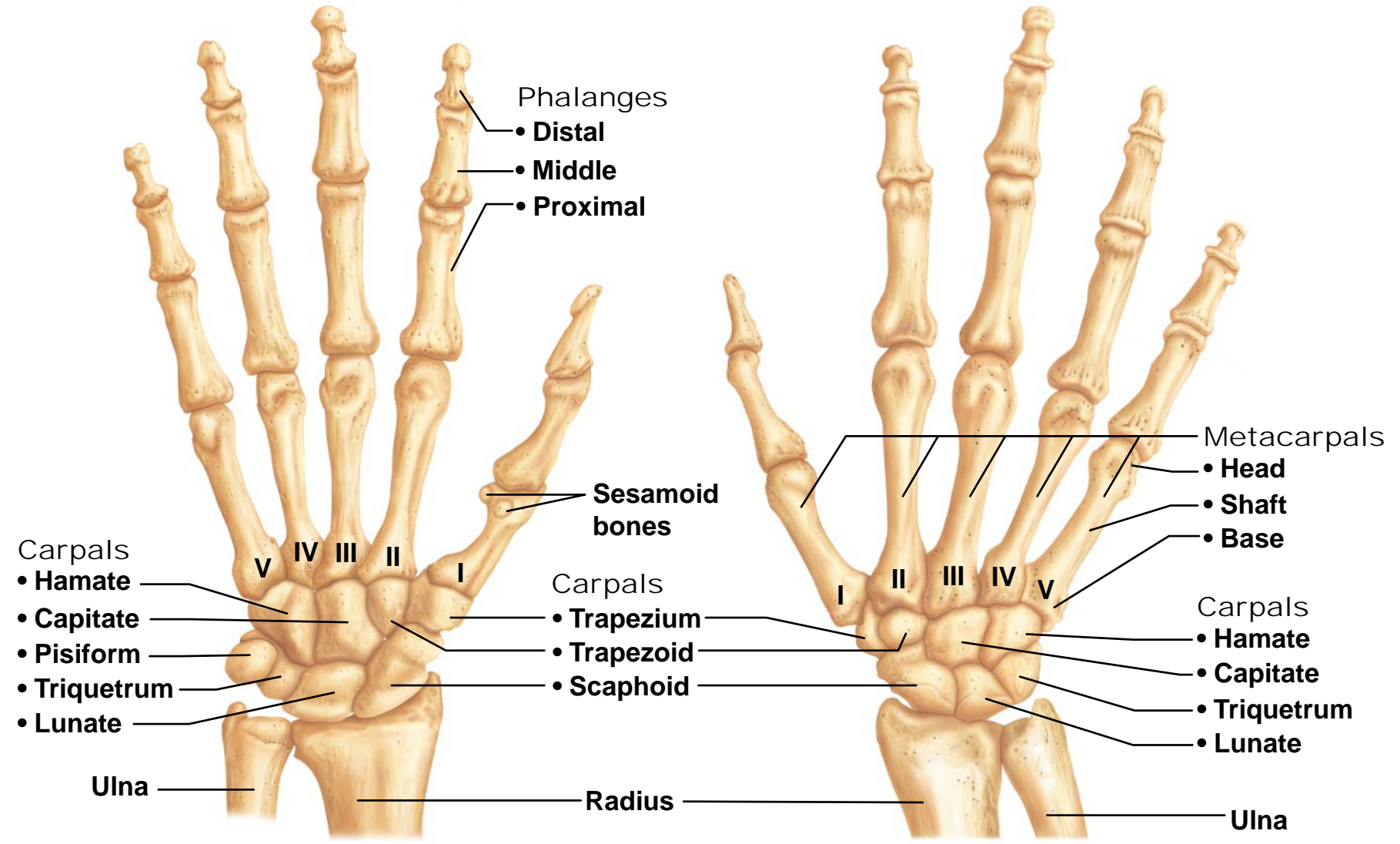
**(d)** Proximal portion of ulna, lateral view

Figure 7.29e Radius and ulna of the right forearm.



**(e)** Distal ends of the radius and ulna at the wrist

Figure 7.30 Bones of the right hand.

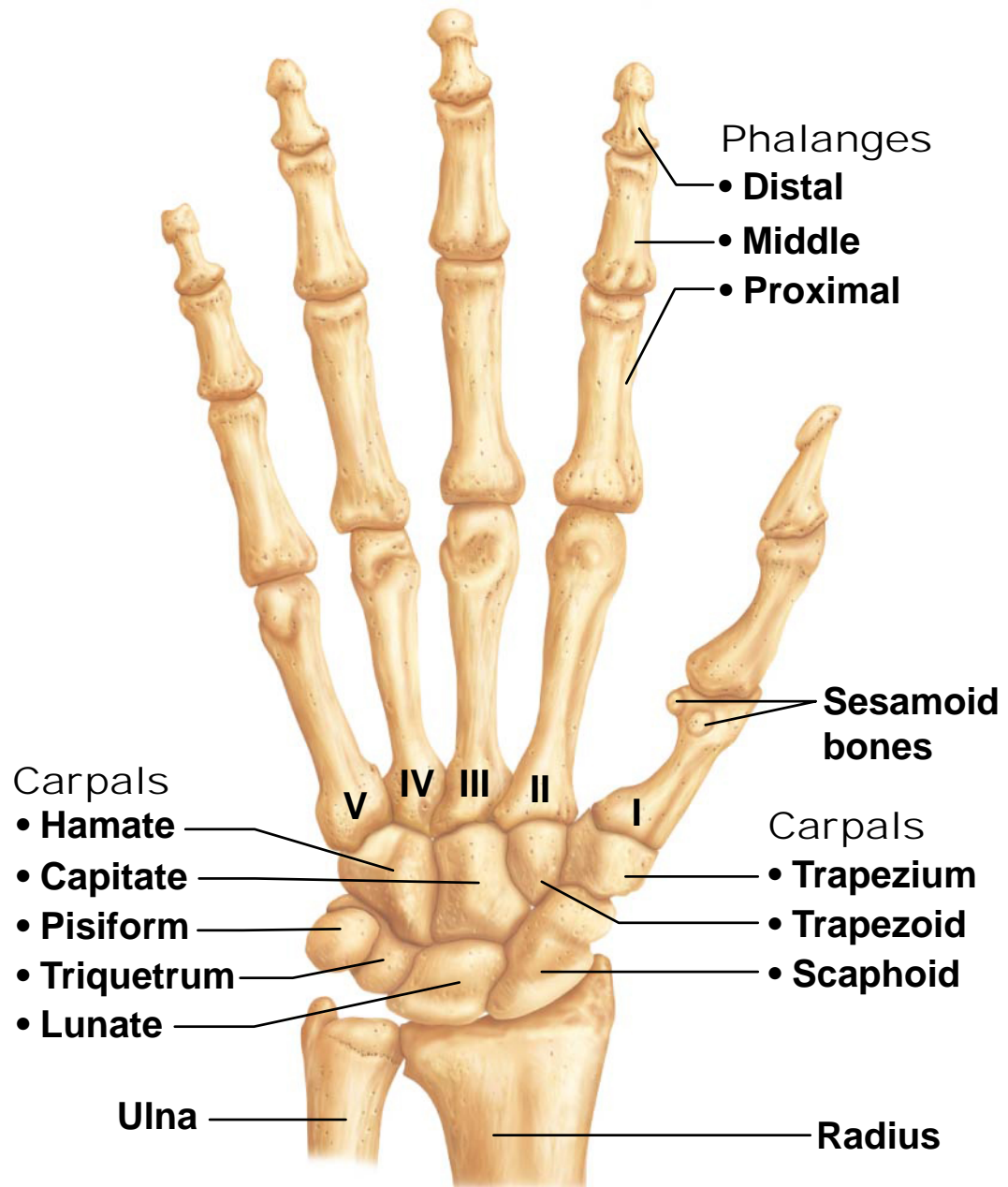


(a) Anterior view

(b) Posterior view

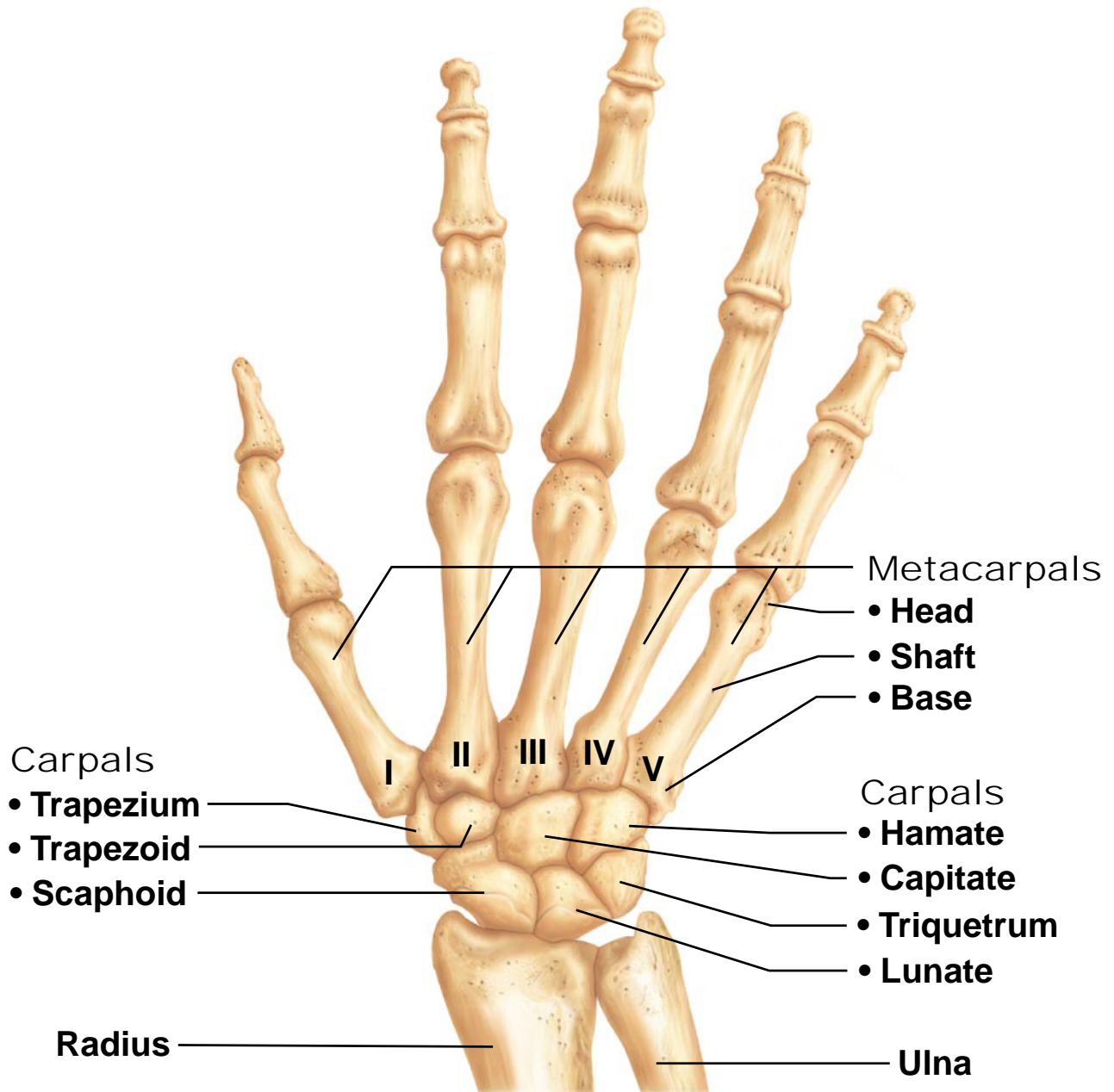


Figure 7.30a Bones of the right hand.



(a) Anterior view

Figure 7.30b Bones of the right hand.



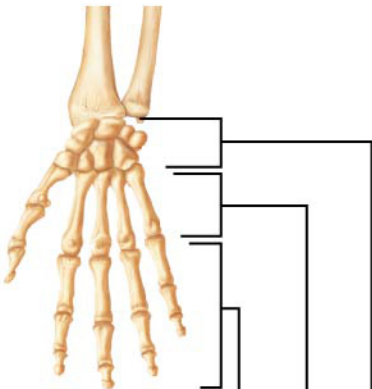
(b) Posterior view

**Table 7.3-1 Bones of the Appendicular Skeleton, Part 1: Pectoral Girdle and Upper Limb**

Table 7.3 Bones of the Appendicular Skeleton, Part 1: Pectoral Girdle and Upper Limb					
BODY REGION	BONES*	ILLUSTRATION	LOCATION	MARKINGS	
<b>Pectoral girdle</b> (Figures 7.25, 7.26, 7.27)	<b>Clavicle (2)</b>		Clavicle is in superoanterior thorax; articulates medially with sternum and laterally with scapula	Acromial end; sternal end	
	<b>Scapula (2)</b>		Scapula is in posterior thorax; forms part of the shoulder; articulates with humerus and clavicle	Glenoid cavity; spine; acromion; coracoid process; infraspinous, supraspinous, and subscapular fossae	
<b>Upper limb</b> Arm (Figure 7.28)	<b>Humerus (2)</b>		Humerus is sole bone of arm; between scapula and elbow	Head; greater and lesser tubercles; intertubercular sulcus; radial groove; deltoid tuberosity; trochlea; capitulum; coronoid and olecranon fossae; epicondyles; radial fossa	
	Forearm (Figure 7.29)		<b>Ulna (2)</b>	Ulna is the medial bone of forearm between elbow and wrist; with the humerus (and radius) forms elbow joint	Coronoid process; olecranon; radial notch; trochlear notch; ulnar styloid process; head
			<b>Radius (2)</b>	Radius is the lateral bone of forearm; articulates with carpals to form part of the wrist joint	Head; radial tuberosity; radial styloid process; ulnar notch

*Anterior view of pectoral girdle and upper limb*

\*The number in parentheses ( ) following the bone name denotes the total number of such bones in the body.

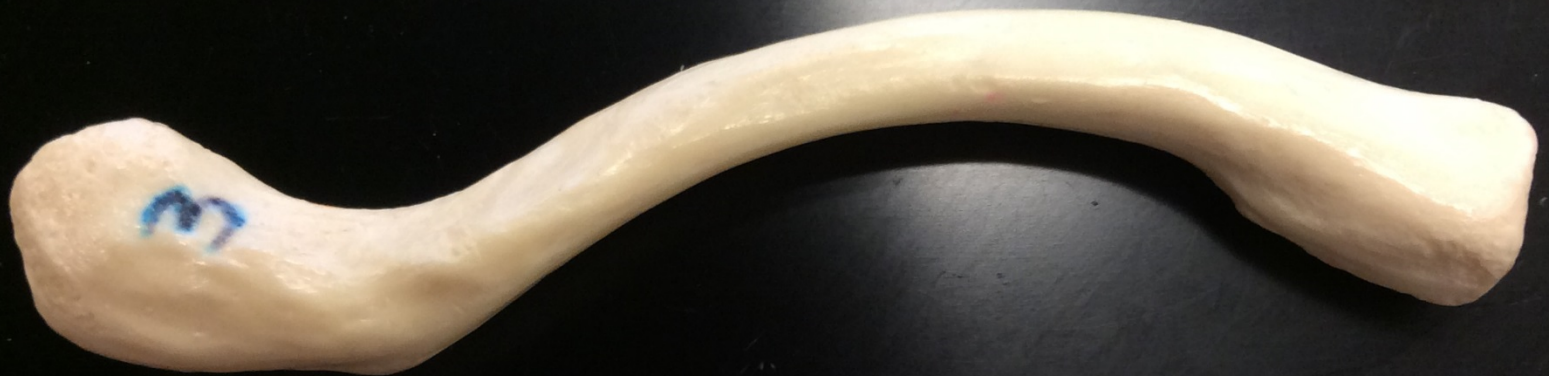Table 7.3	Bones of the Appendicular Skeleton, Part 1: Pectoral Girdle and Upper Limb (continued)			
BODY REGION	BONES*	ILLUSTRATION	LOCATION	MARKINGS
Hand (Figure 7.30)	<p>8 <b>Carpals</b> (16)                      scaphoid                      lunate                      triquetrum                      pisiform                      trapezium                      trapezoid                      capitate                      hamate</p> <p>5 <b>Metacarpals</b> (10)</p> <p>14 <b>Phalanges</b> (28)                      distal                      middle                      proximal</p> <p><i>Anterior view of the hand</i></p>		<p>Carpals form a bony crescent at the wrist; arranged in two rows of four bones each</p> <p>Metacarpals form the palm; one in line with each digit</p> <p>Phalanges form the fingers; three in digits II–V; two in digit I (the thumb)</p>	

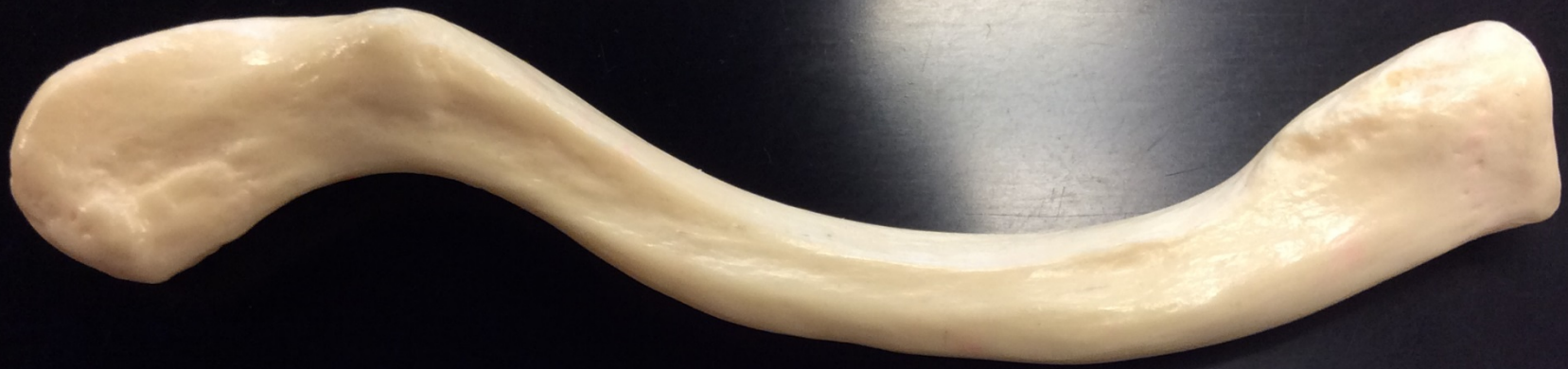\*The number in parentheses ( ) following the bone name denotes the total number of such bones in the body.

Use the following pictures to help you practice finding the terms from the lab term handout on unlabeled images.

- Remember, you won't learn them if you don't take plenty of time to practice!
- Also, be sure to mix up the order once you get comfortable with the unlabeled slides.
- Over the weekend, once you are feeling confident with the pictures here, do the bone model quizzes in PAL (from the Pearson website) to get practice with new pictures that you haven't seen.

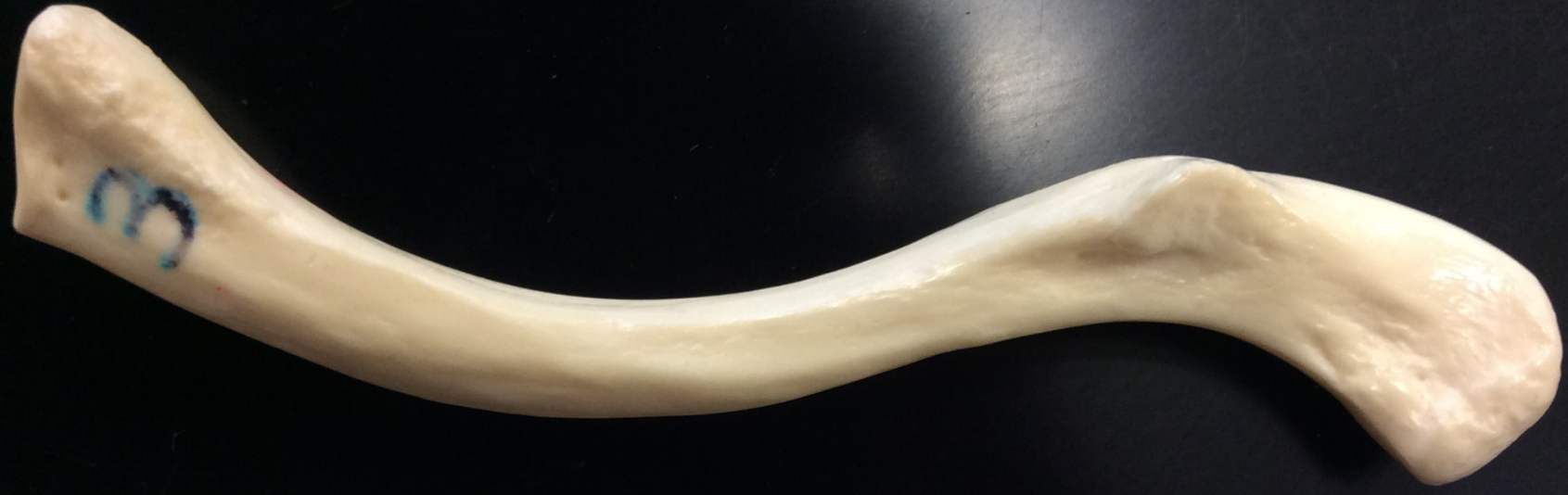# Pectoral Girdle

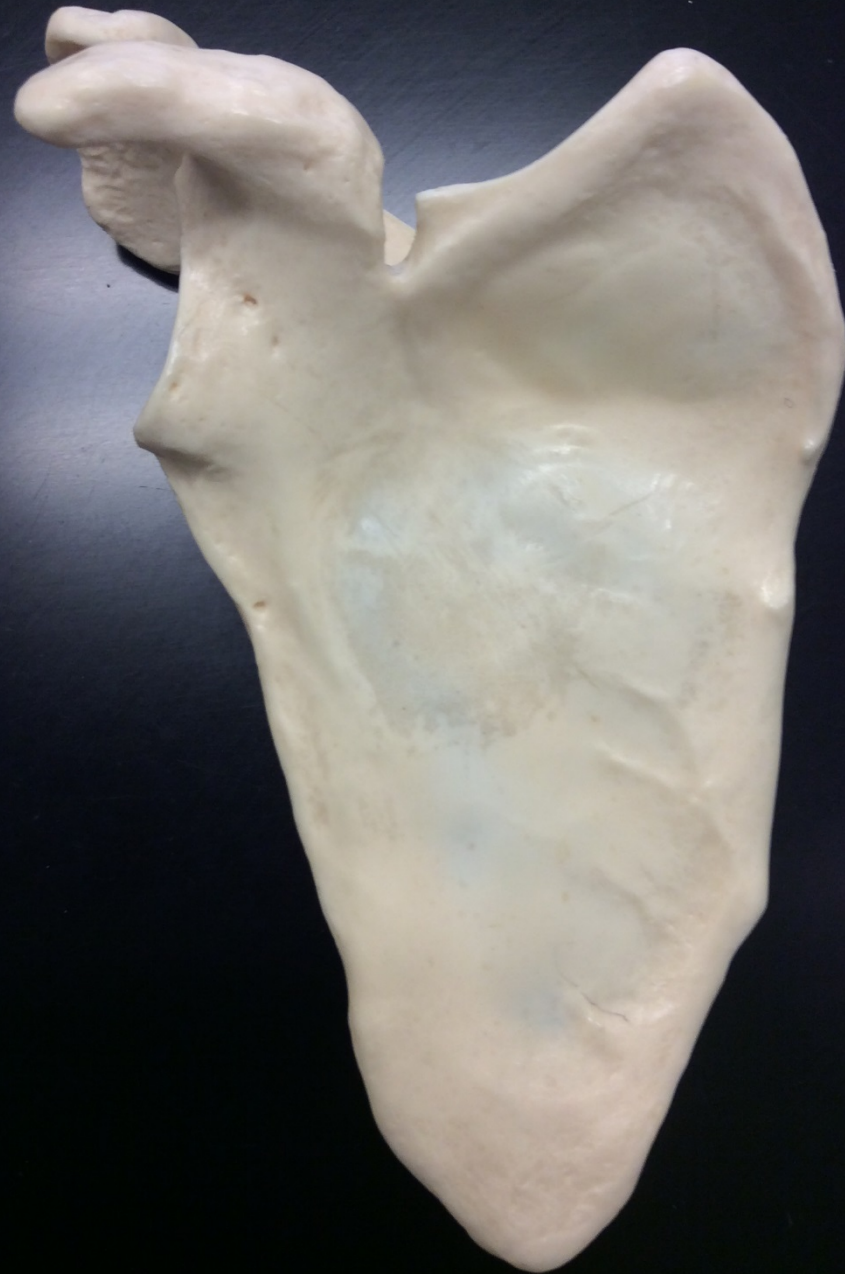


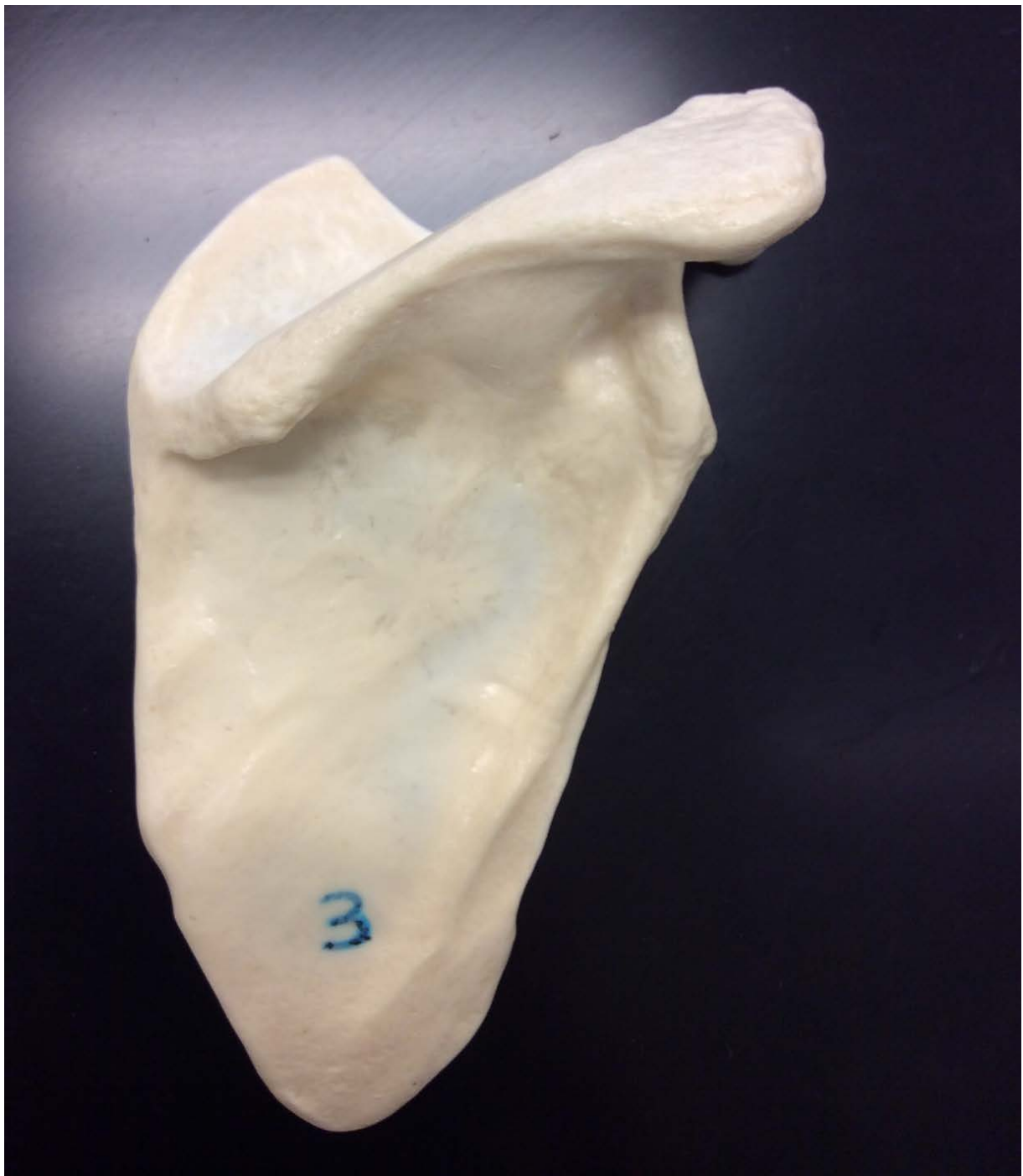


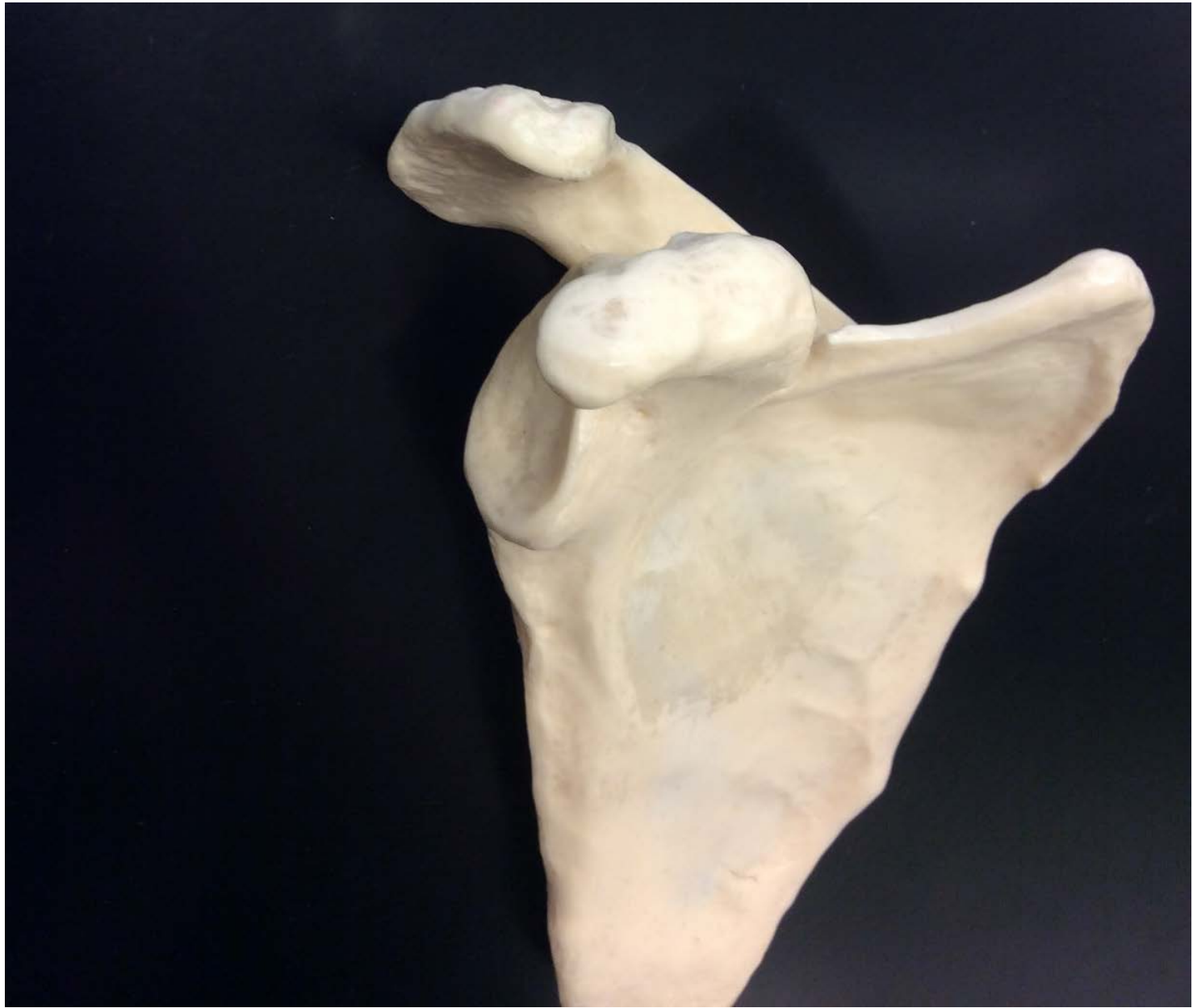

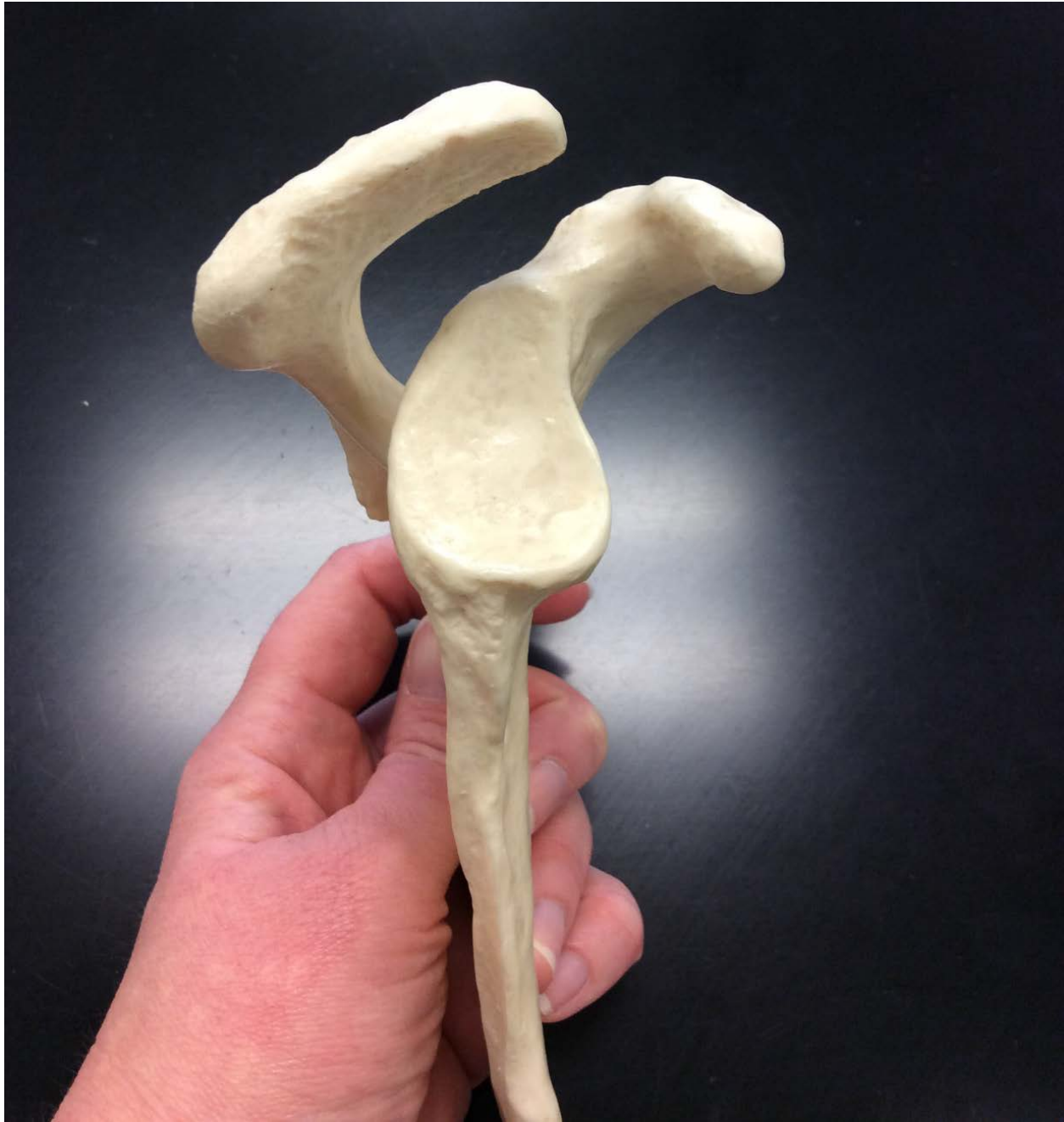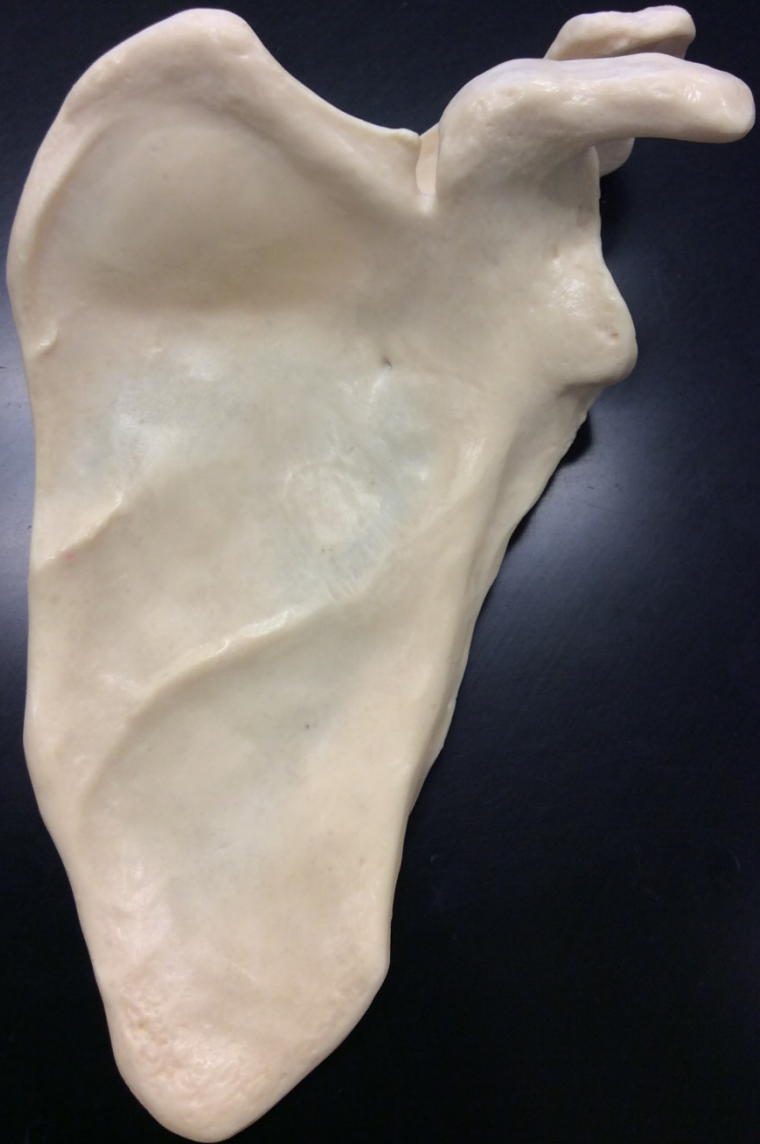


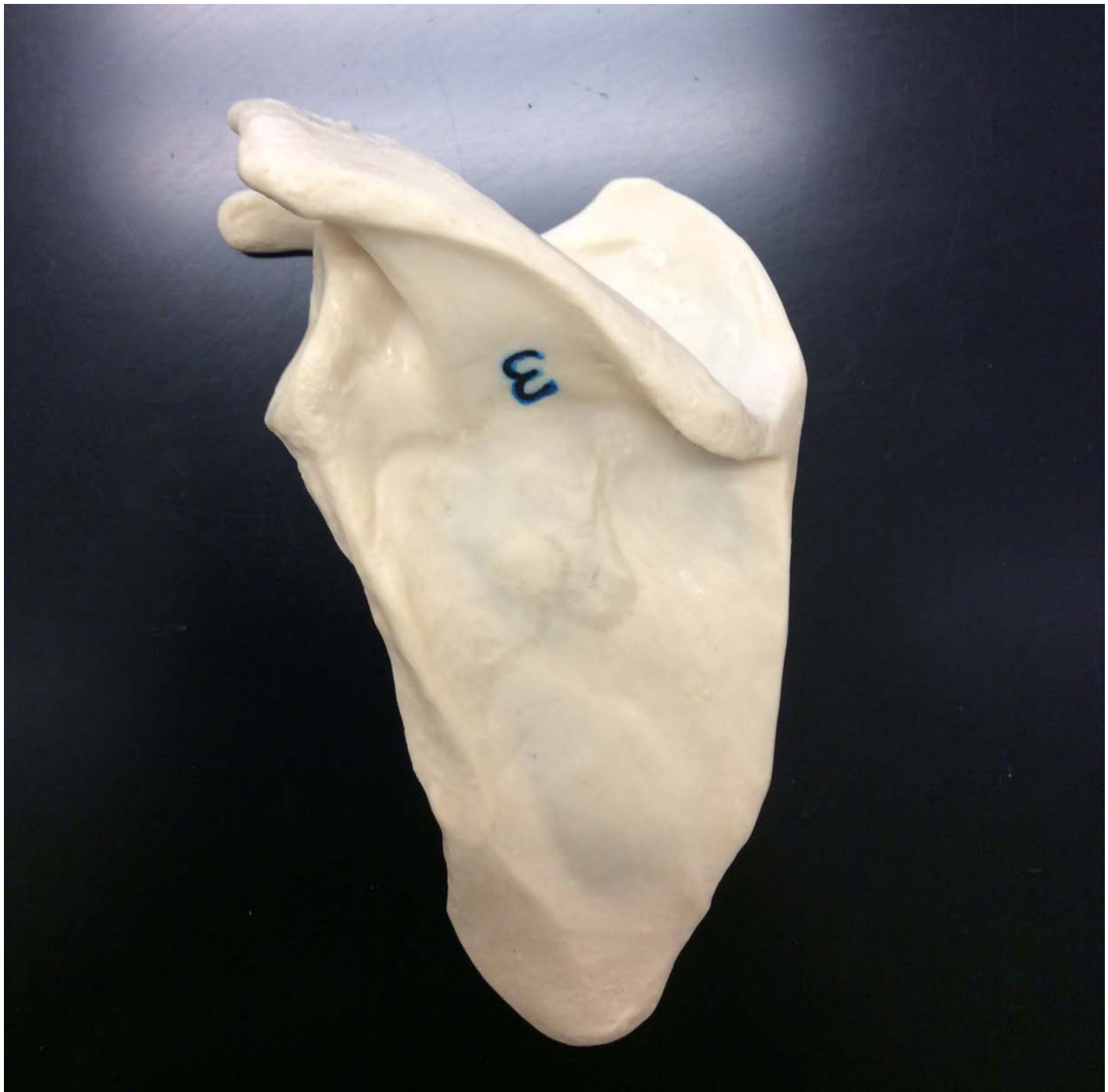








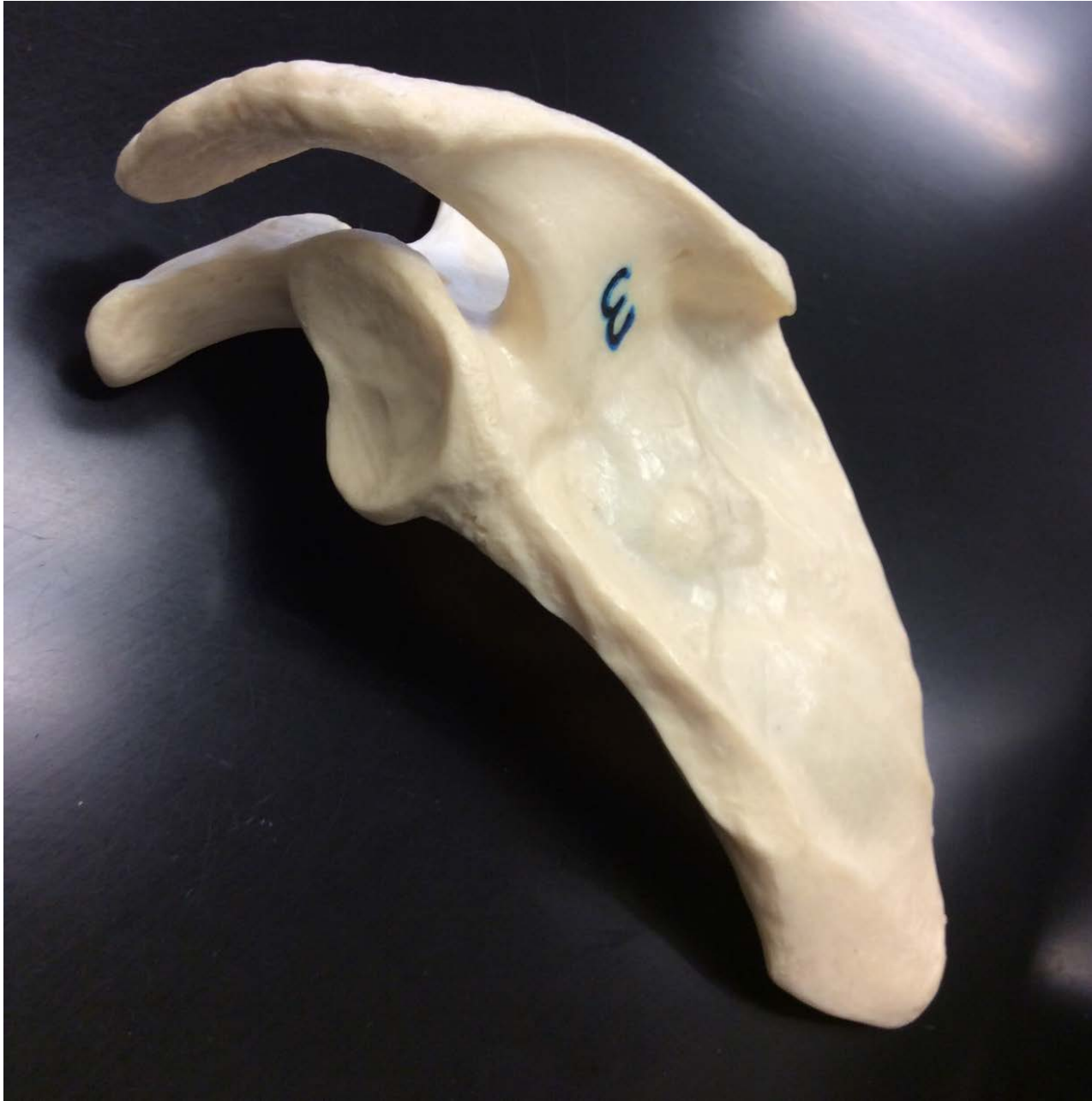






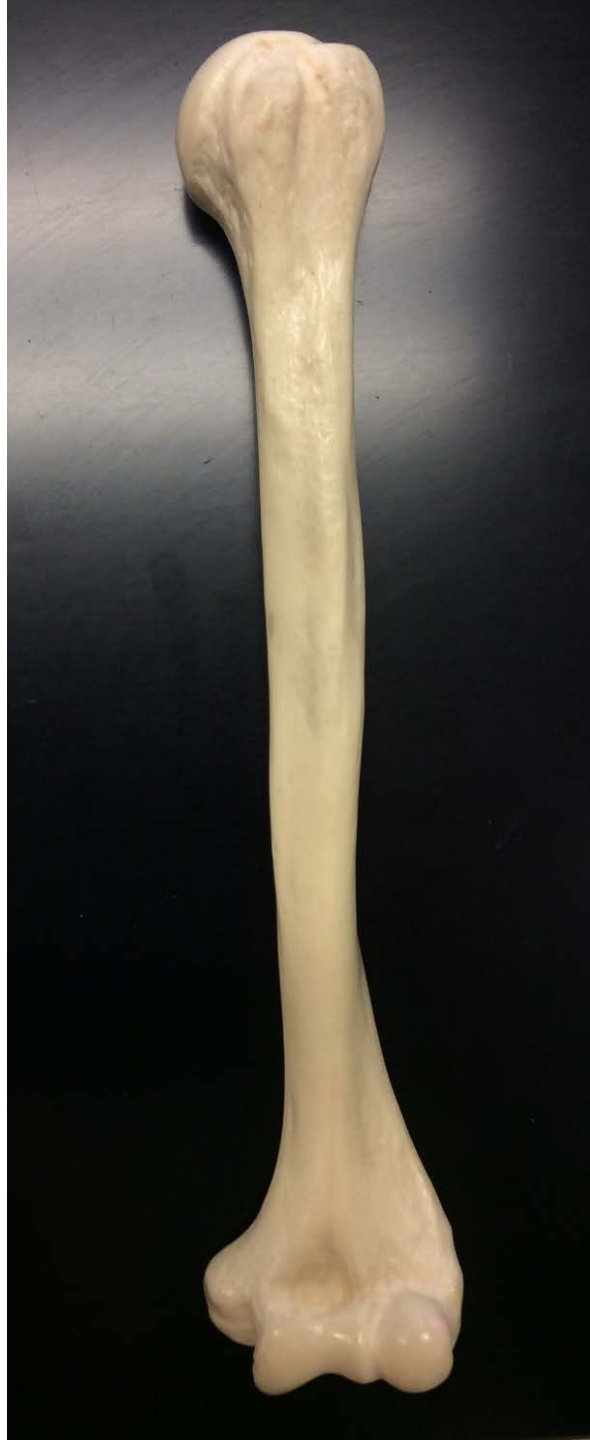


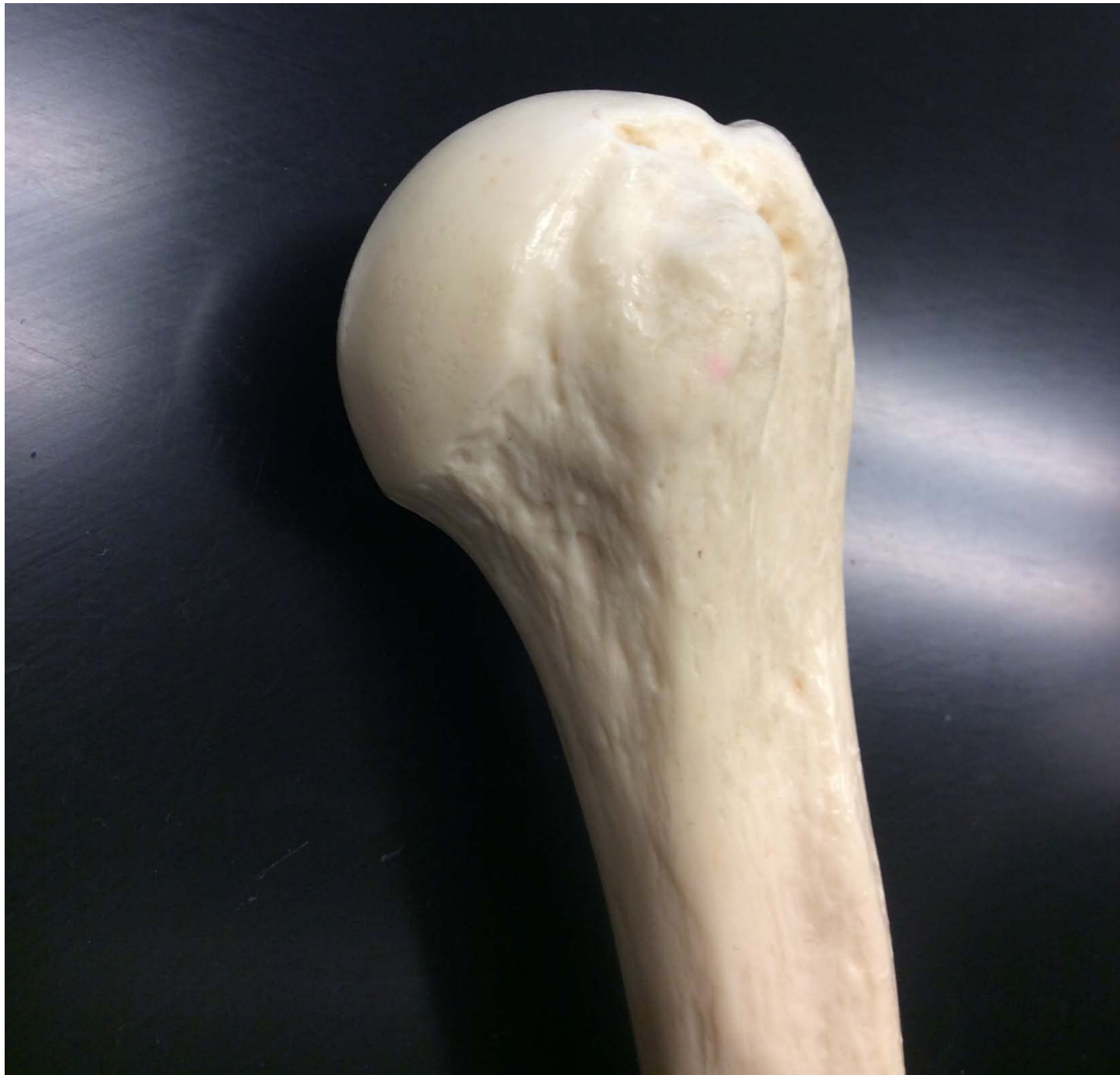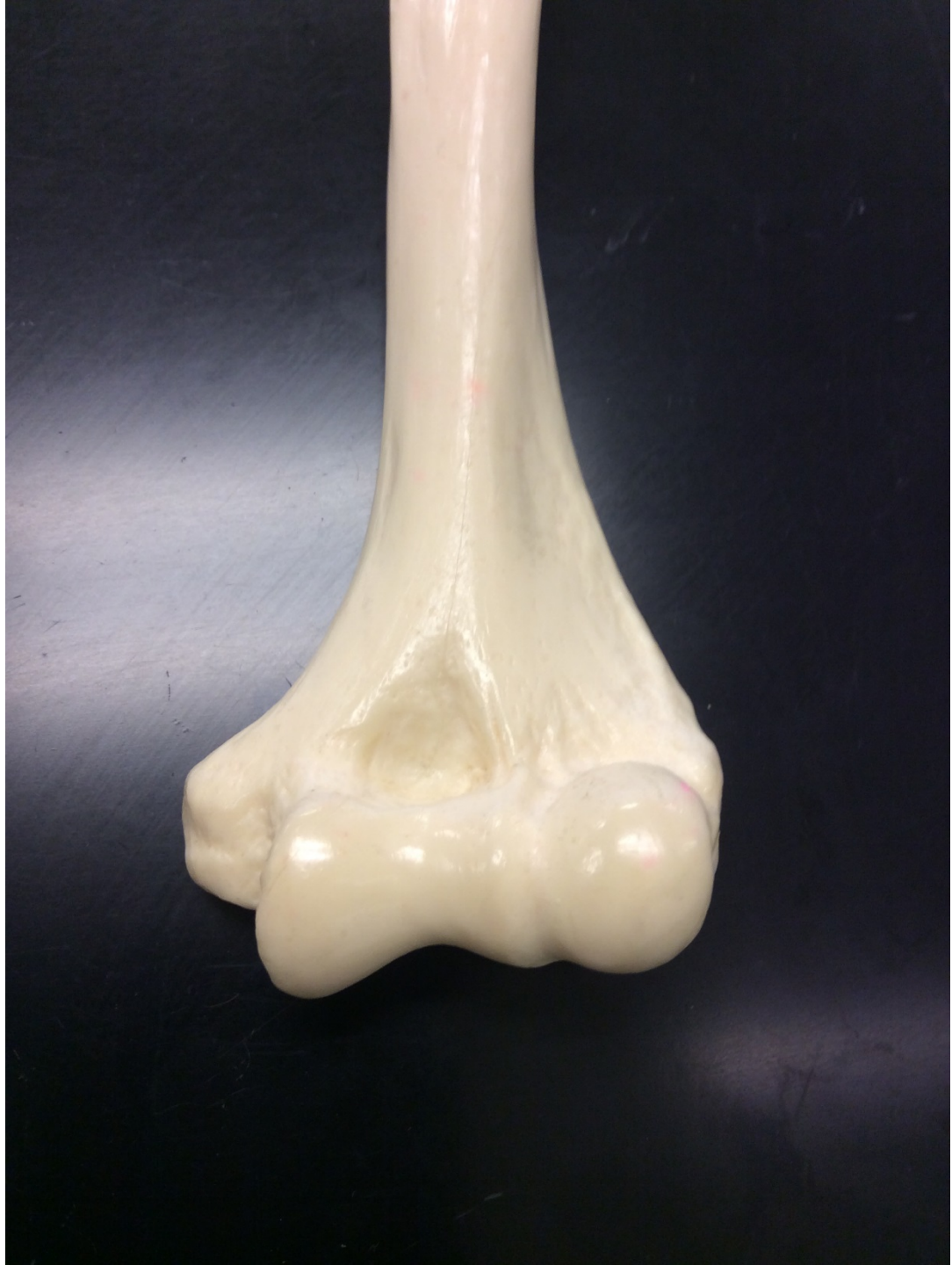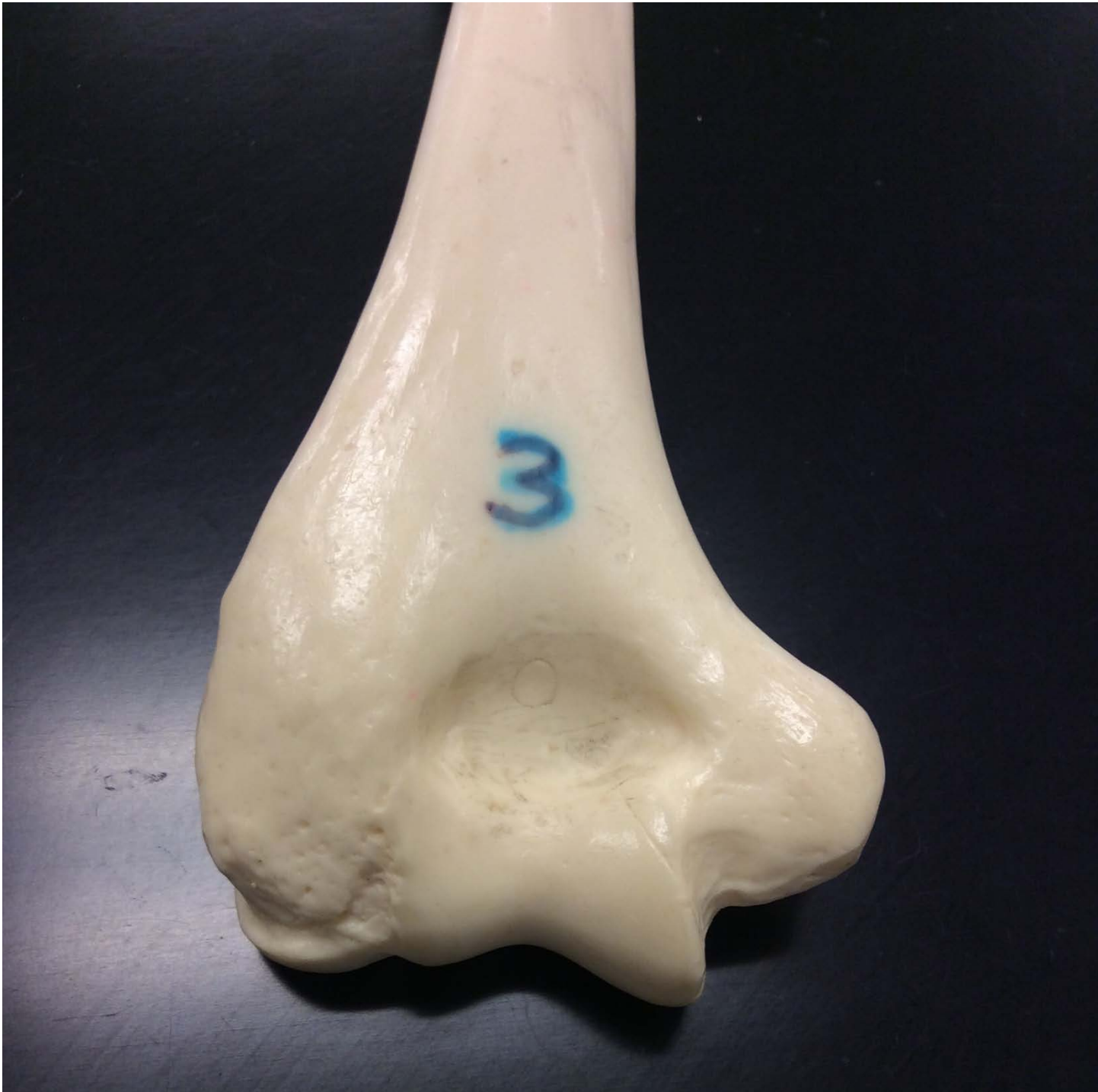
Upper Extremity (Limb)



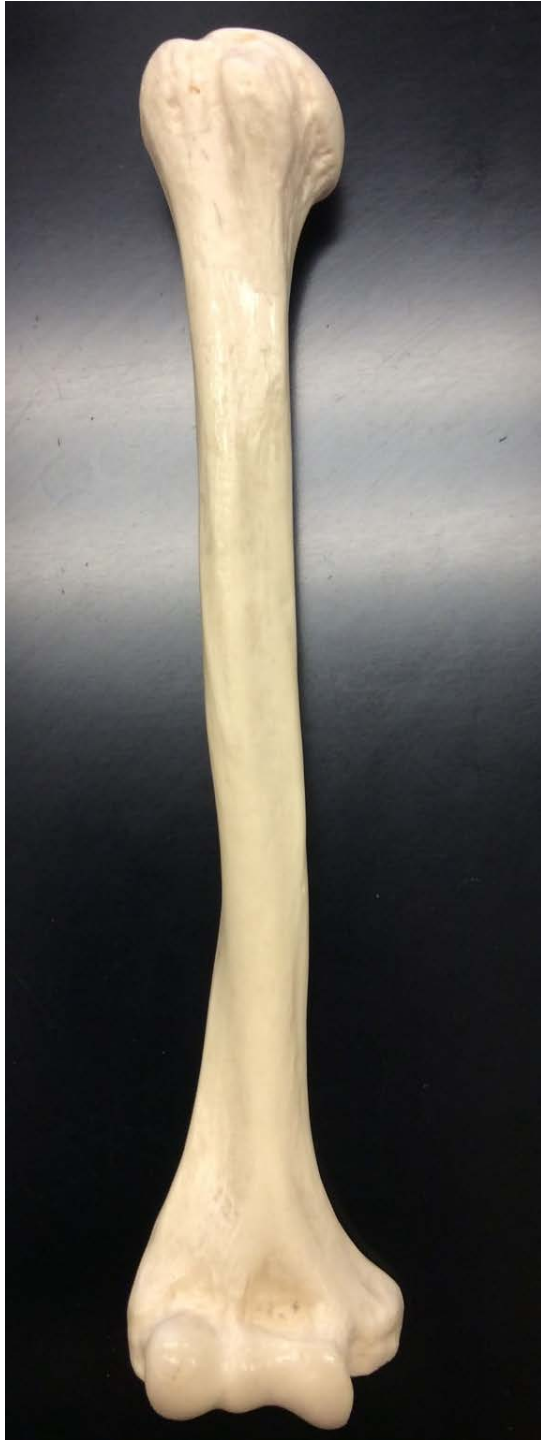


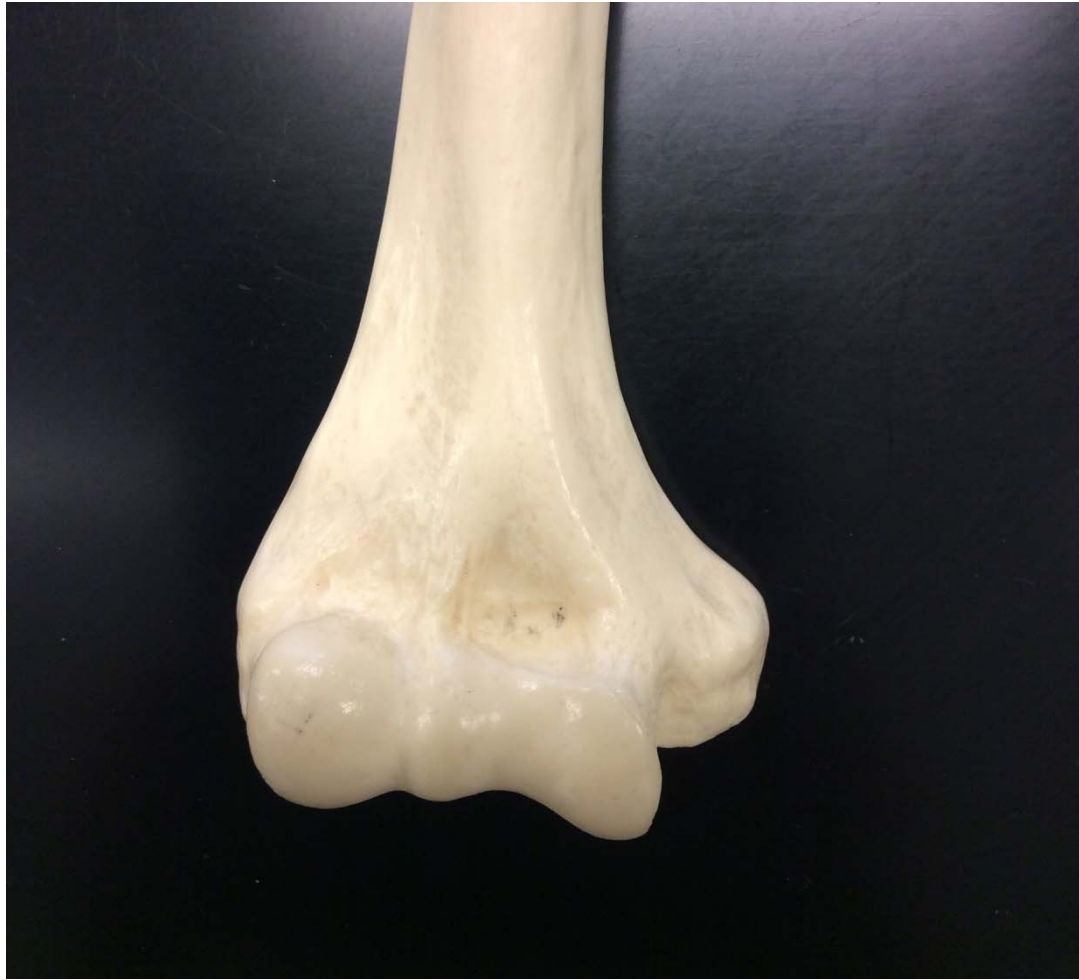


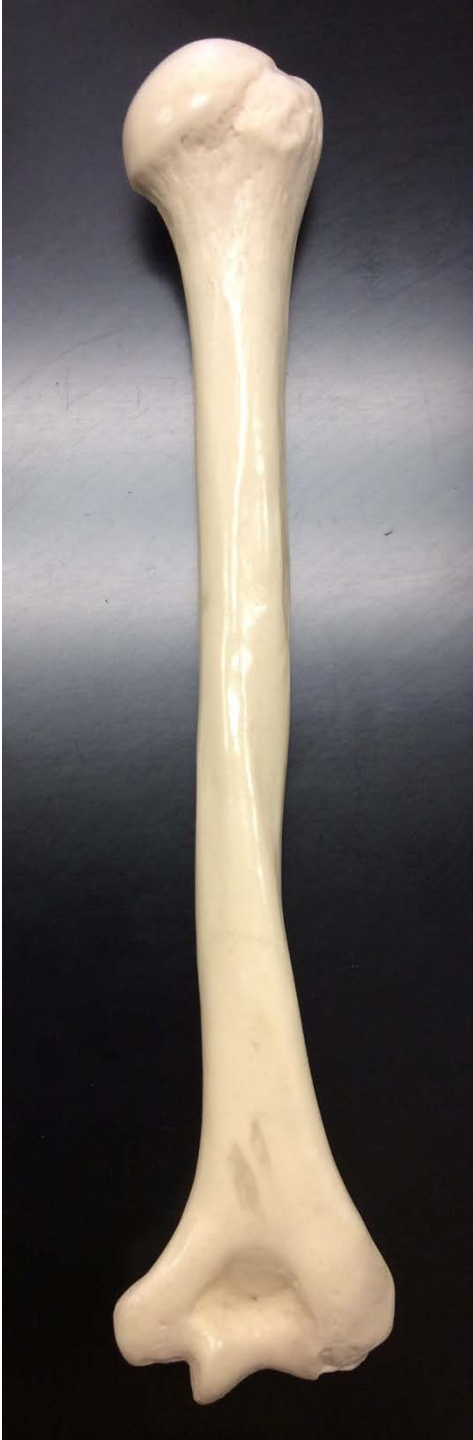

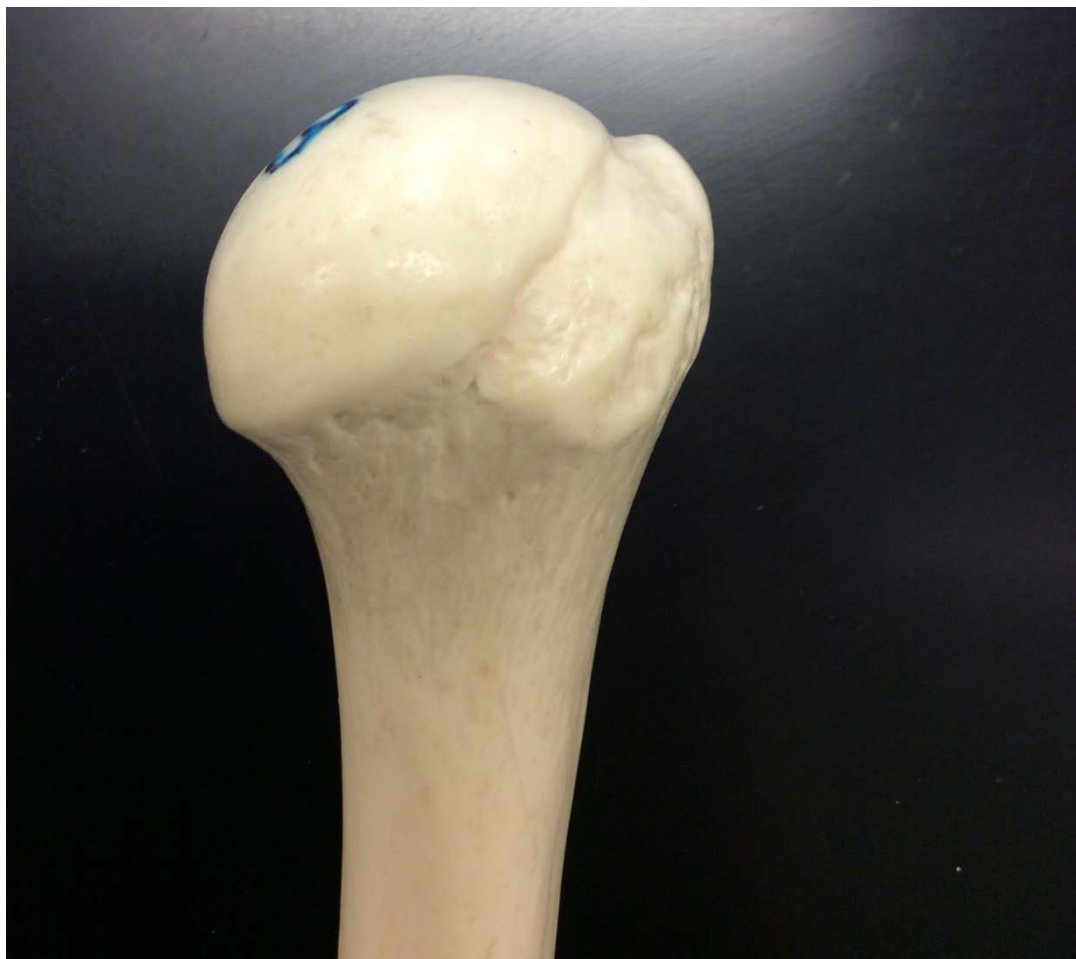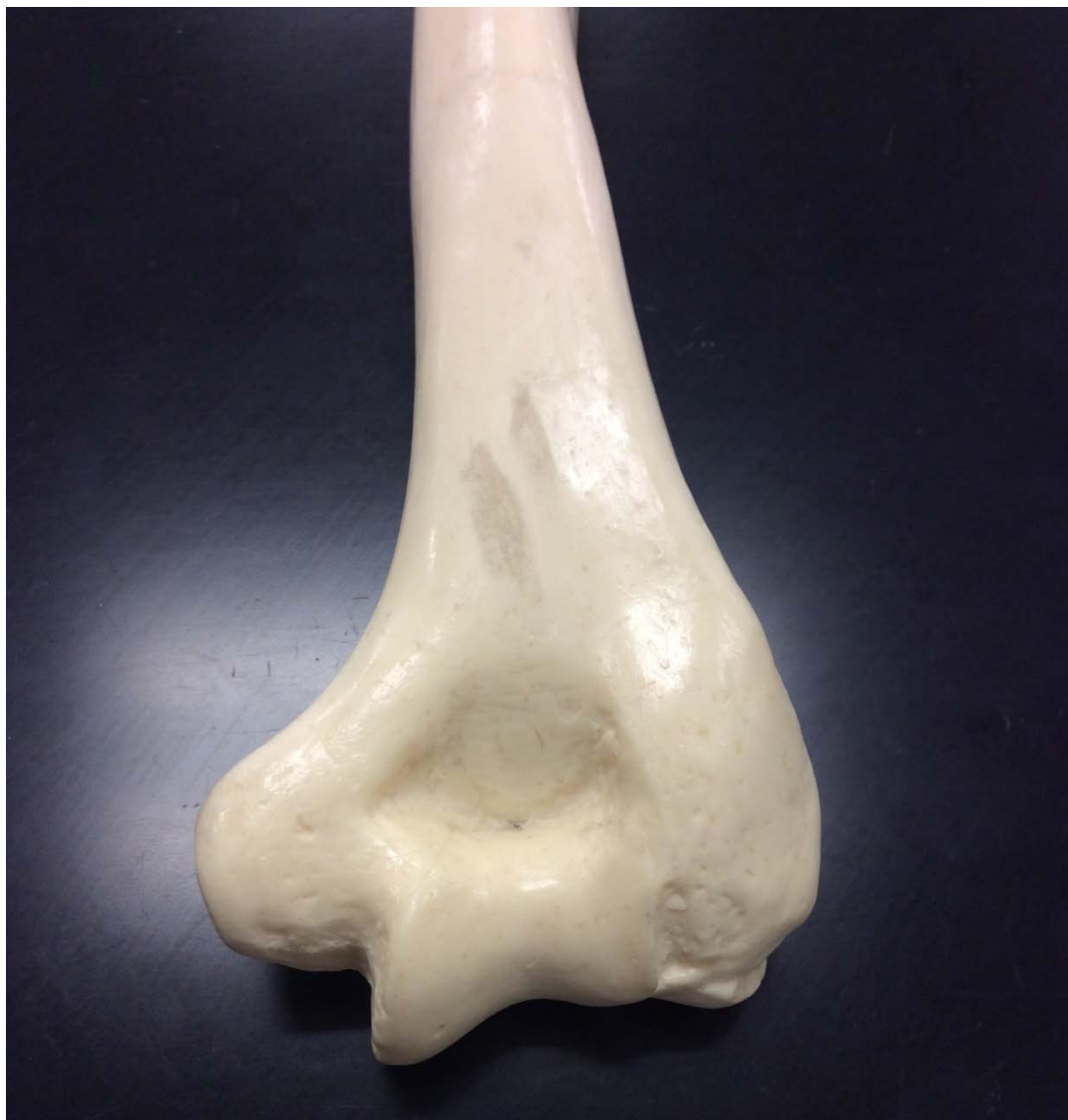










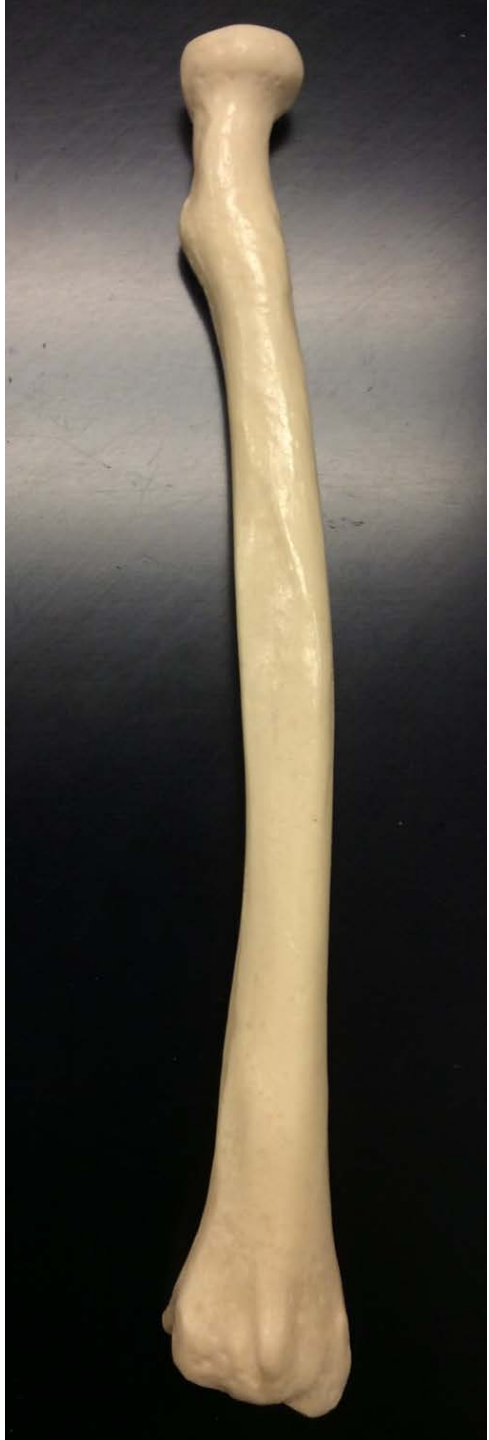


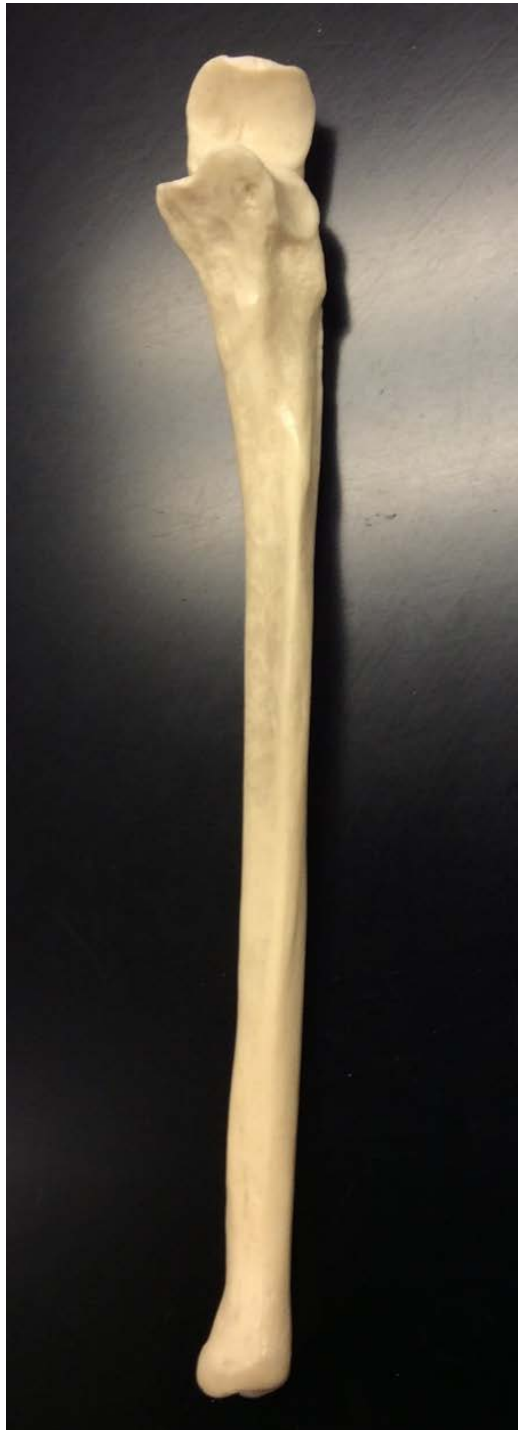






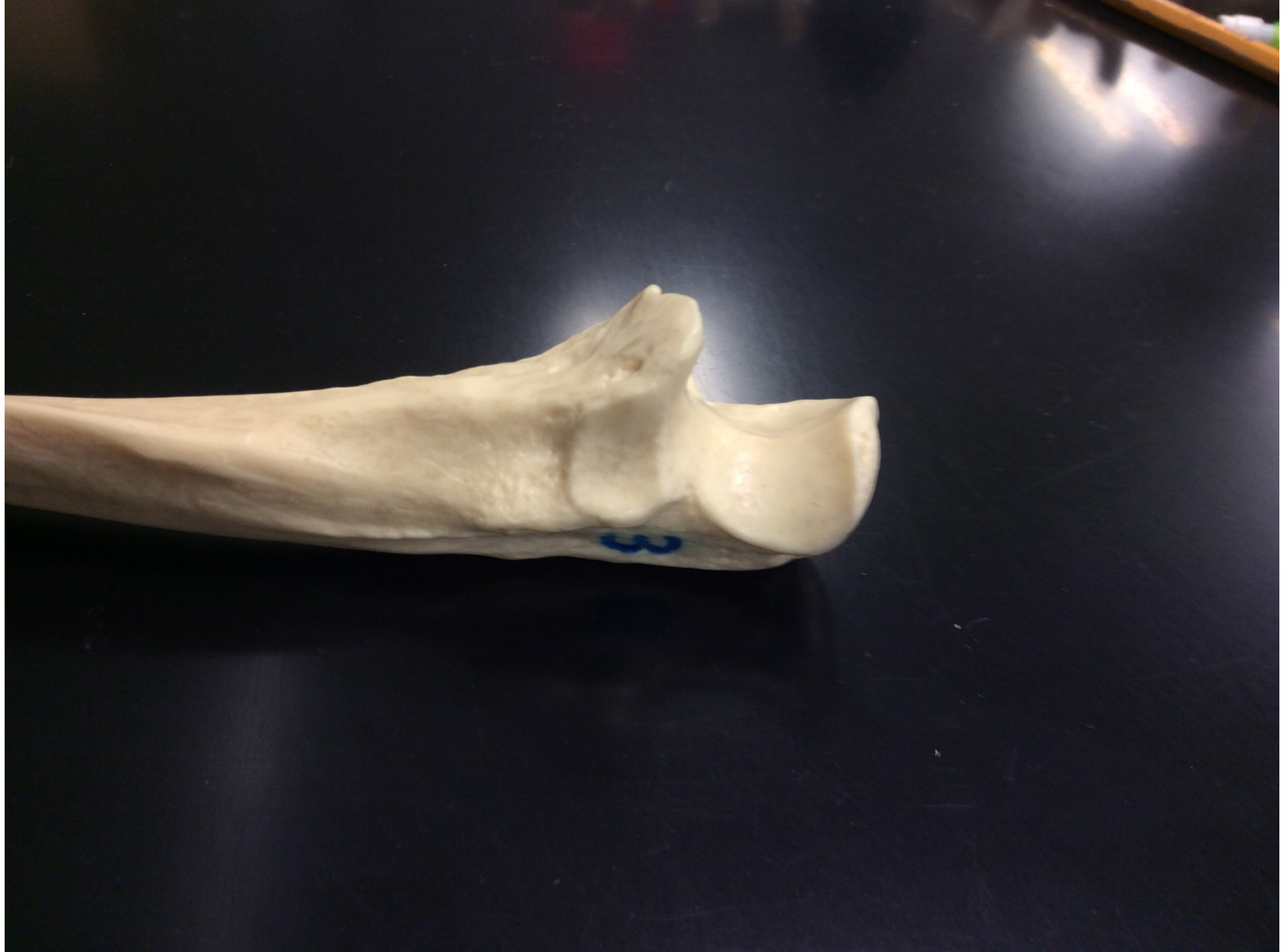














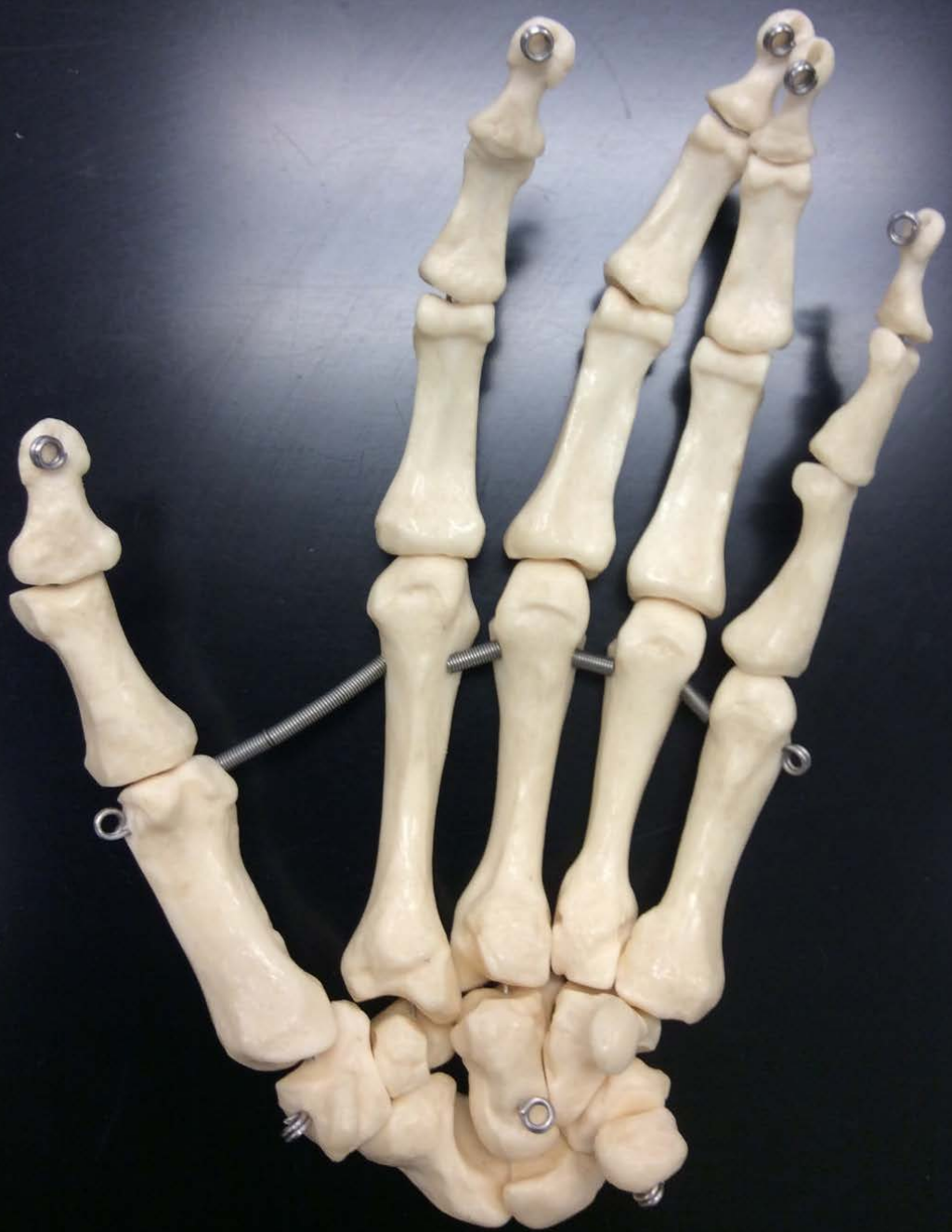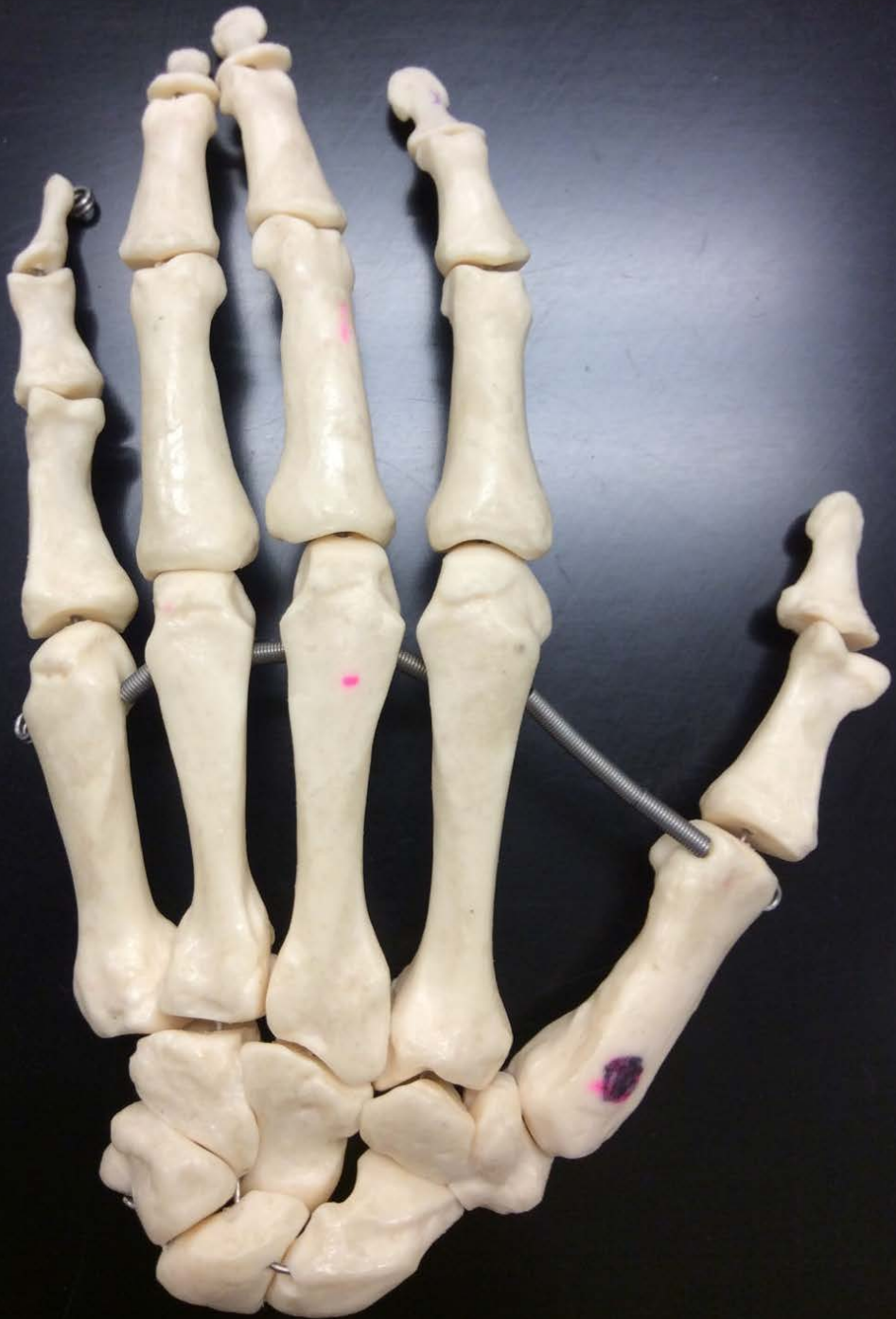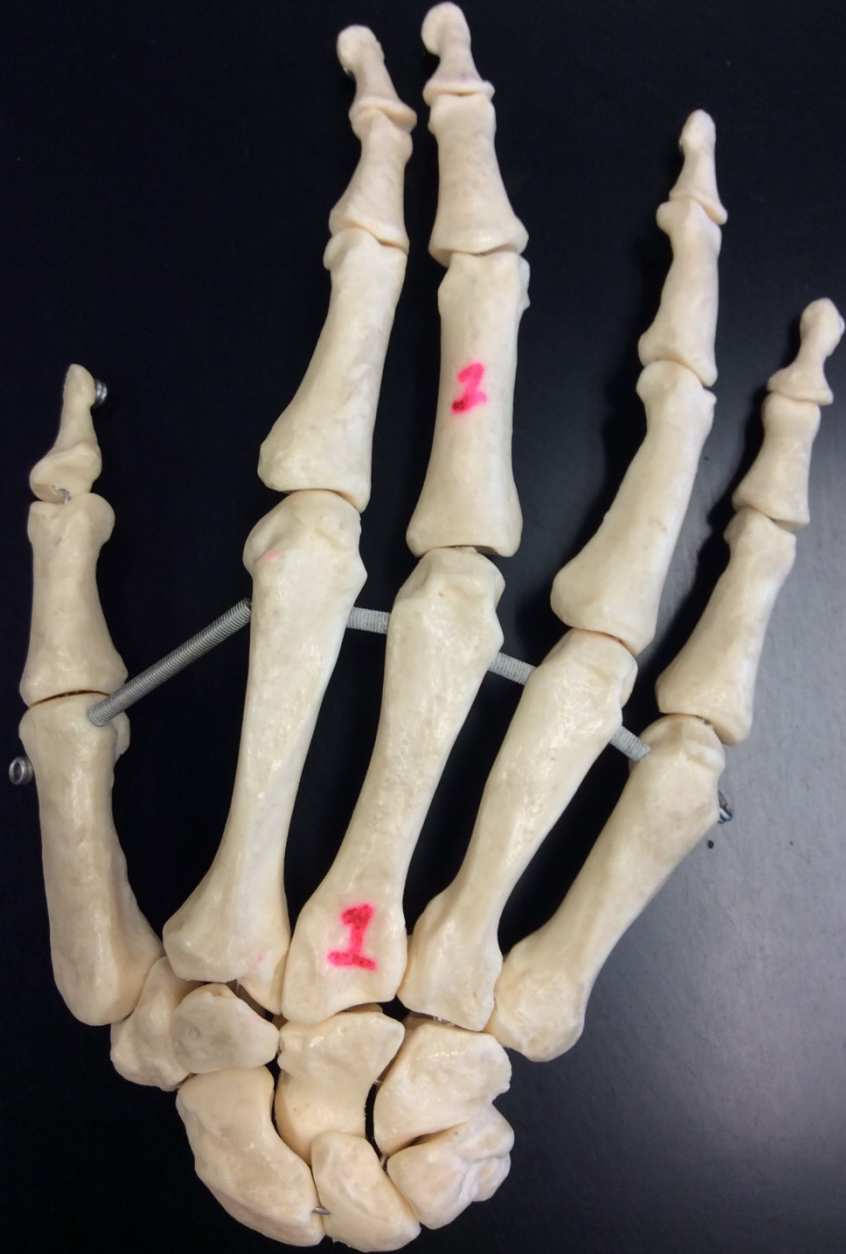








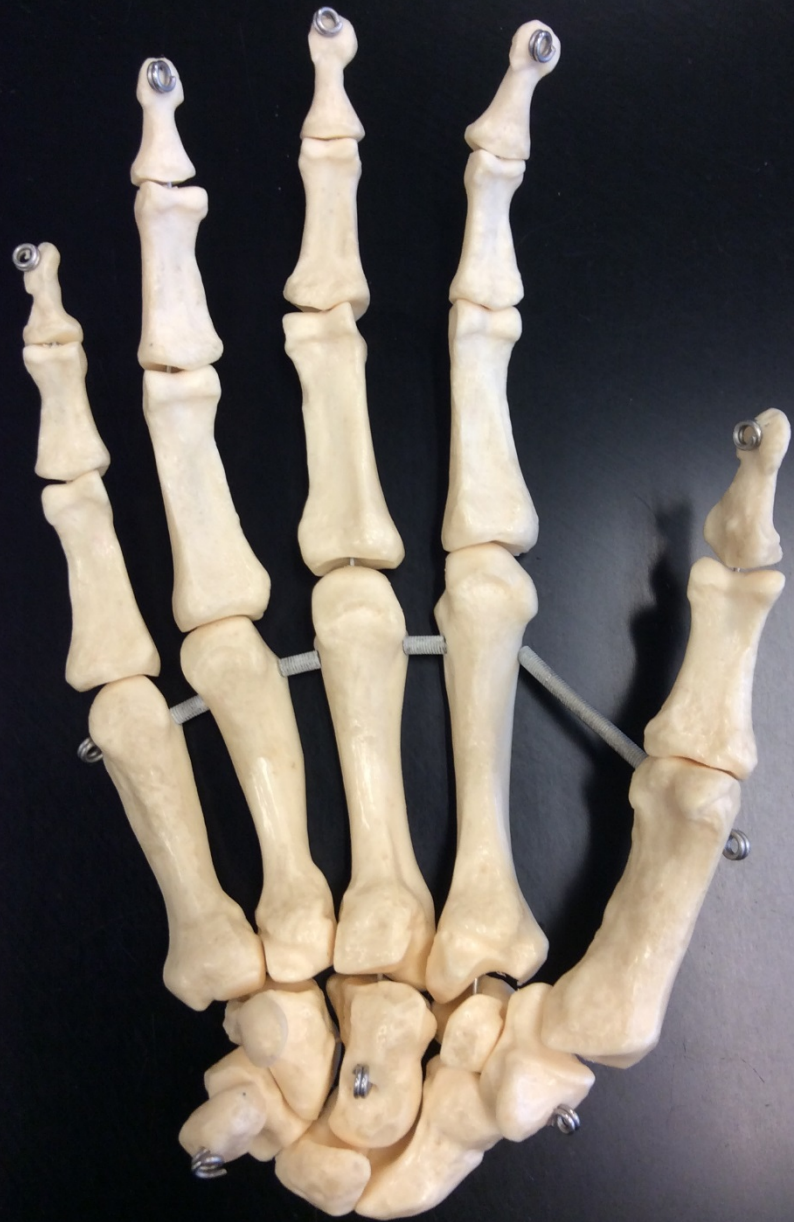





# Use the following pictures to help you identify terms from the lab term handout.

Another good resource is the Visible Body app: <http://skeleton.visiblebody.com>

Don't forget that to use the link to download to a personal device, the device must first be connected to the MCPA Wi-Fi at the Rockville campus.

Figure 7.31 Pelvis.

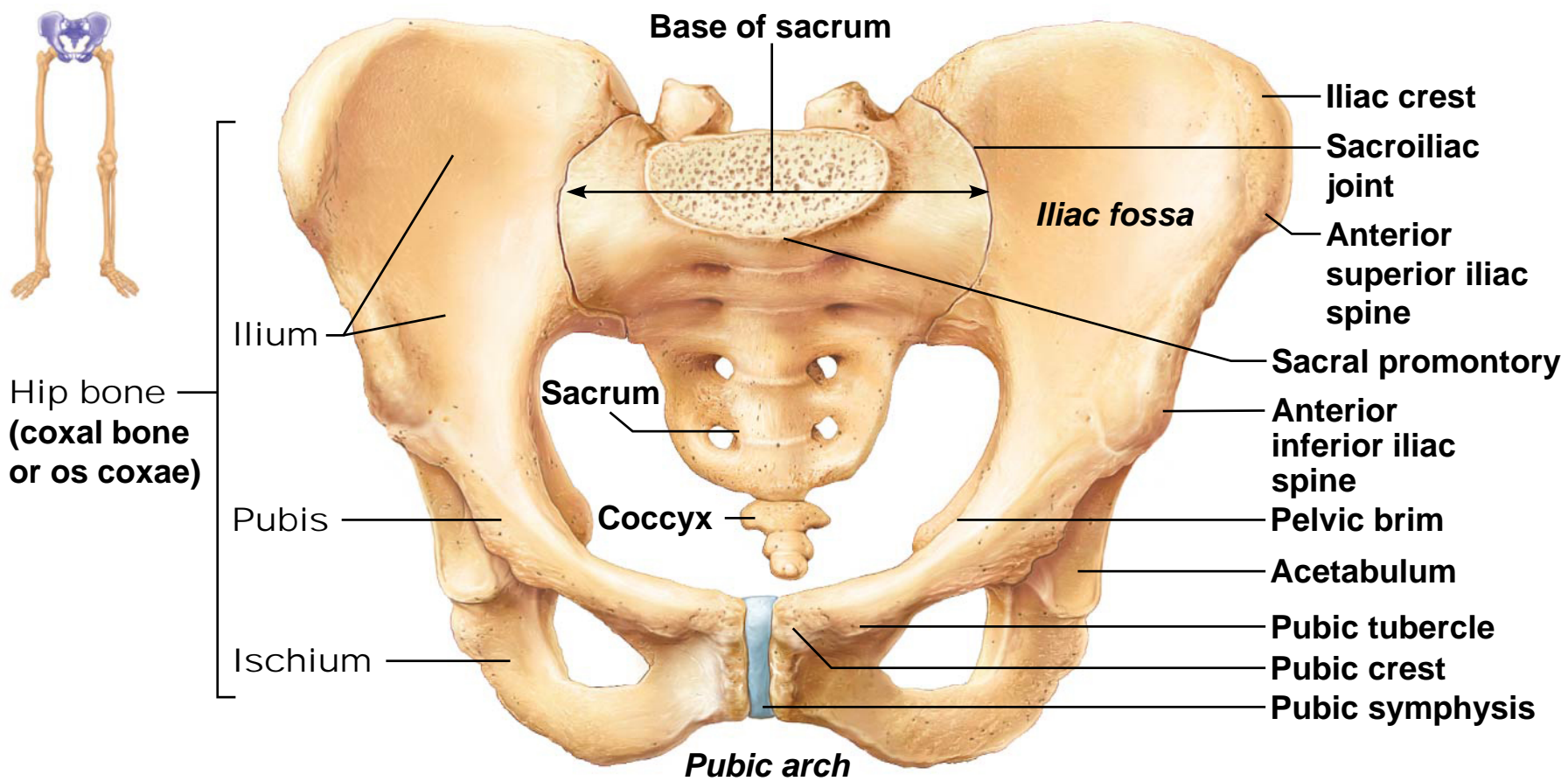
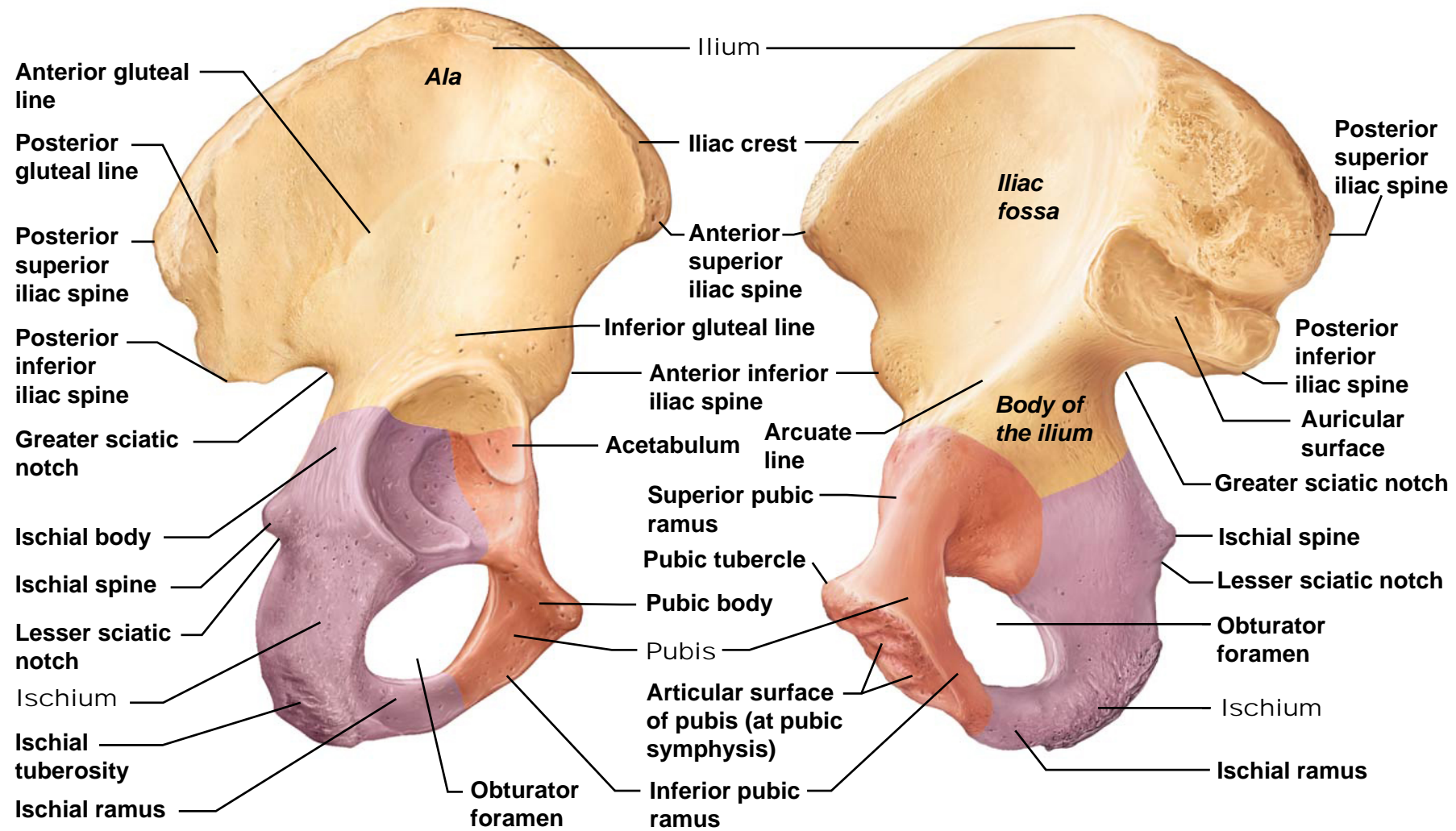


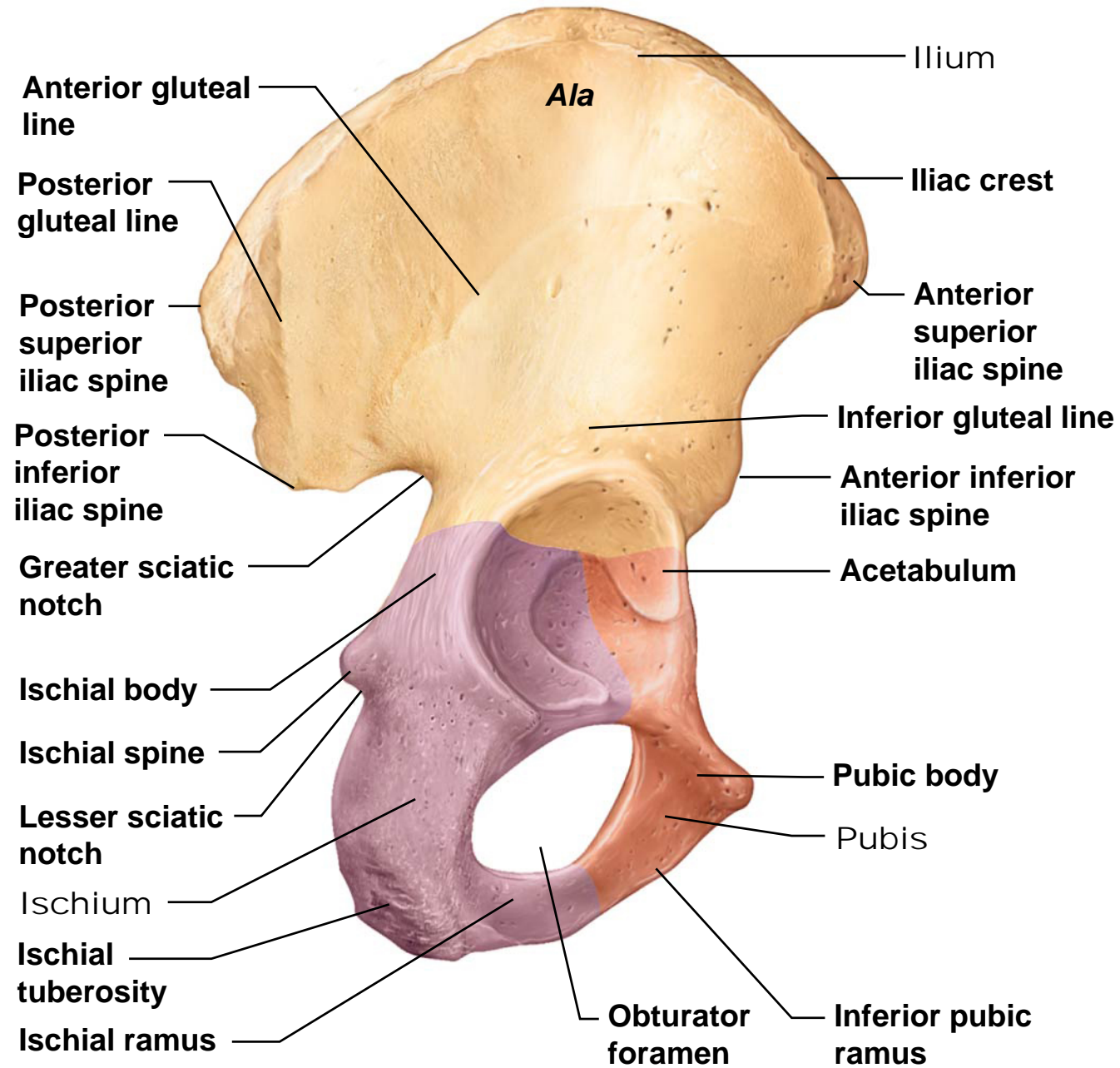
Figure 7.32 The hip (coxal) bones.



(a) Lateral view, right hip bone

(b) Medial view, right hip bone

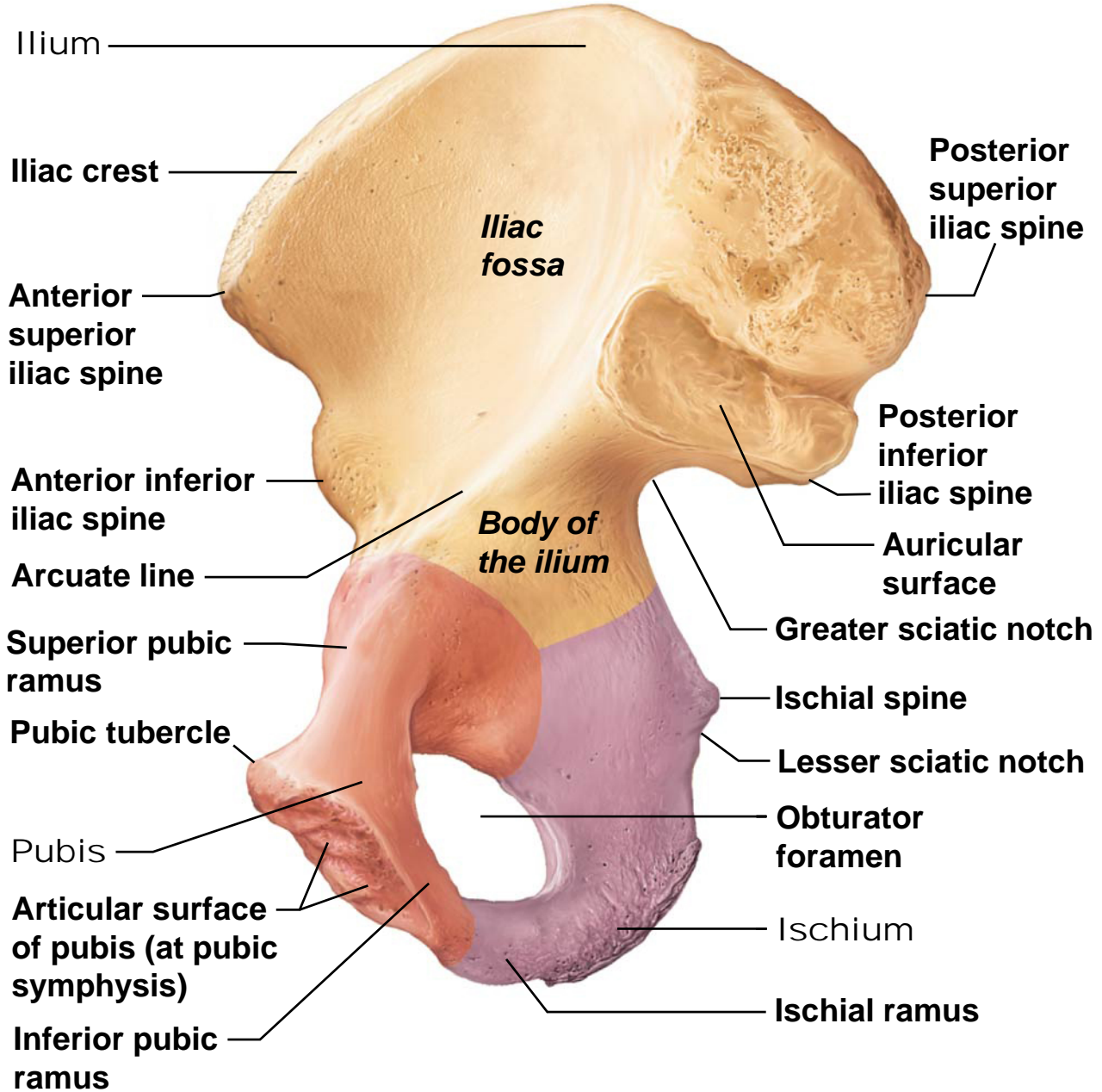
Figure 7.32a The hip (coxal) bones.



(a) Lateral view, right hip bone



Figure 7.32b The hip (coxal) bones.



**(b)** Medial view, right hip bone

Table 7.4-1 Comparison of the Male and Female Pelves

Table 7.4 Comparison of the Male and Female Pelves		
CHARACTERISTIC	FEMALE	MALE
General structure and functional modifications	Tilted forward; adapted for childbearing; true pelvis defines the birth canal; cavity of the true pelvis is broad, shallow, and has a greater capacity	Tilted less far forward; adapted for support of a male's heavier build and stronger muscles; cavity of the true pelvis is narrow and deep
Bone thickness	Less; bones lighter, thinner, and smoother	Greater; bones heavier and thicker, and markings are more prominent
Acetabula	Smaller; farther apart	Larger; closer
Pubic arch/subpubic angle	Broader (80° to 90°); more rounded	Angle is more acute (50° to 60°)
Anterior view		



Table 7.4 Comparison of the Male and Female Pelves ( <i>continued</i> )		
CHARACTERISTIC	FEMALE	MALE
Sacrum	Wider; shorter; sacral curvature is accentuated	Narrow; longer; sacral promontory more ventral
Coccyx	More movable; projects inferiorly	Less movable; projects anteriorly
Greater sciatic notch	Wide and shallow	Narrow and deep
Left lateral view		

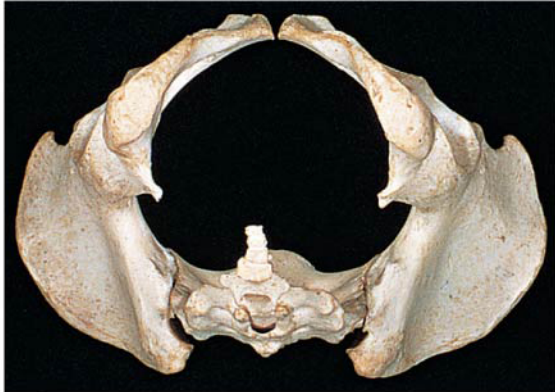

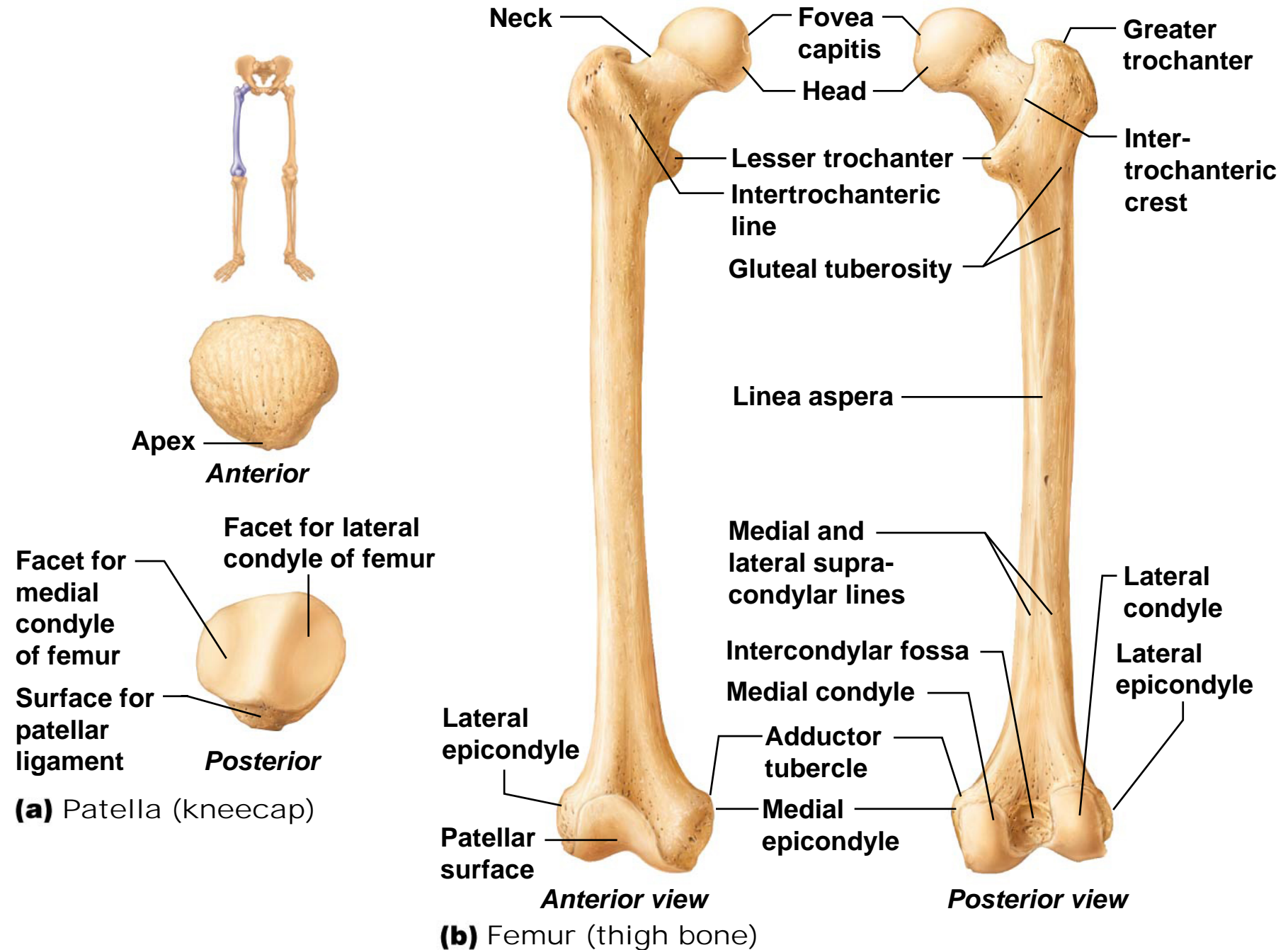
Table 7.4 Comparison of the Male and Female Pelves ( <i>continued</i> )		
CHARACTERISTIC	FEMALE	MALE
Pelvic inlet (brim)	Wider; oval from side to side	Narrow; basically heart shaped
Pelvic outlet	Wider; ischial tuberosities shorter, farther apart and everted	Narrower; ischial tuberosities longer, sharper, and point more medially
Posteroinferior view		

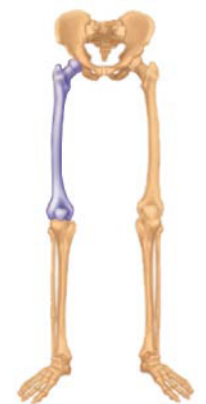Figure 7.33 Bones of the right knee and thigh.



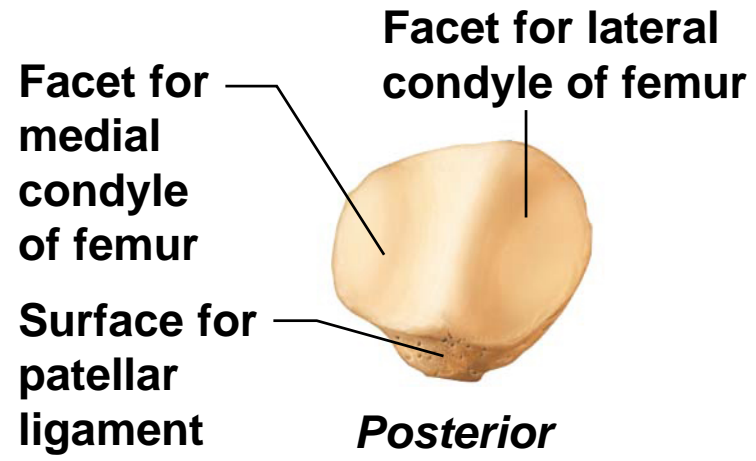
**(a)** Patella (kneecap)

**(b)** Femur (thigh bone)

Figure 7.33a Bones of the right knee and thigh.

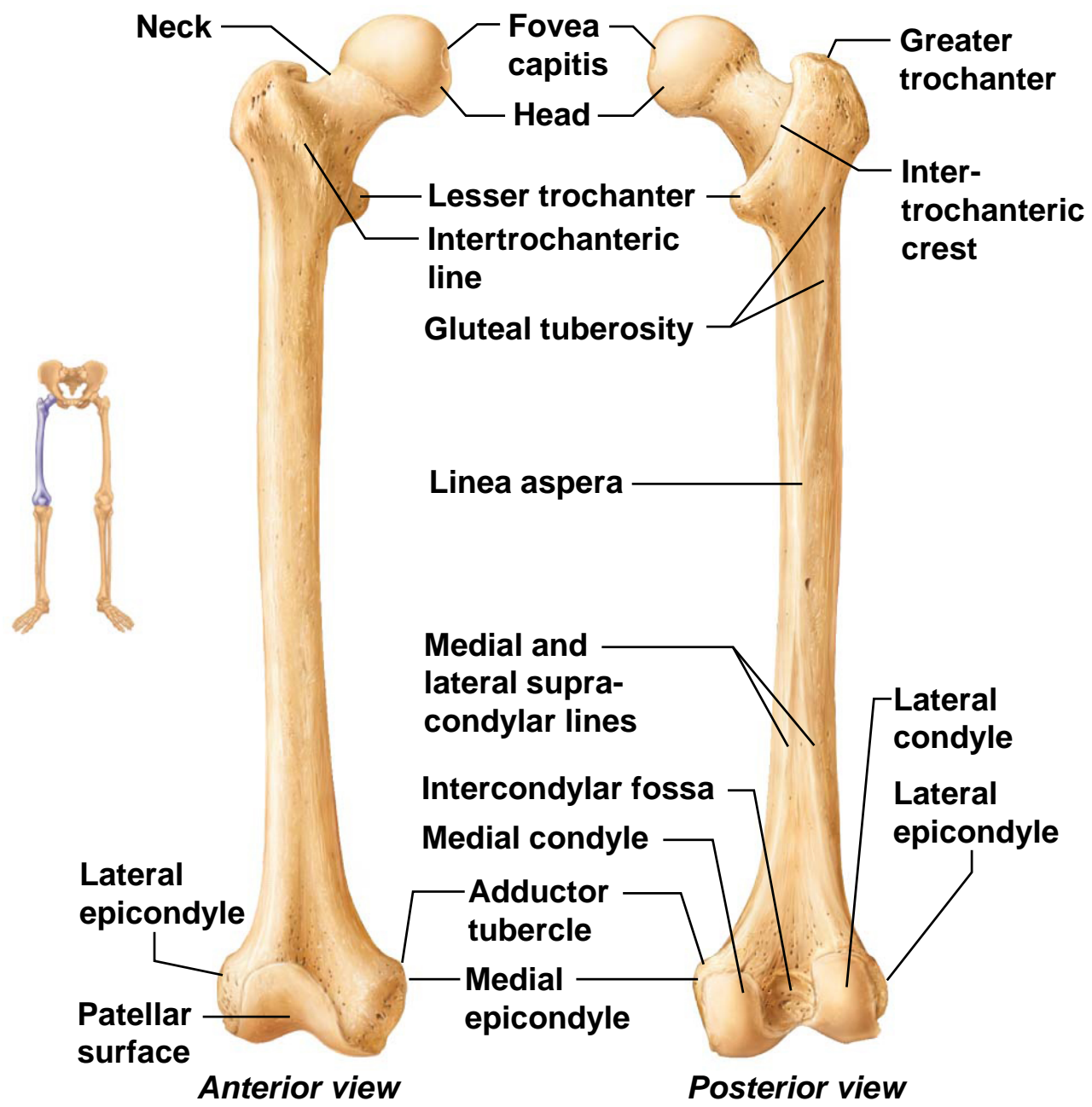


Apex —  
*Anterior*



**(a)** Patella (kneecap)

Figure 7.33b Bones of the right knee and thigh.



**(b)** Femur (thigh bone)

Table 7.5		Bones of the Appendicular Skeleton, Part 2: Pelvic Girdle and Lower Limb		
BODY REGION	BONES*	ILLUSTRATION	LOCATION	MARKINGS
<p><b>Pelvic girdle</b> (Figures 7.31, 7.32)</p>	<p><b>Coxal (2)</b> (hip)</p>		<p>Each hip (coxal) bone is formed by the fusion of an ilium, ischium, and pubis; the hip bones articulate anteriorly at the pubic symphysis and form sacroiliac joints with the sacrum posteriorly; girdle consisting of both hip bones and the sacrum is basinlike</p>	<p>Iliac crest; anterior and posterior iliac spines; auricular surface; greater and lesser sciatic notches; obturator foramen; ischial tuberosity and spine; acetabulum; pubic arch; pubic crest; pubic tubercle</p>
<p><b>Lower limb</b> Thigh (Figure 7.33)</p>	<p><b>Femur (2)</b></p>		<p>Femur is the sole bone of thigh; between hip joint and knee; largest bone of the body</p>	<p>Head; greater and lesser trochanters; neck; lateral and medial condyles and epicondyles; gluteal tuberosity; linea aspera</p>
<p>Kneecap (Figure 7.33)</p>	<p><b>Patella (2)</b></p>		<p>Patella is a sesamoid bone formed within the tendon of the quadriceps (anterior thigh) muscles</p>	

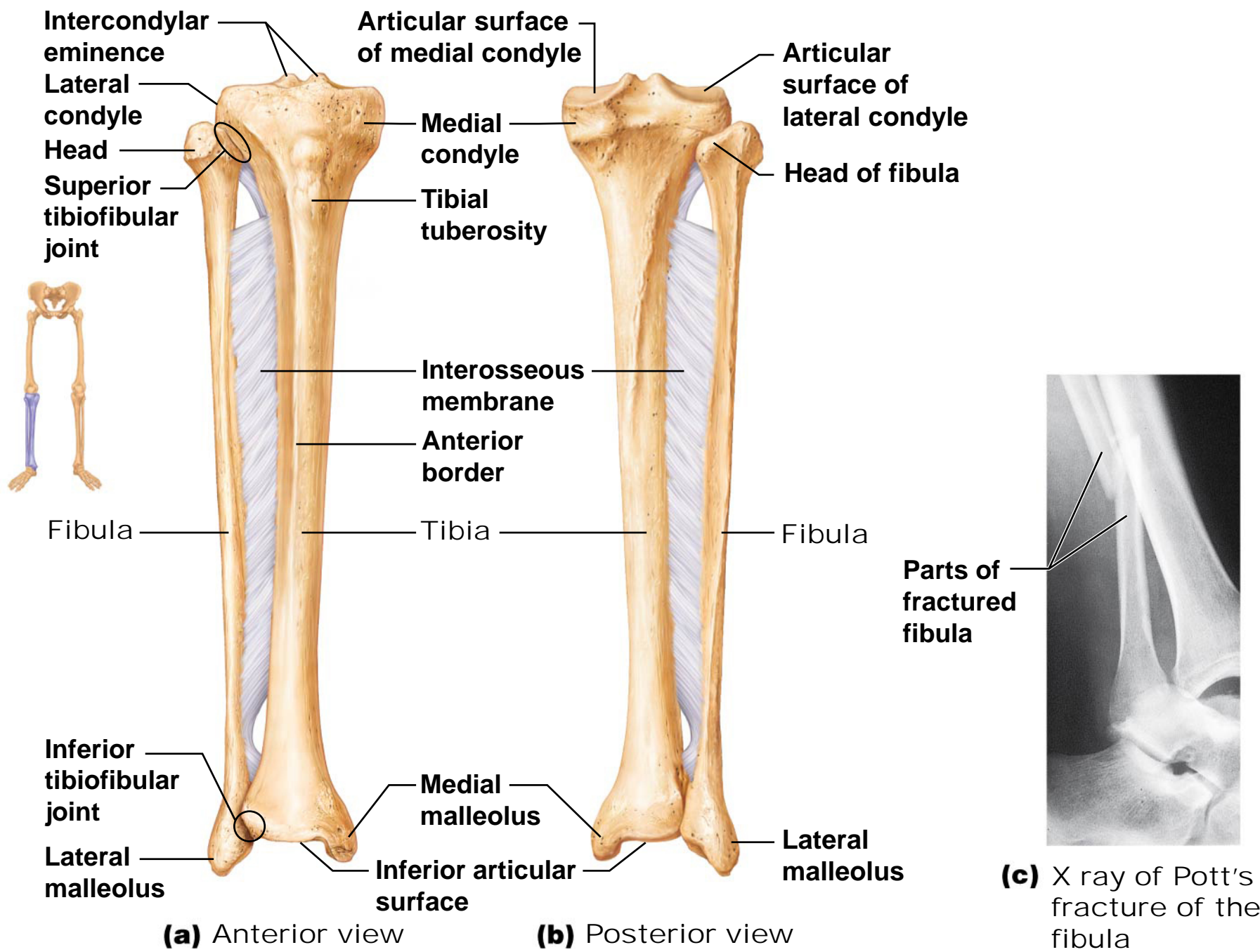
\* The number in parentheses ( ) following the bone name denotes the total number of such bones in the body.

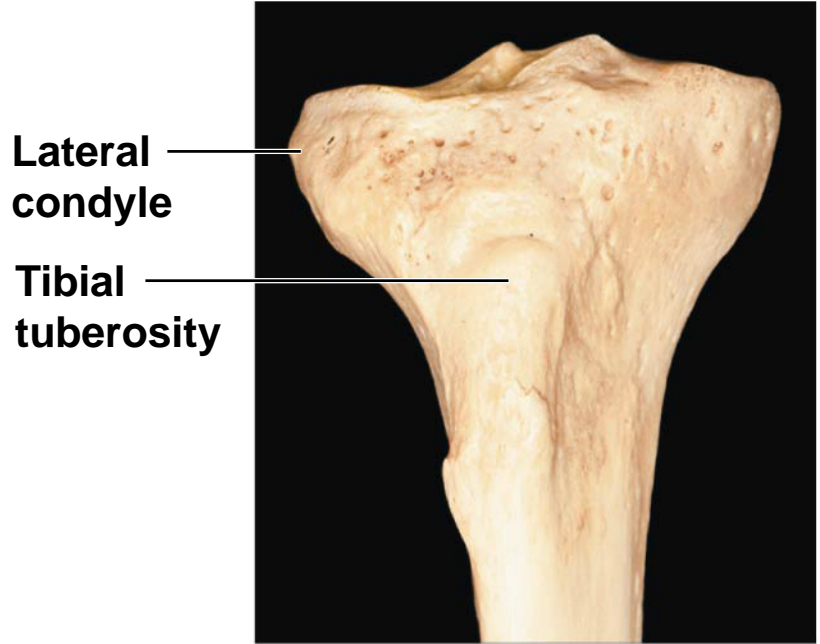


Table 7.5 Bones of the Appendicular Skeleton, Part 2: Pelvic Girdle and Lower Limb (continued)					
BODY REGION	BONES*	ILLUSTRATION	LOCATION	MARKINGS	
Leg (Figure 7.34)	<b>Tibia</b> (2)		Tibia is the larger and more medial bone of leg; between knee and foot	Medial and lateral condyles; tibial tuberosity; anterior border; medial malleolus	
	<b>Fibula</b> (2)		Fibula is the lateral bone of leg; sticklike	Head; lateral malleolus	
Foot (Figure 7.35)	<b>7 Tarsals</b> (14) talus calcaneus navicular cuboid lateral cuneiform intermediate cuneiform medial cuneiform		Tarsals are seven bones forming the proximal part of the foot; the talus articulates with the leg bones at the ankle joint; the calcaneus, the largest tarsal, forms the heel		
	<b>5 Metatarsals</b> (10)		Metatarsals are five bones numbered I–V		
	<b>14 Phalanges</b> (28) distal middle proximal	Phalanges form the toes; three in digits II–V, two in digit I (the great toe)			

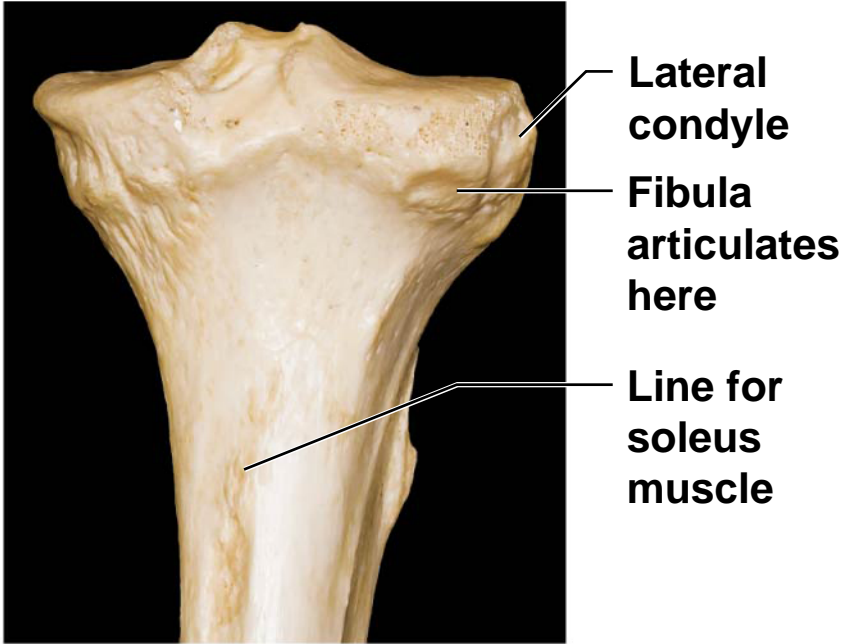
\* The number in parentheses ( ) following the bone name denotes the total number of such bones in the body.

Figure 7.34 The tibia and fibula of the right leg.



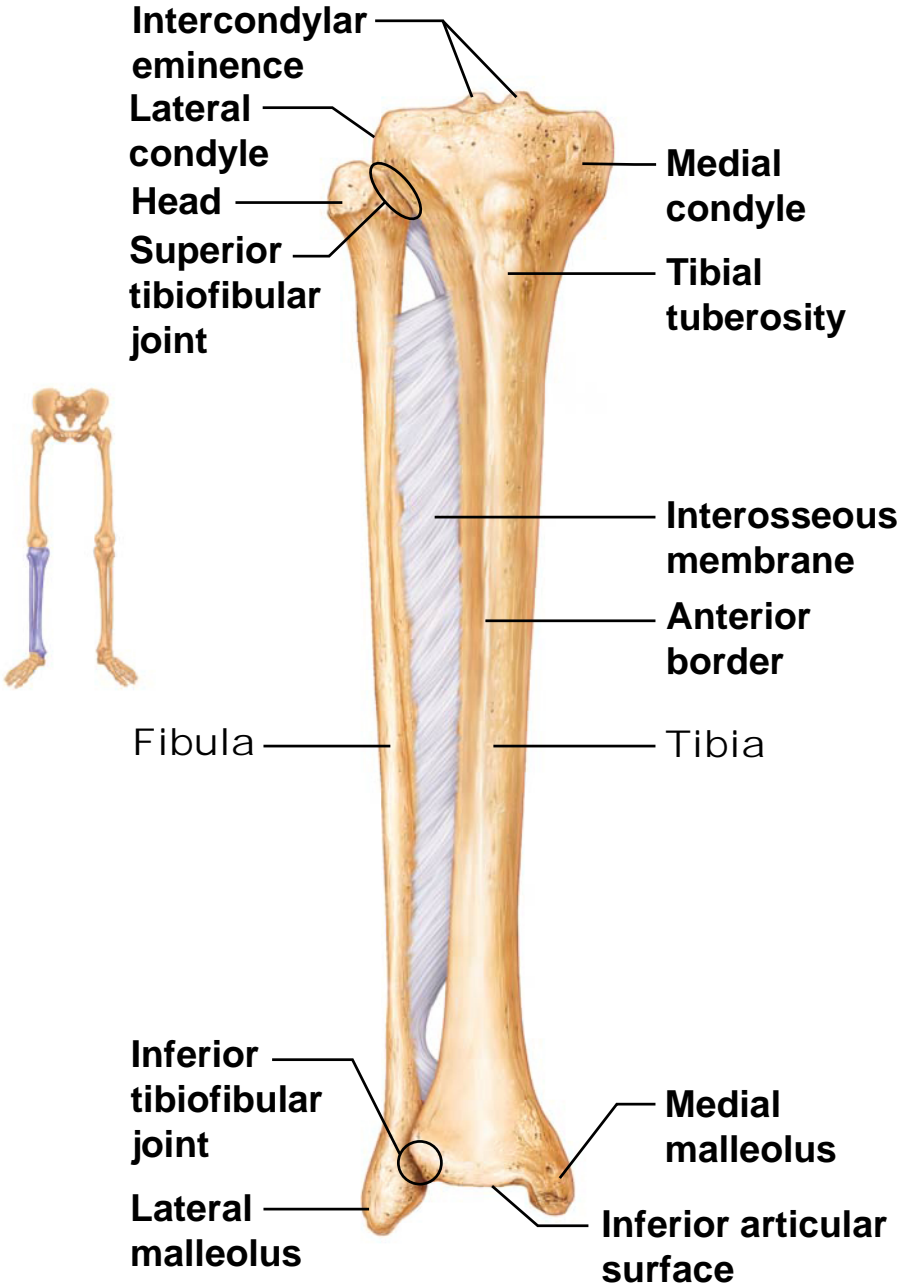


**(d)** Anterior view, proximal tibia



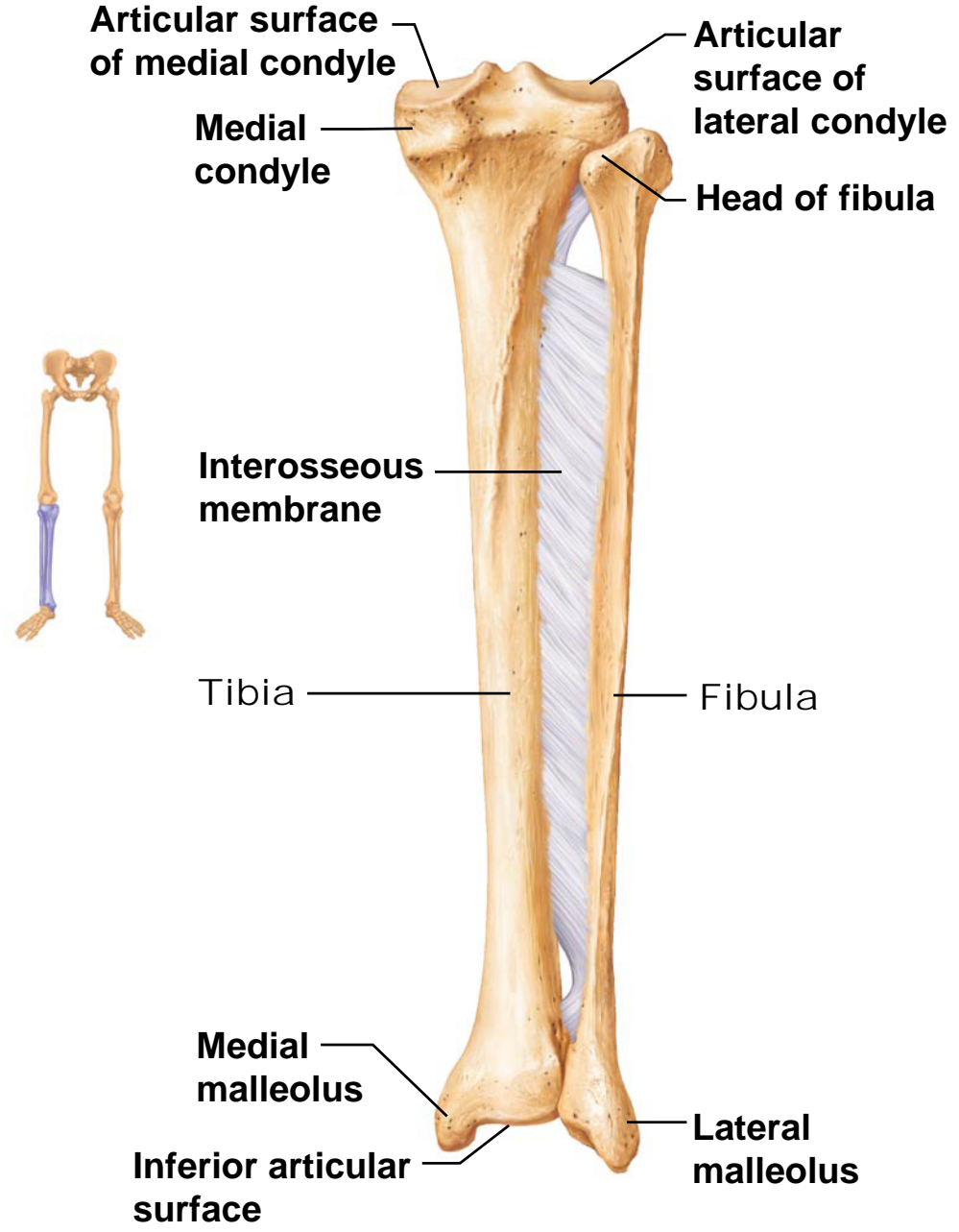
**(e)** Posterior view, proximal tibia

Figure 7.34a The tibia and fibula of the right leg.

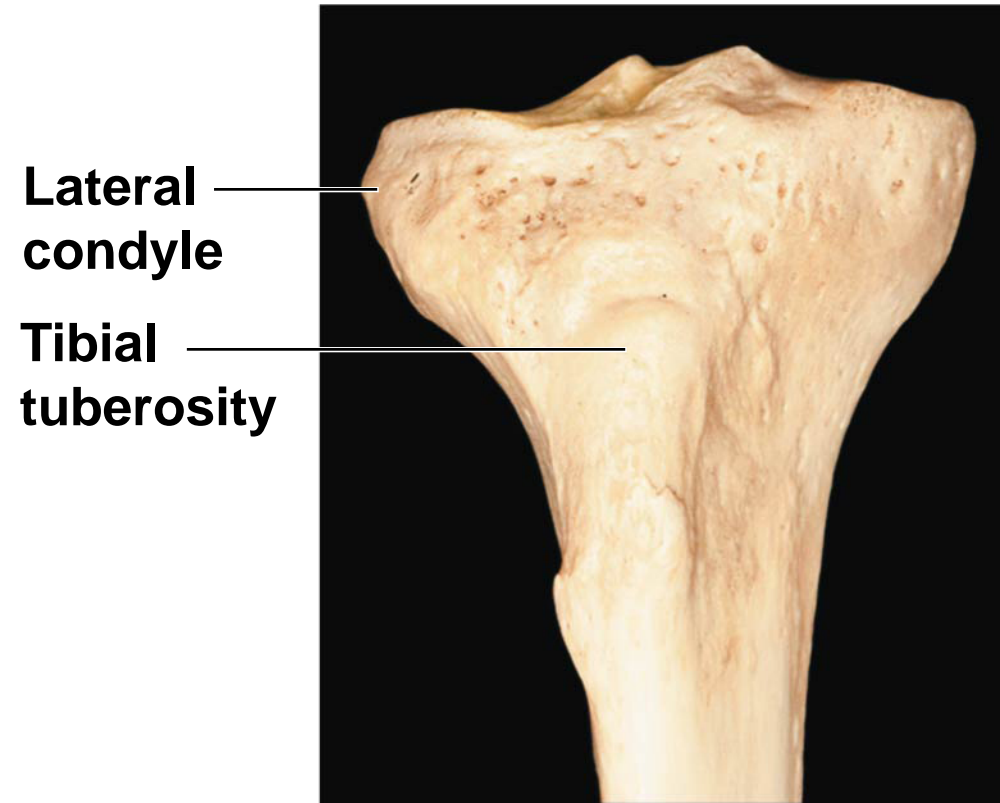


**(a)** Anterior view

Figure 7.34b The tibia and fibula of the right leg.

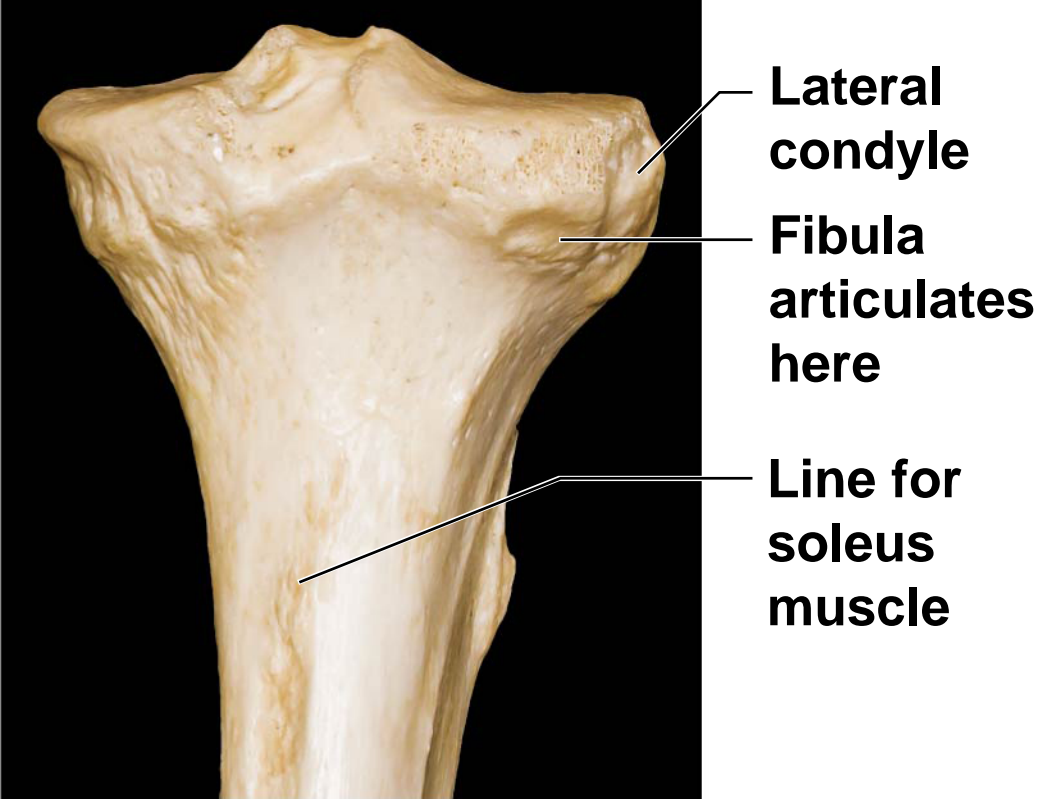


**(b)** Posterior view



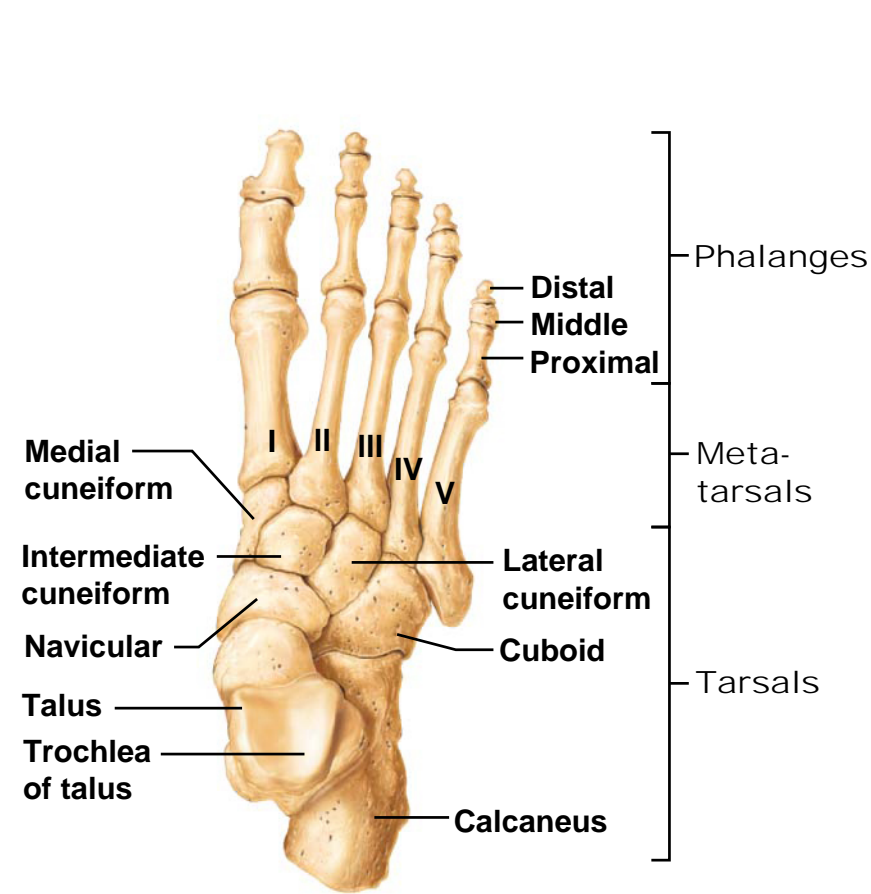
**(d)** Anterior view,  
proximal tibia

Figure 7.34e The tibia and fibula of the right leg.

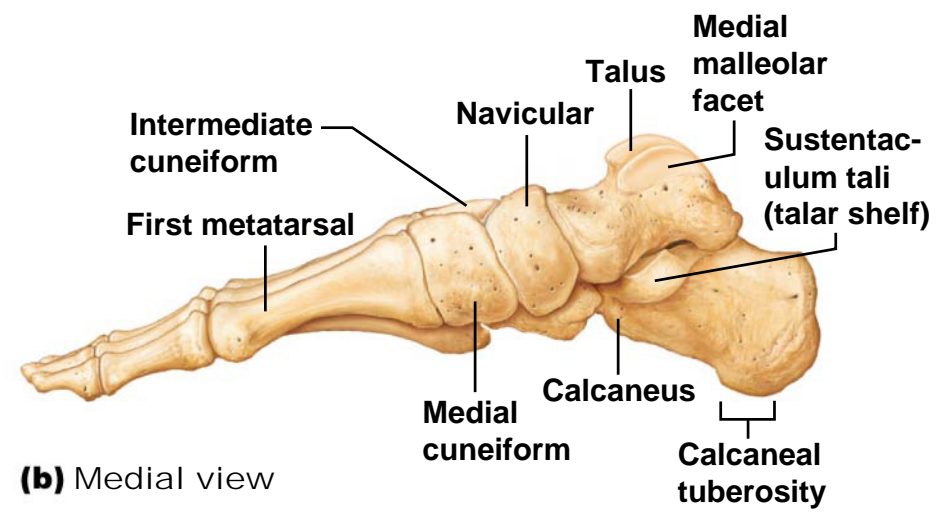


**(e)** Posterior view, proximal tibia

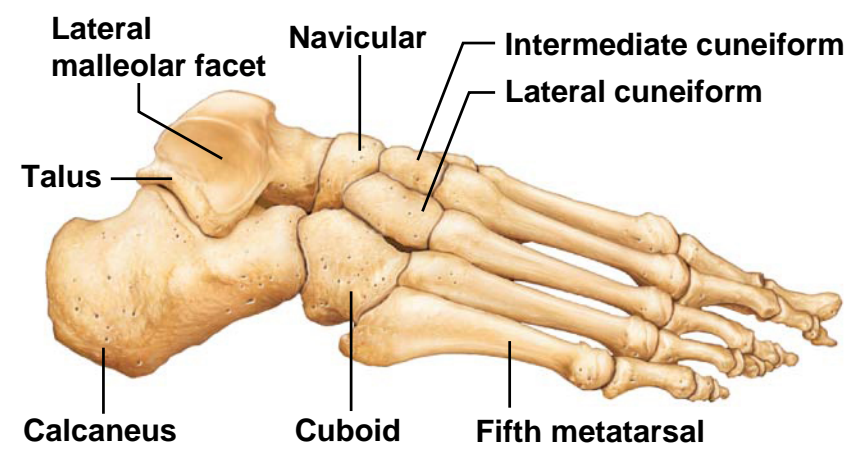
Figure 7.35 Bones of the right foot.



(a) Superior view



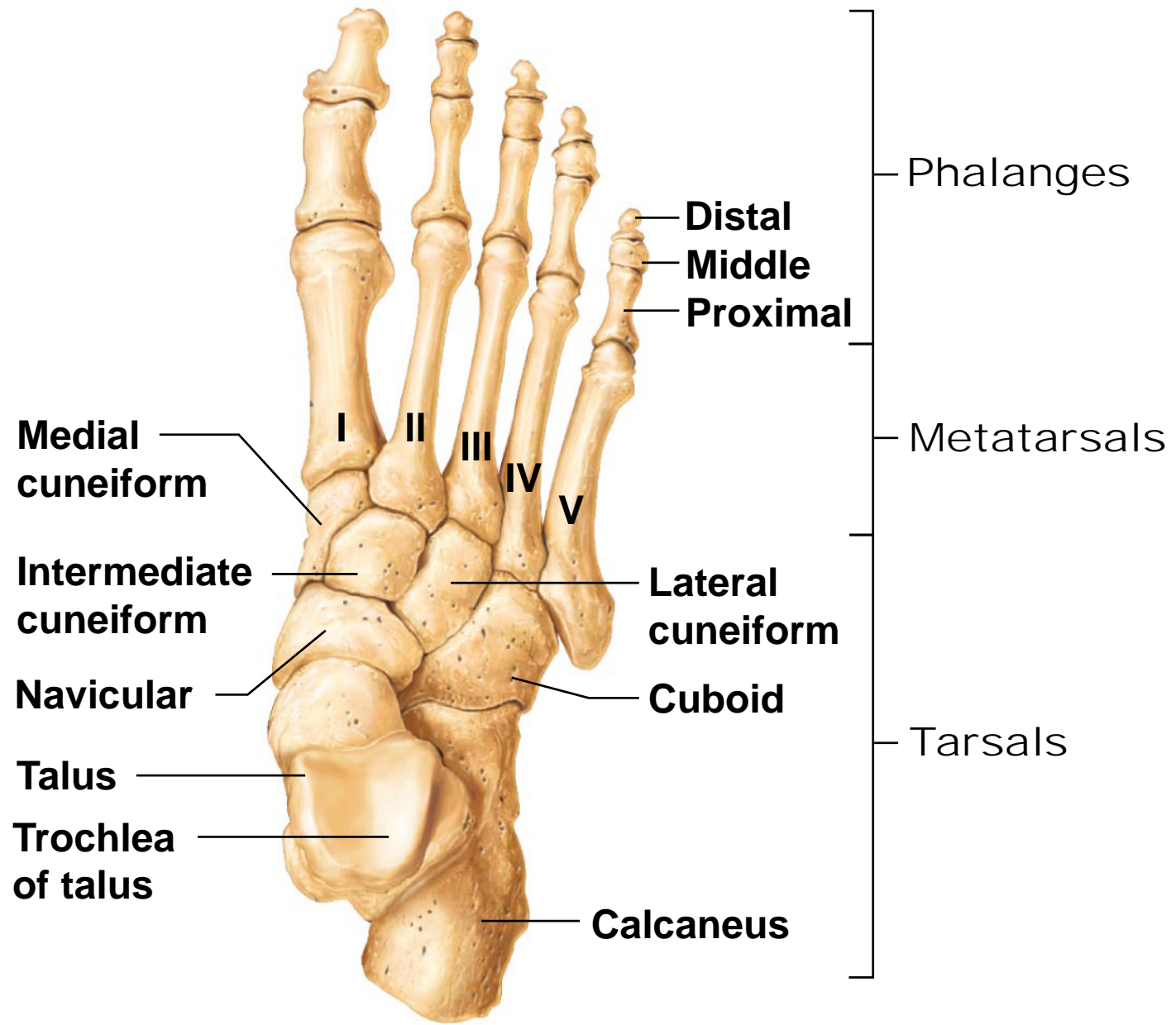
(b) Medial view



(c) Lateral view

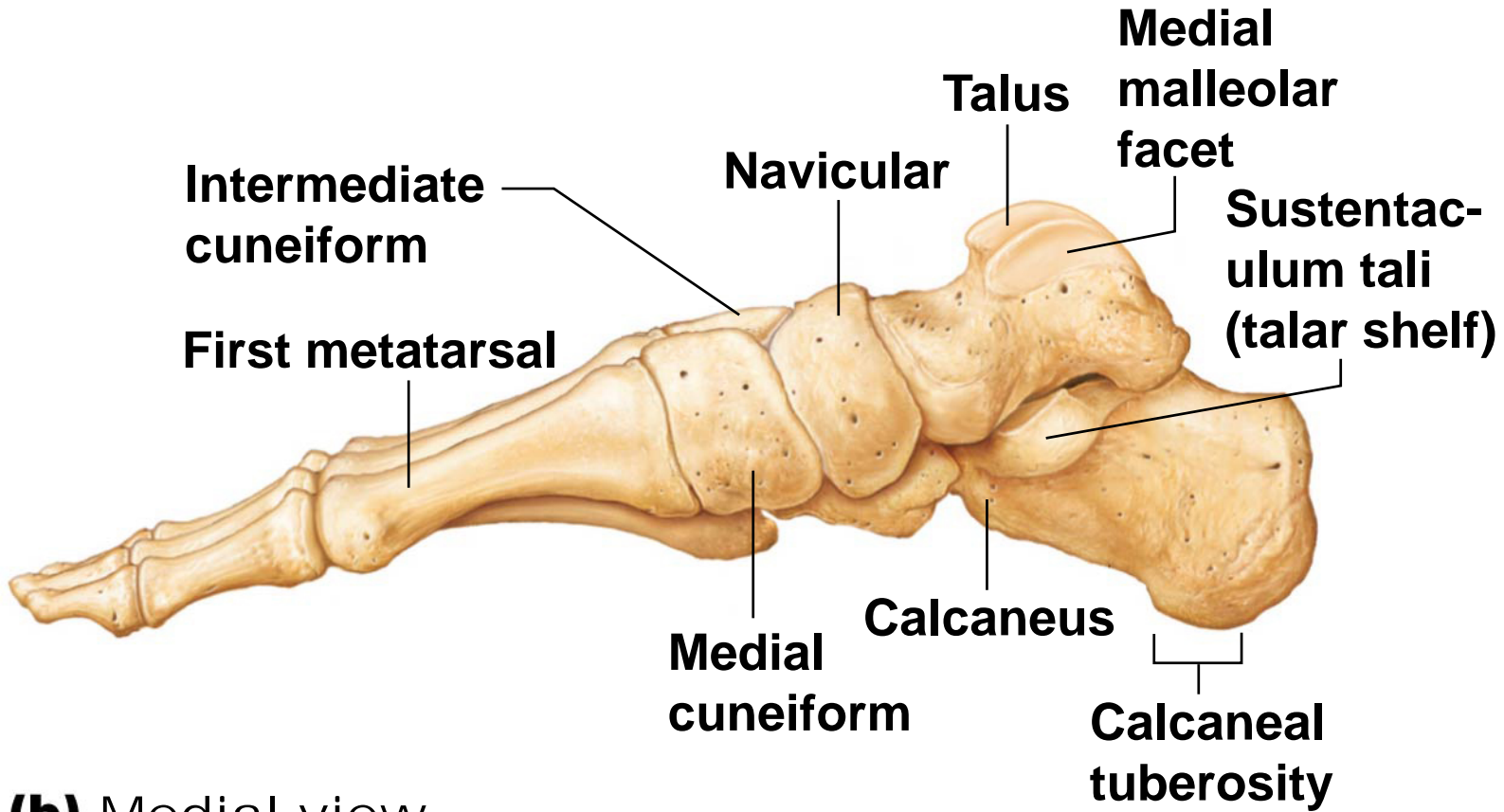


Figure 7.35a Bones of the right foot.



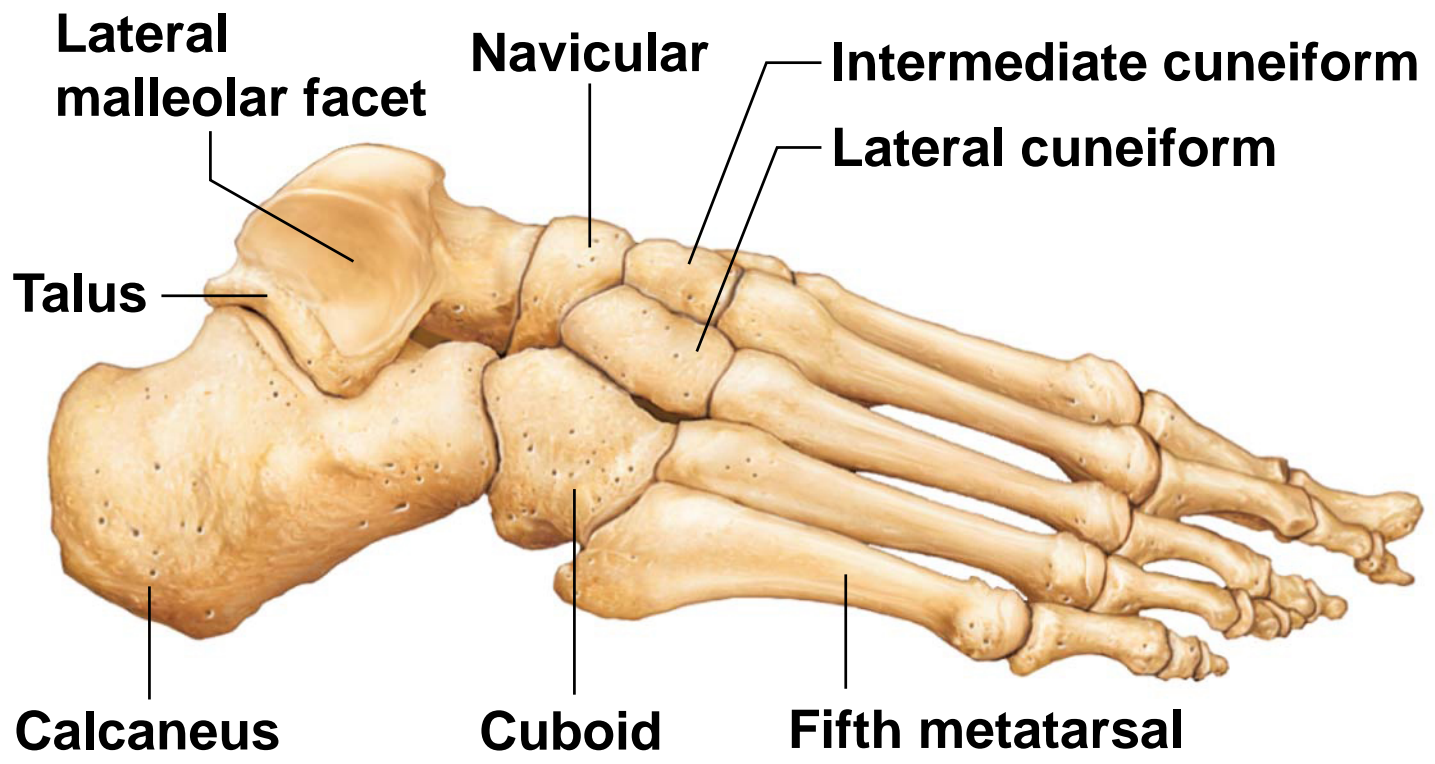
**(a)** Superior view

Figure 7.35b Bones of the right foot.



**(b)** Medial view

Figure 7.35c Bones of the right foot.



**(c)** Lateral view

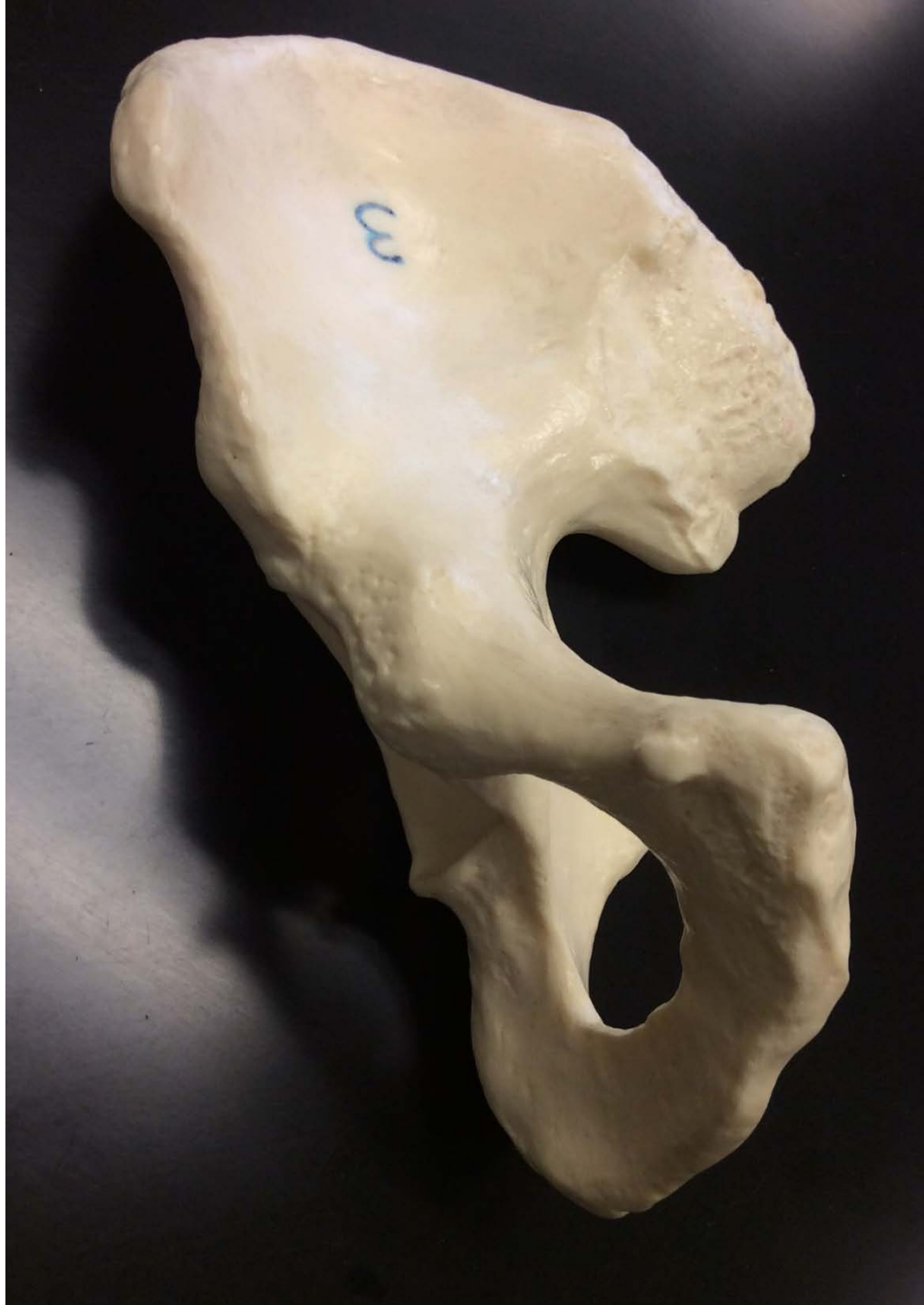


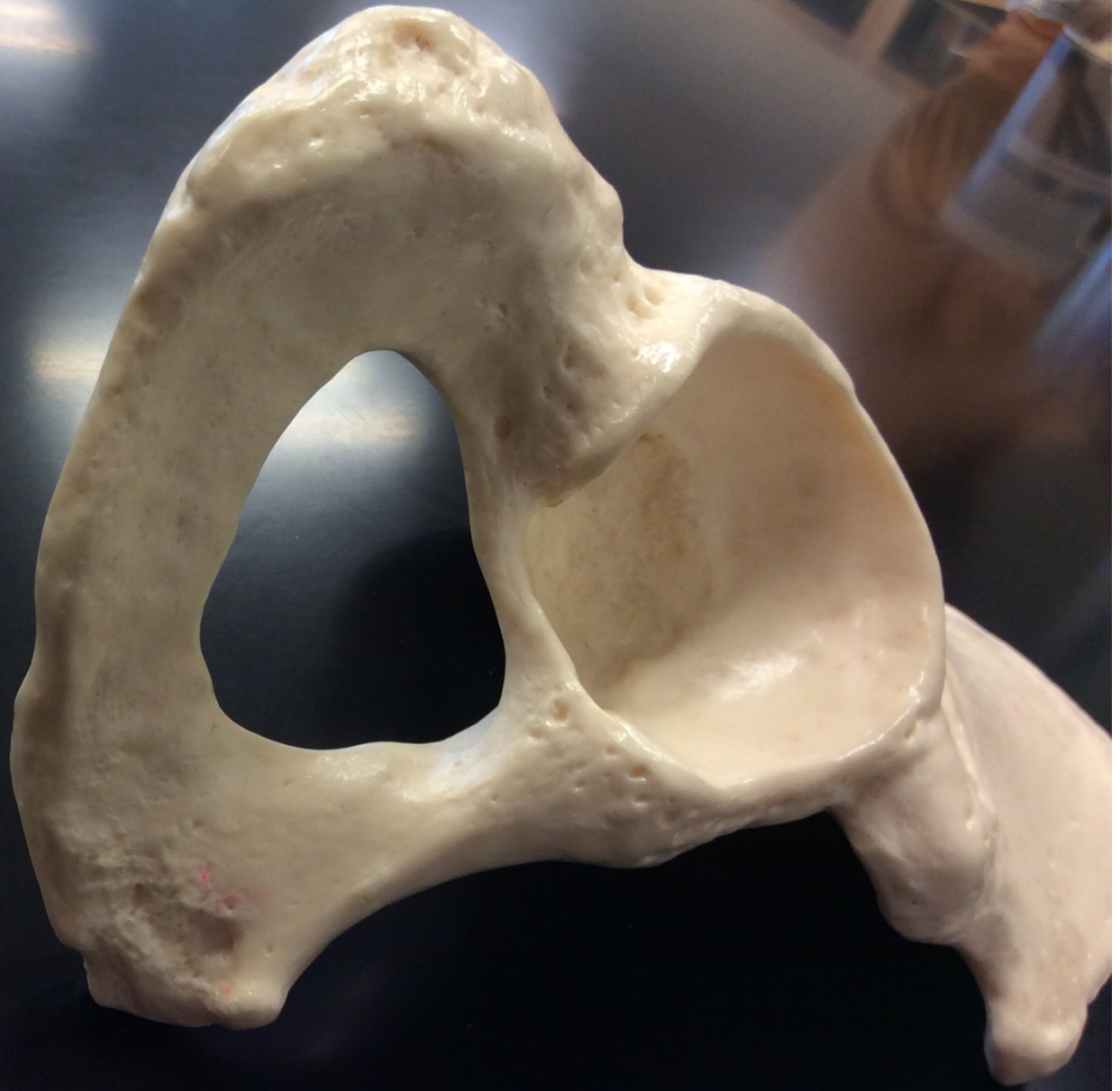Use the following pictures to help you practice finding the terms from the lab term handout on unlabeled images.

- Remember, you won't learn them if you don't take plenty of time to practice!
- Also, be sure to mix up the order once you get comfortable with the unlabeled slides.
- Over the weekend, once you are feeling confident with the pictures here, do the bone model quizzes in PAL (from the Pearson website) to get practice with new pictures that you haven't seen.

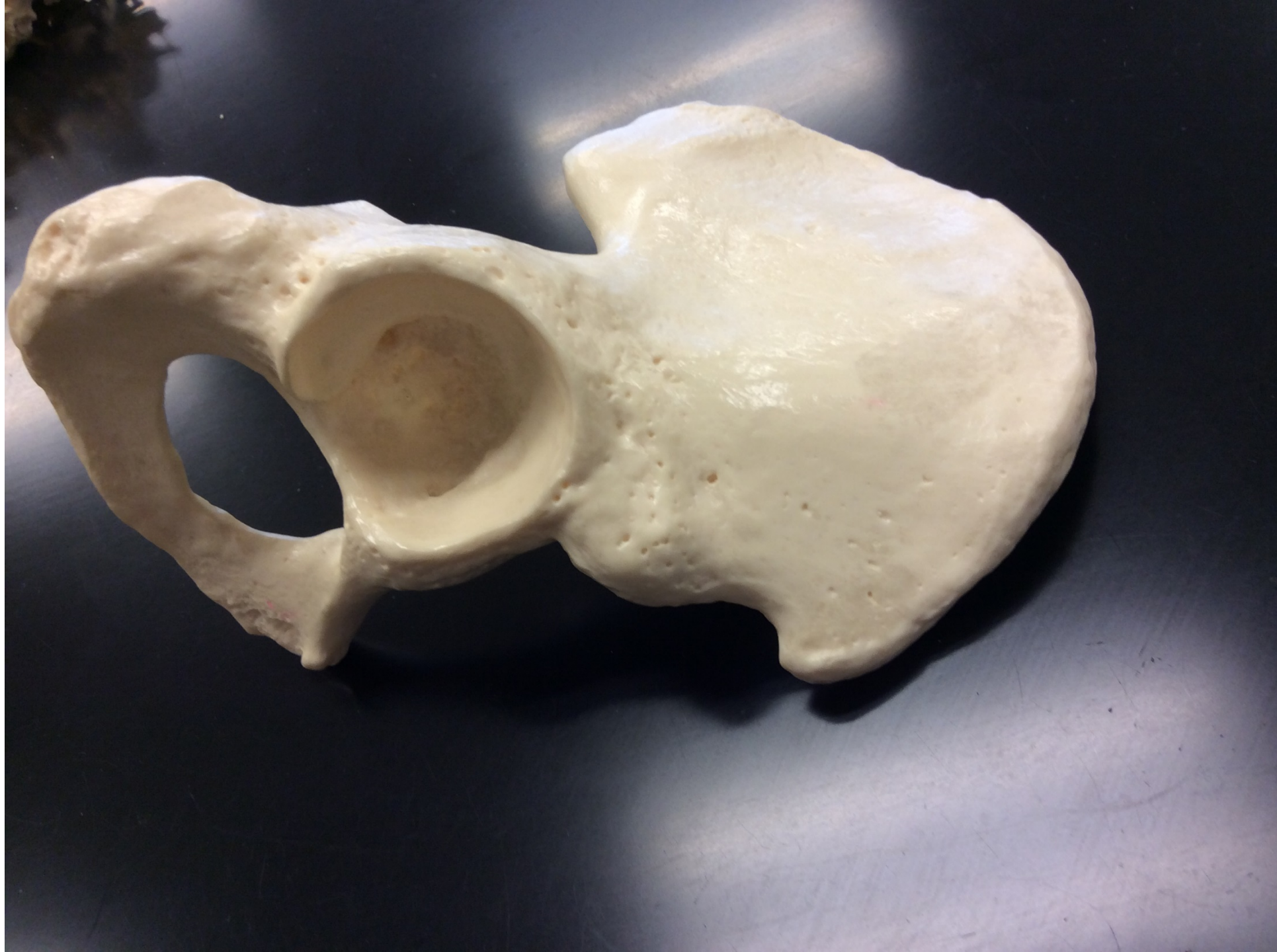
# Pelvic Girdle

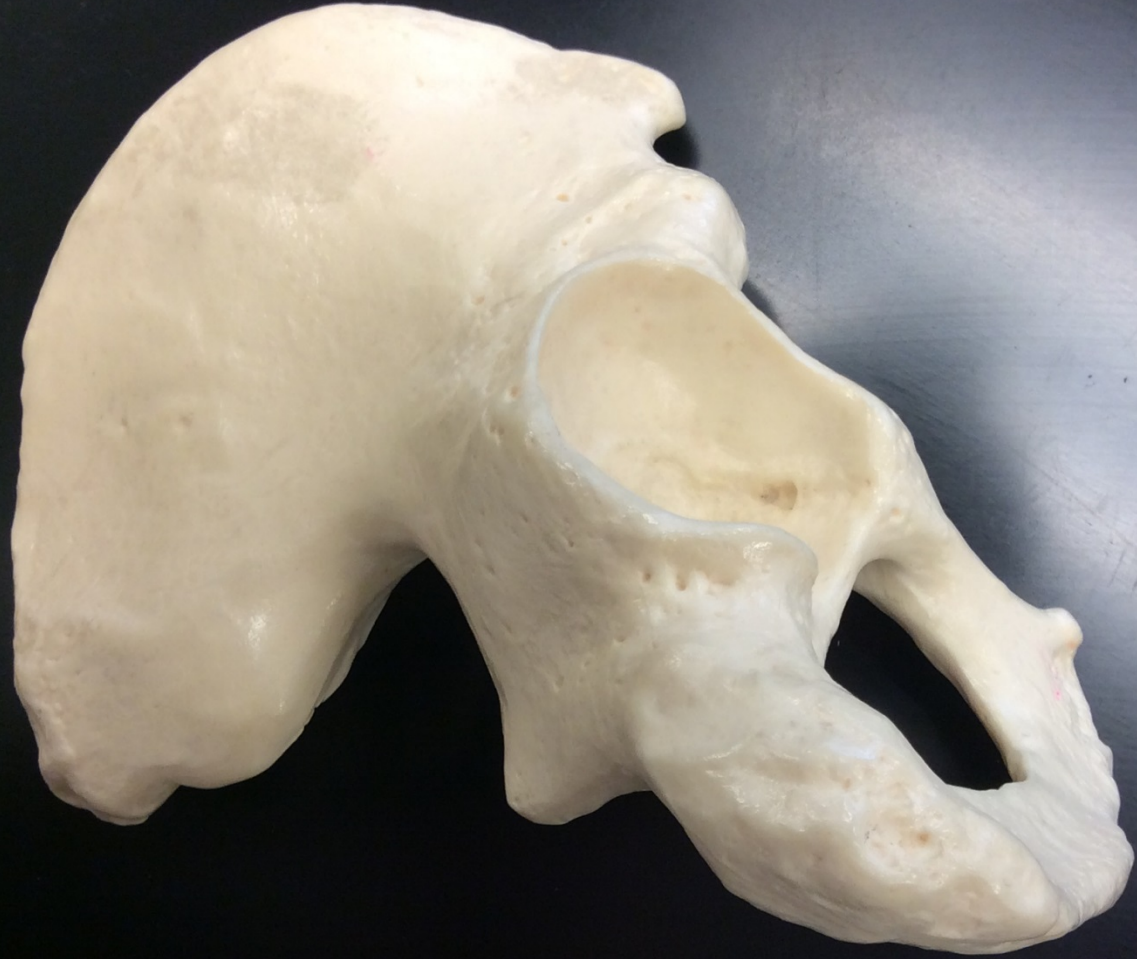Begins with right coxal bone with many different views, then moves to left with many different views.

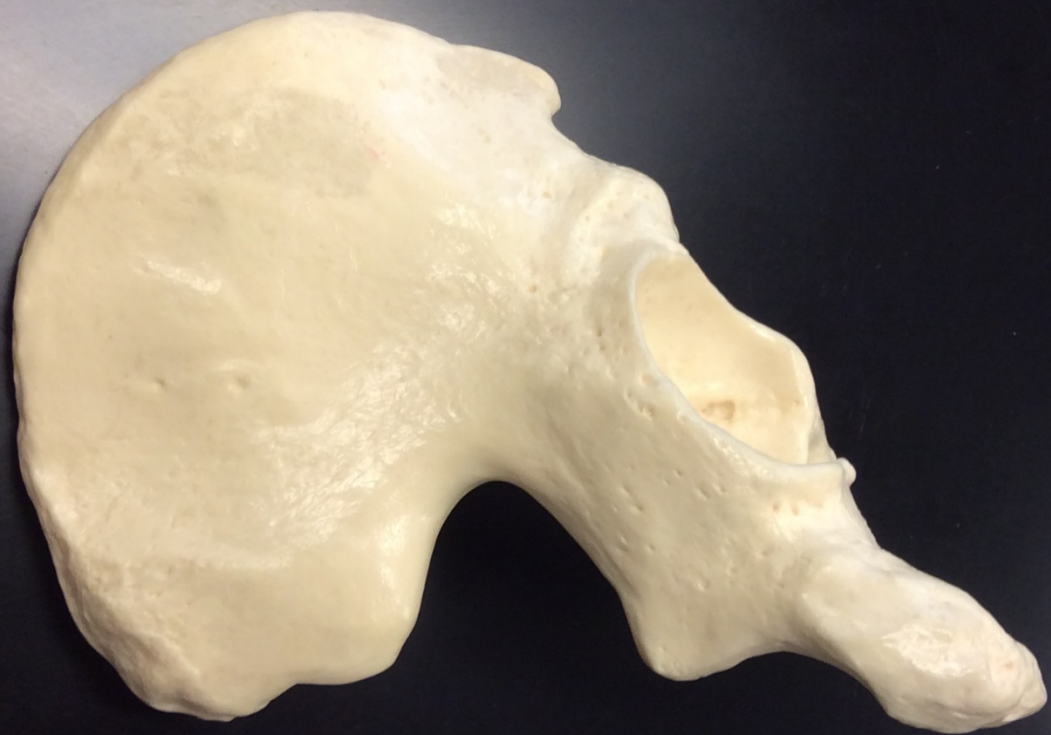


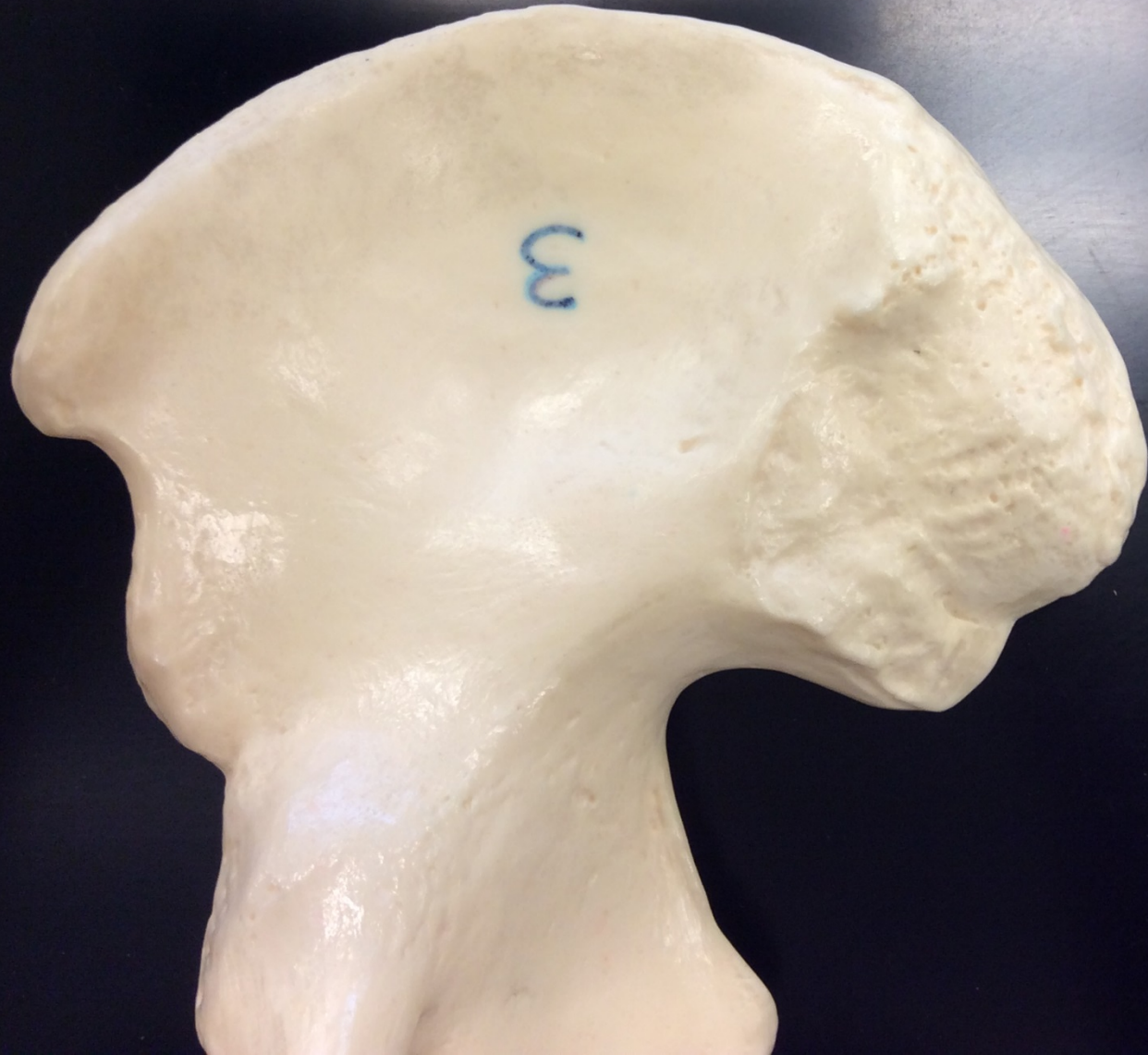


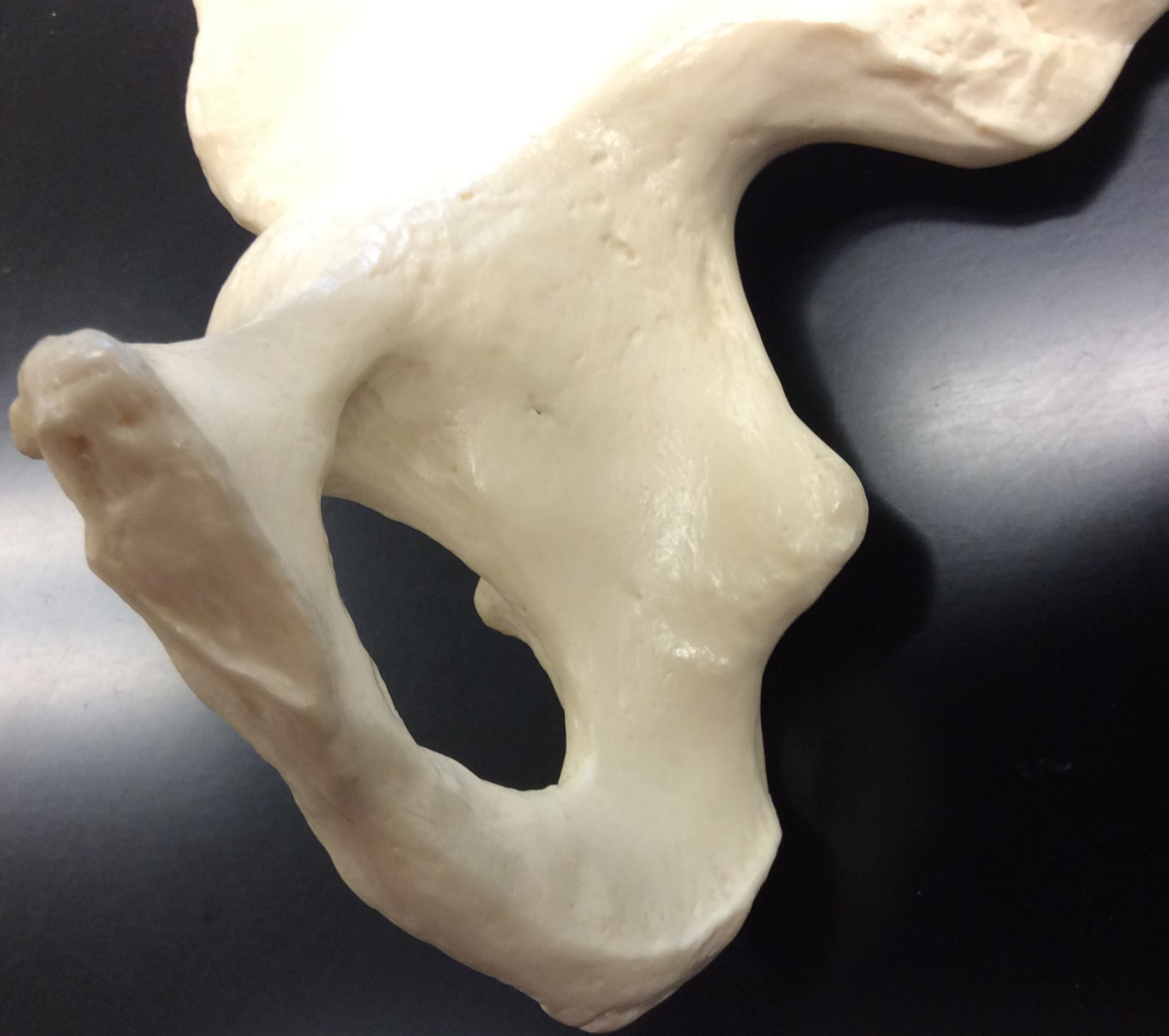

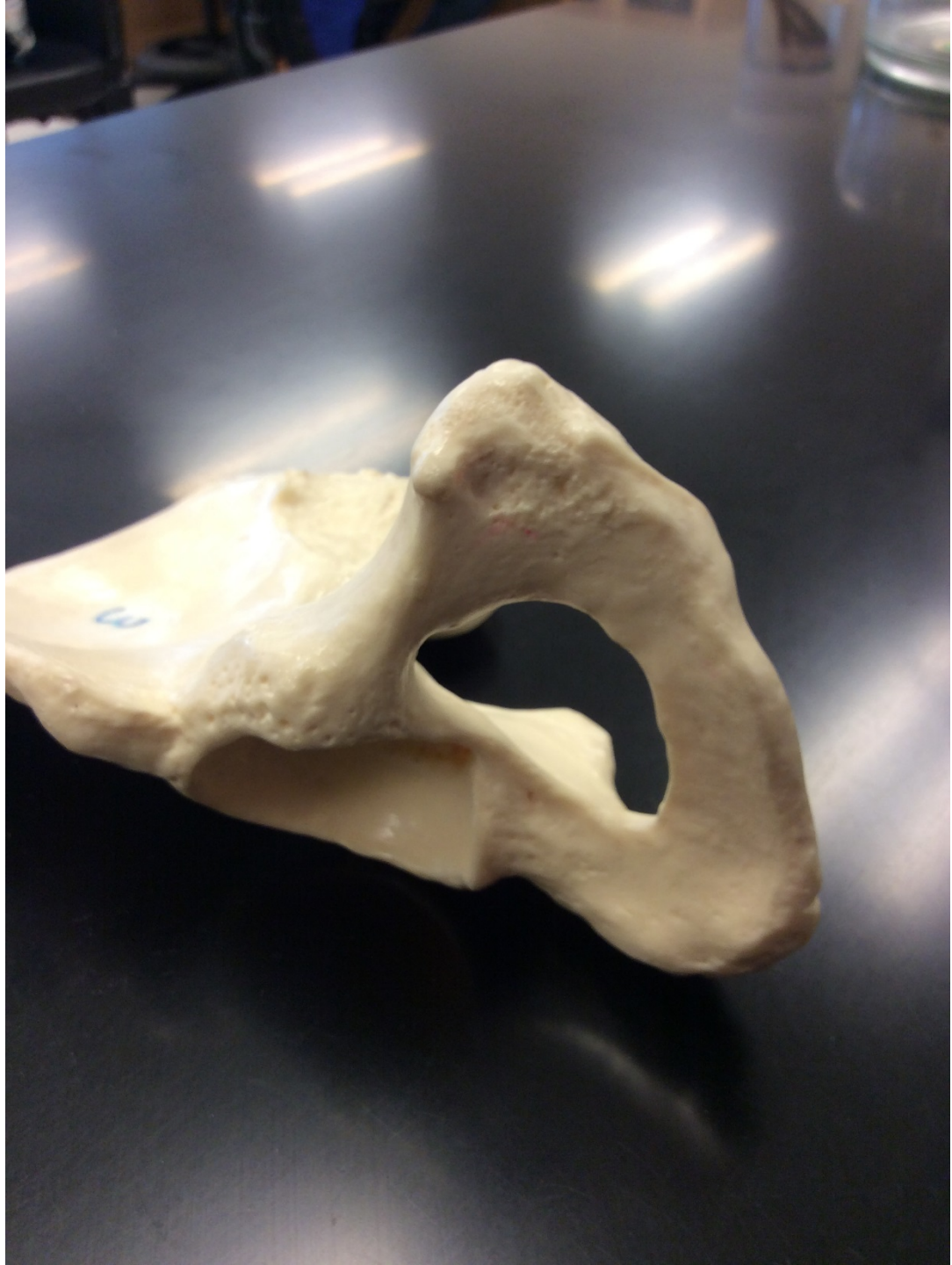





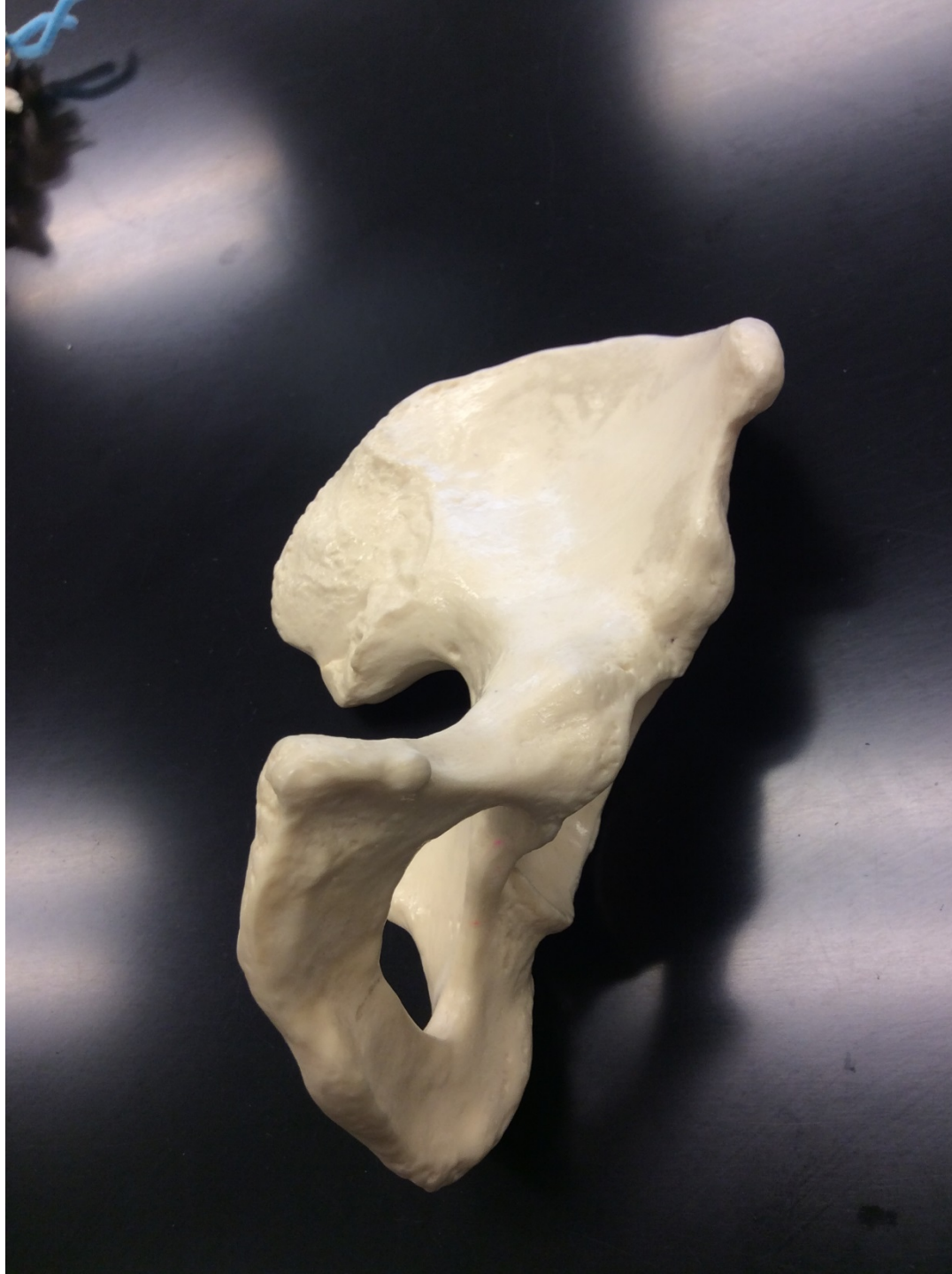
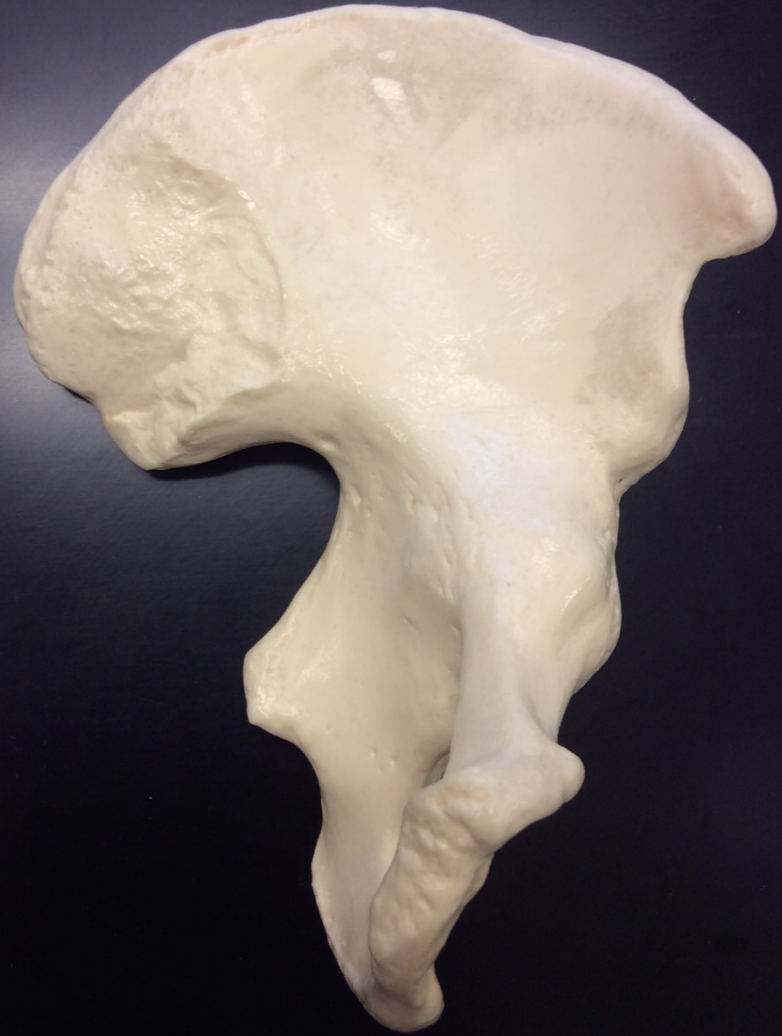




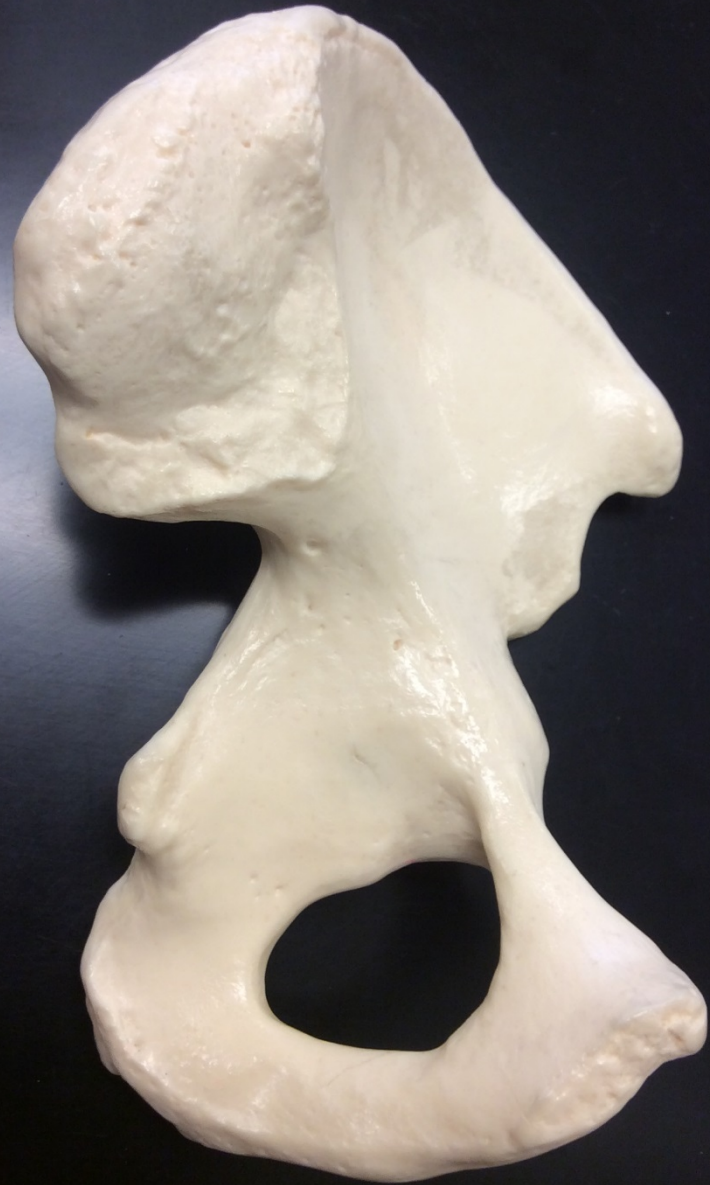


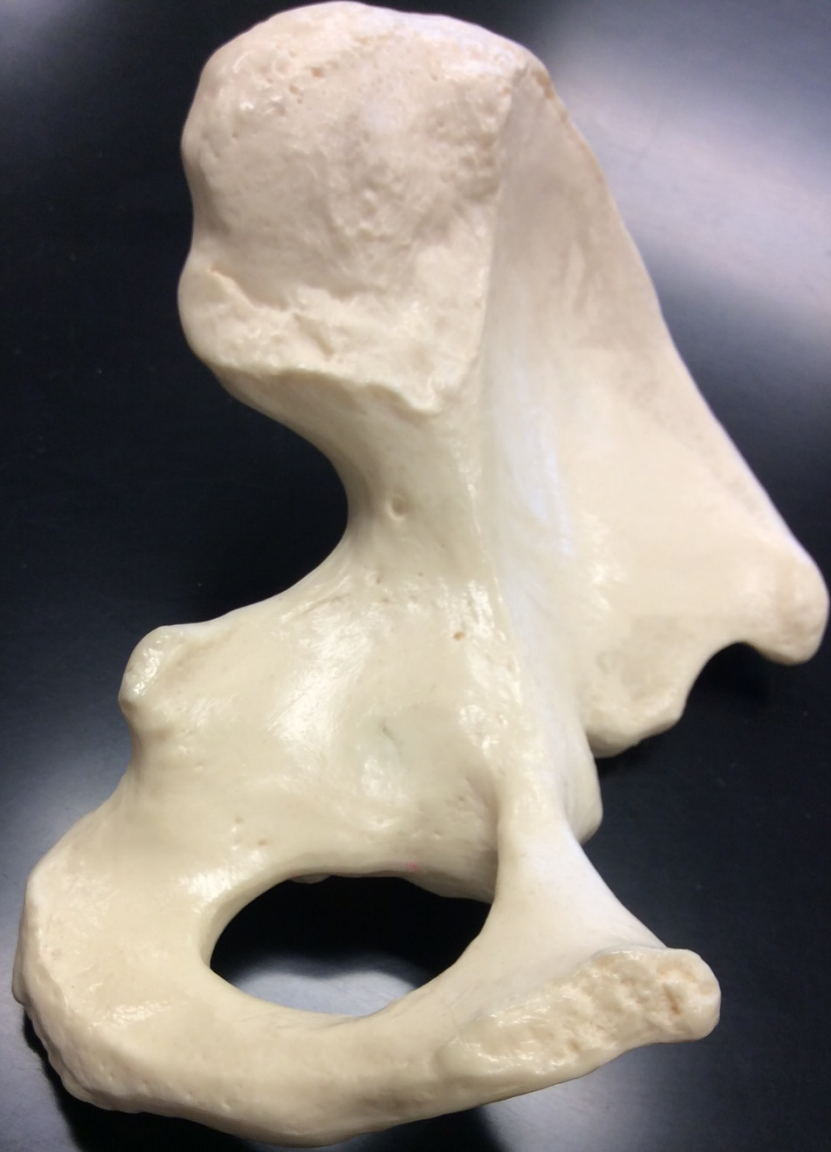
Begin left

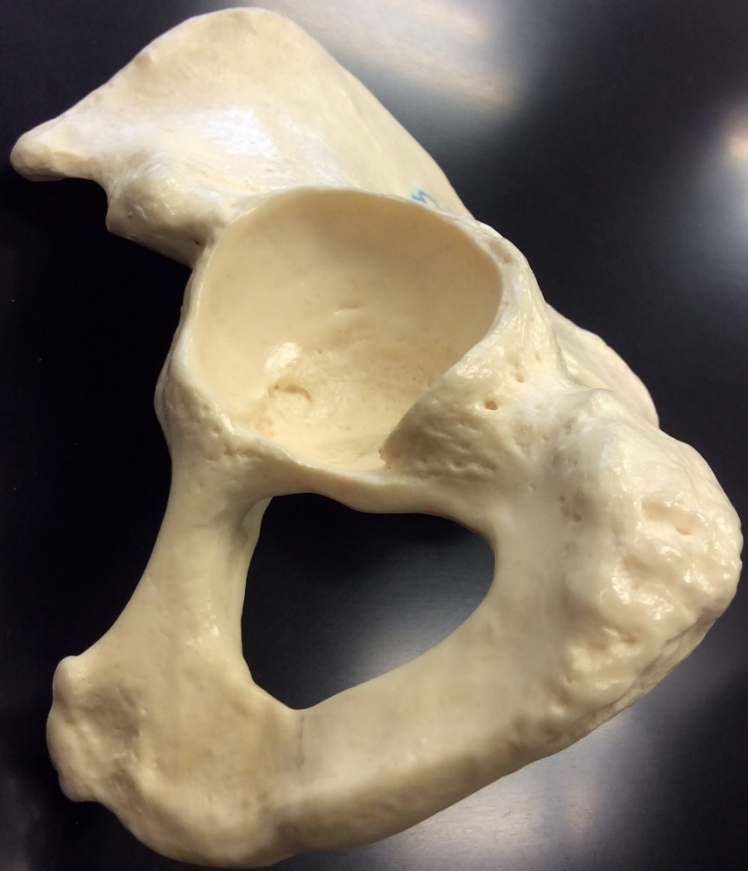


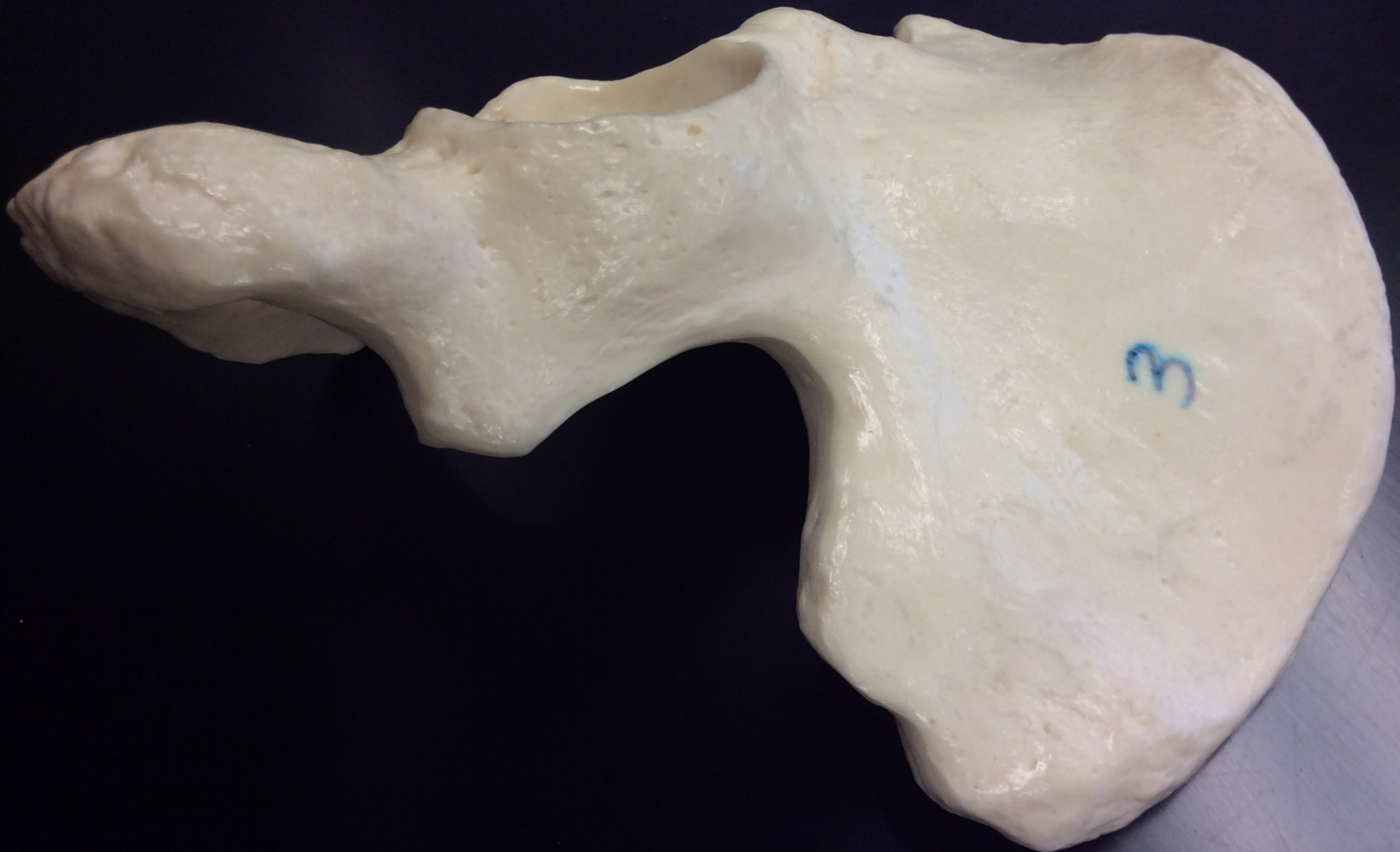


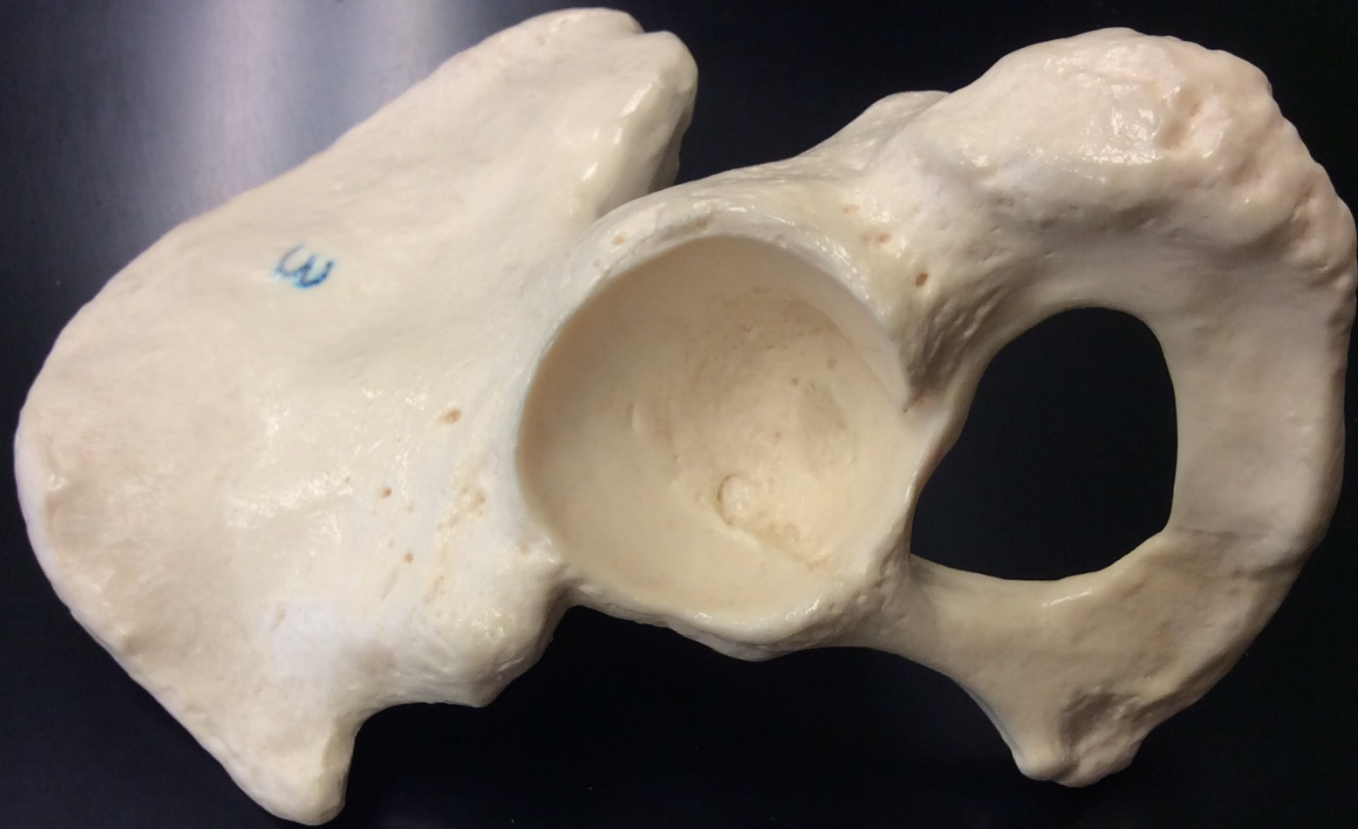


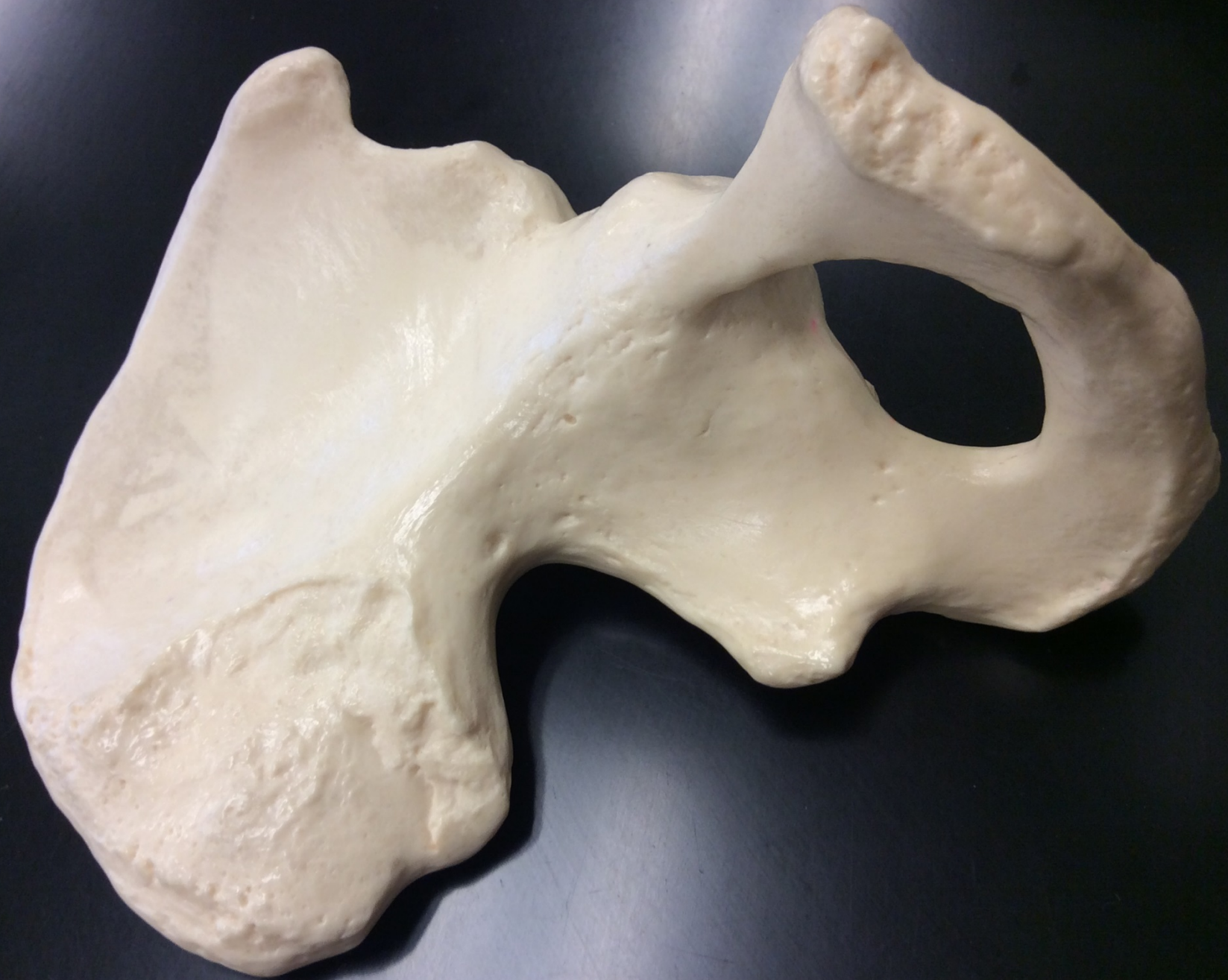











Lower Extremity (Limb)























